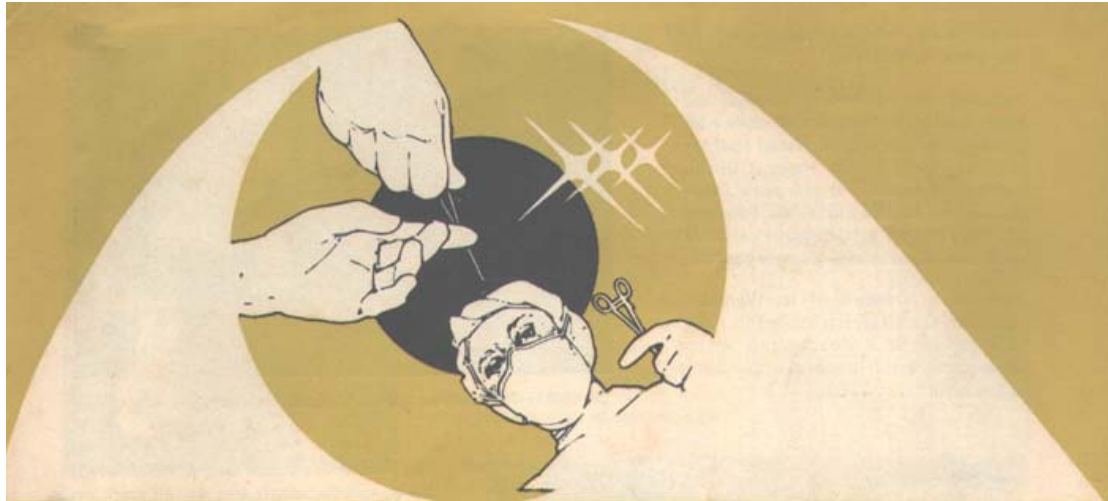



NETHRALAYA INSIGHT


VOL. I

No.2APRIL 1984

HOUSE JOURNAL OF MEDICAL RESEARCH FOUNDATION, MADRAS, INDIA



This issue of the Nethralaya Insight is being brought out under a deeply poignant shadow, Shoba, a person who was so close to all of us is no more. Not only did Shoba make a mark as one of the most active members of the Women's Voluntary Group, but also as a silent and extremely efficient worker and above all a good friend. Her service to the institution did not stop with just that but continued even after her death. Her eyes have given light to the life of two unseeing people. We are truly indebted to this person, so selfless and unassuming and dedicate this number to her memory.



**Mrs Surekha Mehta lighting the lamp at the inaugural ceremony of “Vimal Nethralaya”.
Looking on from L to R are Mrs. Doshi, Dr.Doshi, Dr.Badrinath and Mrs.Badrinath.**

1984 started with the All India Ophthalmological Conference at Cochin with five papers being presented and two scientific exhibits. This was soon followed by papers being read at the National Symposium on intra and extra-ocular tumours at Jodhpur in February 1984. Two workshops on Ultrasonography and Fluorescein Angiography were also conducted in the same symposium.

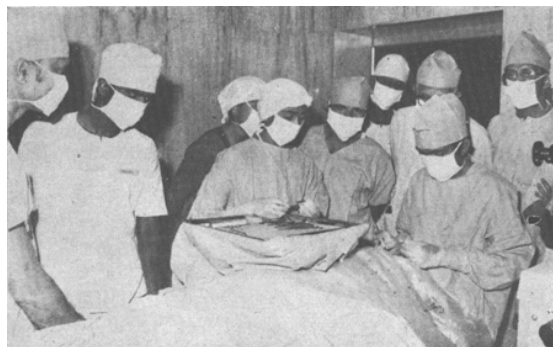
February 21, 1984 was another red letter day for Nethralaya and looks with pride at the opening of ‘Vimal nethralaya’ at Indore by Dr. Hemant Doshi, our former fellow. It was aptly inaugurated by Dr.Badrinath of February 21, 1984 and we at Nethralaya certainly wish him all success in his new venture.



Dr.Padma Subramaniam Greets ‘Sankara Nethralaya’ by way of her nritya.

Nethralaya is proud of its Women’s Voluntary Group which started in 1979 as a seeding of a thought and finally sprang into a full fledged active body in the hospital in 1980.

Initially they started off by assisting the various doctors by way of dilatation and record keeping and then with the encouragement of the Medical Director, Dr.Badrinath they moved on to welfare work in the institute itself.



Surgical Demonstration of Cataract Surgery

Free food and milk to the service patients, free eye care for the poor which not only included check ups but also a free pair of spectacles and in many cases a return ticket to their home towns was provided. This came to be from an interest on a fixed fund known as the Sankara Nethralaya Women's Voluntary Fund.



Lecture session on "Current Concepts in Cataract microsurgery".

Another sector was teaching Hindi to the staff of the Institute. This helped solve tremendously the communication problems with visitors from out of town, Eye care and essential hygiene was also taught and explained to the patients.

The Volunteers comprising of housewives are nonprofessionals and do all work on a purely honorary basis. Acting as pressure valves, the volunteers are there wherever work load is more and staff less. They may be found helping in the lobby or at the reception or one may find them lending a hand at documentation or filing. This not only allows the doctors and other staff to function normally but takes off a degree of pressure patients and doctors. Welfare schemes or the collection of funds for the increasing building costs of the Nethralaya are amongst the major aims of the volunteer group.

The new Larsen & Toubro theatre complex was officially inaugurated on March 29, 1984, by Mr.S.R, Subramaniam, Vice-President of Larsen & Toubro.



Dr.Cyrus Shroff receiving the V.T.Doshi Gold Medal from Mr.C.U.Shah.

An academic session in the morning dealt with the "Current Concepts in Microsurgery." It was heartening to see such a good response from the Ophthalmologists of the neighbouring States. Their active participation both in the teaching session and workshop was encouraging. A practical demonstration on cataract microsurgery was also held in the new theatre complex.

Besides this a cultural programme was held in the evening at the "Music Academy" which was highlighted by a special audio visual show dealing about the new Larsen & Toubro theatre complex.

Dr.Cyrus Shroff our former fellow was awarded the V.T.Doshi gold Medal for the best outgoing fellow of 1983. This was followed by a delightful dance recital by Dr.Padma

Subramaniam with one of the numbers specially composed and choreographed by Miss Subramaniam for 'Sankara Nethralaya'.

Six new self contained consultation rooms have been added this year to meet the growing numbers of outpatients. A brand new reception area is also in the process of completion. All these facilities are intended to streamline the outpatient crowd and to provide its wide clientele excellent quality care.

With every good wishes to all our readers.

Mary Abraham

Editor

Venous Stasis Retinopathy with Branch Arteriolar Occlusion.

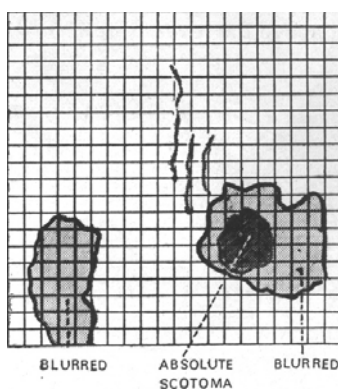
-A case report

Dr.CYRUS M SHROFF

INTRODUCTION :

Full blown occlusion of the central retinal vein or artery usually presents a characteristic clinical picture. Probably 95% of occlusive vascular disease of the retina is the so called retinal vein occlusion. Very often both arterial and venous occlusion are incomplete and can co-exist and produce a wide spectrum of clinical features. In an isolated circulation such as in the retina, there is a close interplay between the arteriolar and venular circulations. A reduction in arteriolar flow will reduce venous flow and predispose to venous stasis and conversely reduced venous flow may cause reduced arteriolar blood flow. These cases highlight the interplay of the arteriolar and venous components of the retinal circulation.

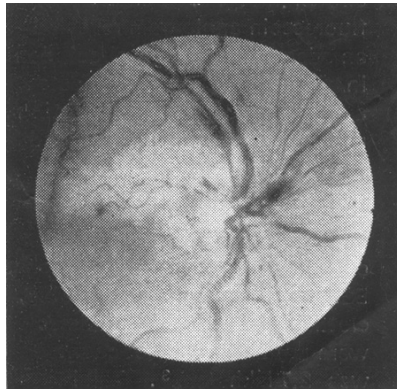
CASE I:



(Fig. 1) Amsler grid showing Scotomas.

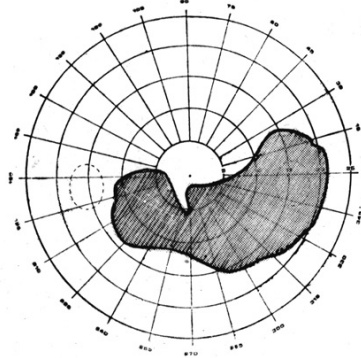
S.M., a 40 year old female presented as an emergency with complaints of sudden onset of a black spot in the center of her right visual field of one day's duration. She had suffered from a tooth infection 3 weeks earlier but had not had an extraction. She was not diabetic or hypertensive and was not taking oral contraceptives.

Ocular examination revealed a visual acuity of 6/9,N/5 and 6/6,N/5 in the right and left eyes respectively, Slit lamp examination was normal and applanation tension was 21 mm of Hg in both the eyes. Amsler grid examination of the right eye showed a dense scotoma infero-temporal to fixation and a less dense scotoma in the nasal and infero-nasal quadrants. (fig 1). Fundus examination with binocular indirect ophthalmoscope revealed a hyperemic disc with flame shaped haemorrhage supero-nasal to it, dilated tortuous veins and a sharply outlined from the disc to just above the fovea. (fig 2) (P.3)



(Fig.2) Fundus photograph showing site of obstruction and area of retinal pallor.

On the basis of these findings a clinical diagnosis of branch anteriorlar occlusion with impending central retinal vein occlusion was made.

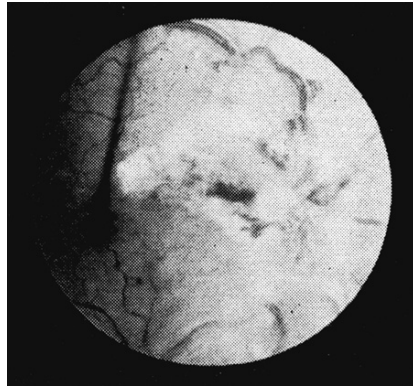


(Fig. 3) Visual field showing scotoma just skirting fixation.

Visual fields plotted on the autoplot tangent screen are shown in Fig.3. Fundus fluorescein angiogram revealed an adequate capillary circulation in the regions of the suspected arteriolar occlusion suggesting recanalisation of the occluded arteiole.

Haemogram showed total leucocyte count of 13,400 cells/mm³ with 77% polymorphs, ESR was 26 mm/hour. Bleeding, clotting and prothrombin times were normal. Platelet count was 2.7 lakhs/mm³. Total proteins were 6.5 gm O/c, Albumin 3.76 gm%, Globulin 2.74% and A:G ratio 1.37 : 1.00. Serum cholestrol was 160mg%.

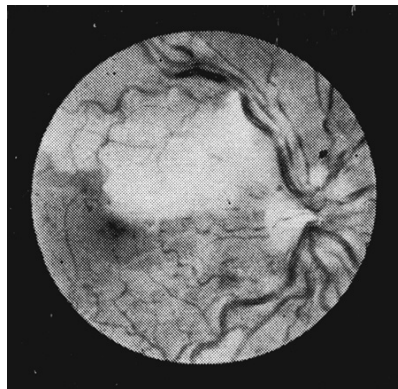
The patient was treated with Lomodex 1/V infusion 2 litre/day for 3 days. Systemic Prednisolone (30 mg/day) and Ampicillin were also given. 4 days later the visual acuity was 6/18 and venous engorgement and tortuosity were much less. There was marked retinal oedema and a few haemorrhages in the infracted area. She was discharged on Complamina retard, steroids. 2 days later she experienced a flare up of here dental problem and underwent tooth extraction under cover of antibiotics and steroids. 10 days later her vision had improved again to 6/9 and N/5. Theoptic disc appeared swollen with deposition of hard exudates like material around it, extending in an arc like fashion towards the fovea, but just sparing it (fig 4. Scattered haemorrhages were seen in the periphery. Amsler charting showed a reduction in size of the absolute and relative scotoma and distortion of vertical line superior and temporal to fixation. Repeat field testing however showed the absolute scotoma to be almost unchanged.



(Fig. 4) Fundus photograph showing deposition of hard exudates above fovea and disc oedema.

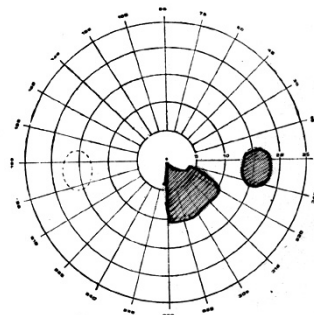
CASE II :

K.V., a 19 year old girl was seen as a emergency with a history of sudden loss of the inferior half of here right visual field of 3 days duration. There was no significant past or family history.



(Fig. 5) Fundus photograph showing sharply defined zone of retinal pallor superior to fovea and including it.

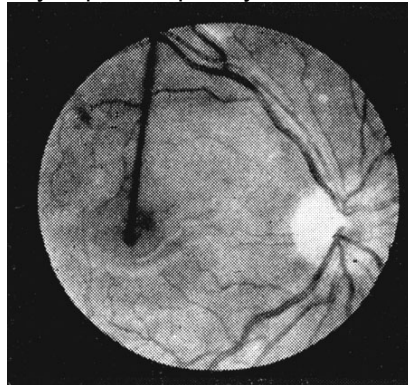
On examination, here visual acuity was 6/36 in the right eye and 6/4 in the left with near vision of N/12 and N/5 in the right and left eye respectively. Anterior segments and intraocular pressure were normal. Funds examination showed a definite irregular sharply desifined zone of retinal pallor, superior to the fovea and including it (fig.5). There was definite oedema of the optic nerve head and the veins were dilated and tortuous.



(Fig. 6) Field Charting showing scotoma intero-temporal to fixation.

The entire retina was splattered with numerous superficial retinal haemorrhages. She was diagnosed to have upper temporal branch arteriolar occlusion with impending Central retinal vein occlusion. Field charting with Goldman perimeter and auto plot showed an infero-temporal scotoma just below the fixation spot. (fig. 6). Flourescein angiogram showed a patch

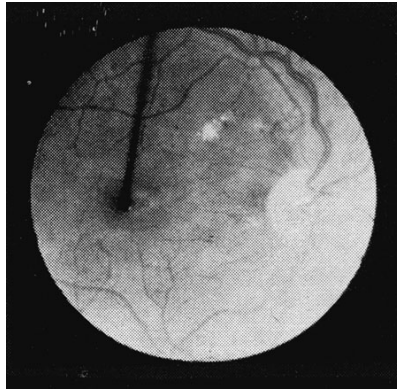
of hypofluorescence in the upper temporal quadrant between and above the disc and fovea, with non filling of the arteriole in that region. Venous filling was distinctly and definitely delayed. The perfoveal net was conspicuously lacking just above the fovea. The angiogram confirmed the diagnosis of upper temporal branch arteriolar occlusion with impending central retinal vein occlusion. Haemogram, prothrombin time, clotting time and bleeding time were within normal limits. Total proteins and A: G ratios were normal. Chest X-Ray was normal and VDRL and LE cell test were negative. There was evidence of urinary tract infection which was treated with Garanycin injections. Besides this Disprin and Persantin. A week later systemic steroids were started. 10 days later the disc oedema appeared aggravated and she was started on low molecular weight Dextran infusions. A week later the disc and retinal oedema were found to be much less. Vision at that stage was 6/24. Central field continued to show an infero temporal arcuate-like scotoma just sparing fixation. She was discharged on disprin, Persantin and tapering dose of Steriods. A month later her visual acuity continued to be 6/24. Funds showed a sclerosed artery super-temporally at the disc with recanalisation distally.



(Fig. 7) Fundus photograph showing sclerosed superotemporal artery at disc with recanalisation distally.

The disc itself was pale temporally. Repeat FFA at this stage revealed normal filling of the previously occluded arteriole, normal venous filling and normal caliber of the veins with no tortuosity. The capillary perfusion just above the fovea had considerably improved. 11 months later her vision had improved to 6/5. Fundus examination revealed temporal pallor of the disc with a small patch of hard exudates superior to it. FFA was within normal limits Central fields still showed a scotoma of considerable size infero-nasal and infero temporal to fixation. More than 3 years later she was found to be maintaining 6/5 vision, though the scotoma persisted. Fundus was within normal limits. In the intervening period she had suffered from "Wrist drop" which had since improved considerably. Neurological check up could not reveal any cause.

DISCUSSION : Retinal arterial occlusion may be confined to a branch may be confined to a branch vessel, the supero-temporal being involved most frequently as seen in both these cases. However any branch including a fine macular one may be affected. Fundus pallor in these cases are confined to an area served by the vessel. The sector field defect in branch retinal artery occlusion is usually bounded by straight or well defined margins, even though the area of retinal oedema presents an irregular border, When a cilio-retinal artery is occluded a centrocaecal scotoma results. A paracentral scotoma taking the form of an altitudinal central hemianopia may result from the blockage of a branch of the inferior or superior temporal artery supplying the macula. Visual defect in this condition may be partial, may diminish or even pass off completely. The shorter the duration of the conditon the more likely is the recovery to be complete.³



(Fig. 8 Fundus Photograph showing temporal pallor of disc with a small plaque of hard exudates close to fovea.

The question that now arises is what was the cause of impending central retinal vein occlusion in our cases and how are the two correlated? In an isolated circulation such as the retina, there is a close interplay between the arteriolar and venular zones of the circulation. A reduced arteriolar flow will reduce venular flow for eg. Vasculitis (or venous pathology at an abnormal a – v crossing) may cause reduced arteriolar blood flow or accentuate it if already present.

Arteriolar irregularities often follow retinal vein occlusion⁴. The major factors implicated in the pathogenesis of vein occlusion are thrombus formation, hyperviscosity of the blood and vasculitis, with glaucoma and systemic hypotension being important accessory factors. Though thrombosis is the most frequent cause, vasculitis is also not uncommon. The wall of the vein is infiltrated by leucocytes and occlusion may occur by extension into the lumen or by causing clot formation³. This group is usually found in younger of age⁶ in whom a source of infection is often found. Cases have been reported associated with nasal sinusitis⁷. Since in both our cases, there was definite source of infection, in a young person, with a picture of venous stasis retinopathy and branch arteriolar occlusion, the most likely cause appears to have been a vasculitis. Both have been very fortunate that the area of retinal infarct just skirted the fovea without actually involving it and good visual acuity was thereby maintained. In all cases of vascular occlusion a thorough search for systemic predisposing factors must be made.

Embolism and thrombosis are important causes of retinal arterial occlusion. Source of an embolism may be from diseased heart valves, mural thrombosis and from carotid atheromas. Unilateral venous stasis retinopathy can occur in cases with occlusive disease of the carotid artery⁸. Ophthalmodynamometry is a useful investigation in these cases.

SUMMARY:

Two cases with features of both retinal venous and arteriolar occlusion is presented and its likely pathogenesis traced. The close interrelationship between venous and arterial pathology in the retina is emphasized and so is the importance of thorough ocular and systemic examination and investigation.

Reference:

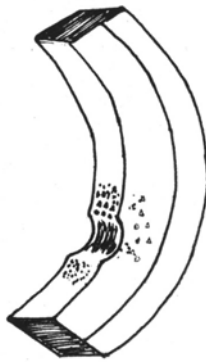1. Michaelson Isaac C., Text book of the Fundus of the Eye 3rd Edition, Churchill Livingstone, P.216 (1980)
2. Gass J.D.M., Arch Ophthal, 80 550, (1968)
3. Michaelson Isaac C., Text book of the Fundus of the Eye, 3rd Edition, Churchill Livingstone P.203-205 (1980)
4. Wise G.N. Trans Amer, Ophthal Soc., 54, 729-827 (1956)
5. Ballantyne A.J., & Michaelson I.C. Trans Ophthal Soc., U.K., 67, 59, (1947)
6. Vamanonchi U. Etal., Michaelson I.C. Text book of the Fundus of the Eye, P.235 (1980)
7. Fontan, P. Etal., in Michealson I.C. Text book of the Fundus of the Eye, P.222 (1980)
8. Kearns, T.P., & Hollenhorst R.W. Proc Mayo Clin 38, 304 (1980)

Circumscribed Posterior Keratoconus

Dr.MANJU KULKARNI

Posterior Keratoconus is a rare congenital aberration of the cornea, characterized by normal anterior curvature and loss of substance in the posterior corneal layers. When this loss of substance is diffused, the condition is termed as generalized posterior keratoconus and when localized, it is called circumscriptus. The latter is more common of the two.

The entity is sporadic, although familial occurrences have been reported. The etiology is unknown. It is probably a result of delayed separation of the lens vesicle from the surface ectoderm. This in turn may lead to excessive absorption or cleavage of the mesoderm in the area of involvement.



Cut section of cornea showing crater like defect in the posterior corneal layers.

Keratoconus posticus circumscriptus appear as a crater like defect in the posterior corneal surface with the convexity towards the stroma. Descemet's membrane and endothelium are usually present in the area of the defect, although the structure of the Descemet's membrane may not be normal. Stromal haze and pigmentation is usually present in the anomalous area. Visual acuity may or may not be affected. As a rule vision is unaffected because the anterior corneal surface, which is the major refracting surface is normal. The condition is non progressive and is not a contraindication to intraocular surgery.

The first case of posterior keratoconus was described by Butler in 1930. The purpose of this article is to highlight our findings in this case, which is the first to be described in our total of 40,000 outpatients.



Stomal opacity and pigmentation overlying the posterior keratoconus.

The patient was a twelve year old boy whose only complaint was inability to lift the eyelids up since birth. There was no history of consanguinity of parents and other siblings were normal.

His best corrected visual acuity was 6/24,N/6 in the right eye and 6/18,N/6 in the left eye. He had bilateral congenital ptosis, gross epicanthic folds, hypertelorism and broad nasal bridge.

The corneae showed bilateral circumscribed posterior keratoconus more marked in the right eye. Other features like pigmentation and stromal haze were also present. The conjunctive encroached the cornea superiorly and inferiorly giving a false appearance of microcornea.

The patient subsequently underwent surgical correction for epicanthic folds and ptosis. In the cases reported so far by other authors, features associated with this condition viz hypertelorism, bullneck, growth retardation etc., have been mentioned. The interesting clinical feature in our case is the presence of bilateral prosis which has so far not been reported.

Reference:

1. Haney W.P.,and Falls H.F. The occurrence of congenital keratoconus posticus circumscriptus, Am J.Ophthalmol 52;52;1961
2. Schocket G.S., Phelps W.L.Pettit T.H.Bilateral posterior circumscribed keratoconus, Am J Ophthalmol 57;840;1964
3. Wolter J.R.,Haney W.P.Histopathology of keratoconus posticus circumscriptus, Arch Ophthalmol 69;357;1963.
4. Grayson M.Diseases of Cornea 314 – 31, 2nd Edition;C.V.Mosby & Co; 1983.

Post-Surgical Results in Intermittent Exo-Deviations

Dr.T.S.Surendran

Treatment and prognosis for intermittent divergent squints are controversial. Some advocate recession of both lateral rectil while the majority recommended bilateral lateral rectus recession only for the cases with divergence excess. In our small series of 41 cases, with intermittent exo-deviation, bilateral lateral rectus recession was done in 16 patients. Of these, seven had divergence excess type of deviation and the rest were all basic type of exo-deviations.

All these patients were subjected to cycloplegic refraction, complete orthoptic evaluation with prism bars, synoptophore and tests for stereo-acuity with titmus fly etc., before and after squint correction. Those who had divergence excess underwent patch test to rule out simulated divergence excess patterns (i.e. the static deviation at near fixation being obscured by dynamic factors like excessive convergence innervation), The patch test or occlusion test was done by closing one eye for 1-2 hours and doing prism bar cover test (PBCT) immediately after removing the patch. The amount of deviation was then classified accordingly. The PBCT was done in primary, up and down gazes for distance and near and was done with and without glasses. Fusional amplitude tests for BSV ,NPC and NPA were all assessed before and after surgery. Orthoptic evaluation was followed by detailed fundus examination with indirect ophthalmoscope before and after surgery.

All surgical procedures were done under general anaesthesia and bilateral lateral rectus recessions of 6-8 mm depending on the amount of deviations were done. Seven patients had associated A-V syndromes for whom differential recession and resections were performed. Two patients had inferior oblique overactions for which inferior oblique myotomies were combined with lateral rectus recession. One patient underwent transposition of both lateral rectil after recession for the gross 'V' phenomenon that was present.

Result :

The success rate in this group was very gratifying. Twelve patients had orthophoria, two had residual exo-deviation and consecutive exo-deviation was found in two patients. This is in comparison to the recession/resection technique done in a series of twenty-five cases where seven patients had residual exo and three patients had consecutive exo-deviation. The present technique has a 75% success as compared to 60% in recession/resection procedures. 15 prism diopters deviations, six weeks following surgery was the parameter for under and over corrections. Over correction persisted in two cases for more than eight weeks post-operatively. They were given alternate occlusion followed by prismatic correction. A second surgery had to be performed in one case.

The remaining patients had residual exophoria and were treated with orthoptic exercises and prisms. Orthoptic therapy consisted of improving fusional amplitudes on synoptophore, home exercises with stereogram cards, teaching physiological diplopia etc. The follow-up period in our series varied from two months to 1 ½ years. It is commonly thought that bilateral recession gives better results in divergence excess cases but in our present study this was found to be true with basic type of exo-deviation as well.

Reference:


1. Hardasty, H.H, Boynton, J.R., and Keenan, J.P., Treatment of Intermittent Exotropia, Arch, Ophthalmol, 96 : 268, 1978.
2. Pratt-Johnson, J.A., Berlow, J.M., and Tilson, G : Early surgery for Intermittant Exotropia, Am, J.Ophthalmol 84 : 689, 1977.
3. Raab, E.L. and Parks, M.M. :recession of the lateral rectil, Arch, Ophthalmol, 82 : 203, 1969.

“Clip-on Lenses “ for Spectacle Binocular Indirect Ophthalmoscope

DR.MADHIVANAN NATARAJAN

Binocular Indirect Ophthalmoscope is the main tool for a total examination of the retina.


Pre-operative, intra-operative and post-operative retinal examination by the Indirect Ophthalmoscope is a must in retinal detachment surgery.



Clip –on lenses with bent hooks attached to the front surface

The Head-band Binocular Indirect Ophthalmoscope is very convenient for all practical purpose, and the same can be worn comfortably over the surgeon’s own spectacles as well.

The Spectacle model Binocular Indirect Ophthalmoscope has also gained wide popularity with retinal surgeons. The spectacle correction of each surgeon is incorporated in the ophthalmoscope for individual use. But in any situation where one ophthalmoscope has to be used by many surgeons, it is not possible to have the spectacle correction of each surgeon incorporated into the ophthalmoscope. To overcome this problem contact lenses are an asset. However the long hours of wear may make it difficult and sometimes impossible for many surgeons. This has led to the design of a simple device “CLIP-ON LENSES.”



Lenses hooked onto the spectacle model indirect ophthalmoscope.

The clip-on lenses essentially consists of a very thin and light metal frame without the ear supports. Metal hooks bent forwards are soldered to the upper horizontal position of the metal frame. The surgeons refractive correction is incorporated in the lens and this can be clipped on to the spectacle Indirect Ophthalmoscope.

Since this device is inexpensive and easily available it will be a great boon to those surgeons requiring their refractive correction in the spectacle model of the Indirect Ophthalmoscope.