

insight

Vol. XXVII No. 1

FEBRUARY 2009

Scientific Journal of
MEDICAL & VISION RESEARCH FOUNDATIONS
18, COLLEGE ROAD, CHENNAI - 600 006, INDIA

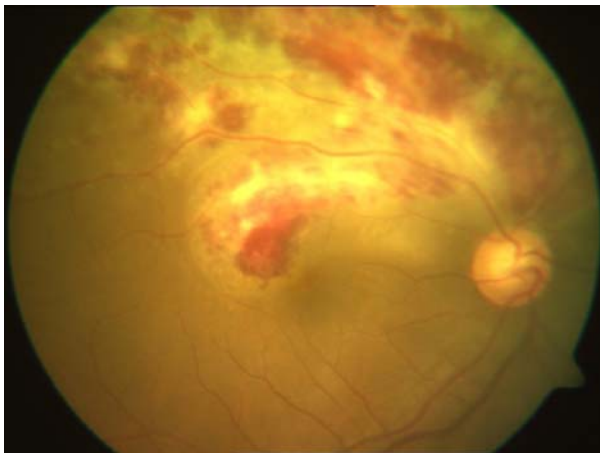
Editorial

Perspective — Acquired Immunodeficiency Syndrome and its Ophthalmic Complications - Part I — Aruj K Khurana - C.U.Shah Post Graduate Ophthalmic Institute, Sudharshan S - Dept of Uvea Services

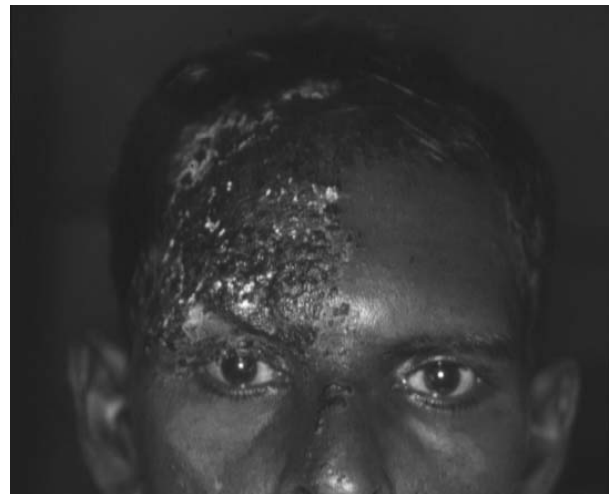A New Software for Analysing Iris Shape in Ultrasound Biomicroscopy Images — V Sekar, K Krishnakumar, Elite School of Optometry

Muscle Puzzle — Muralikrishna V, SN_ORBIS POLTC

Introduction to Biostatistics - 'Science' has the right to be written well!" - Classifying Variables by type — M. Thennarasu, Dr. V. V. Jaichandran, Dr. Vishnu Vahan Prasan, Dr. R. R. Sudhir, Department of Preventive Ophthalmology and Department of Anaesthesia



Pizza Pie Type CMV Retinitis



Herpes Zoster Ophthalmicus

EDITORIAL

HIV infection has gained tremendous public health importance in India and world wide. This issue's perspective talks about the ophthalmic complications in HIV in the first part of a two part series. The reader is introduced to biostatistics in an excellent article from the department of Preventive Ophthalmology. Iris shape factor, a new concept is discussed in detail in the article from the Elite School of Optometry. A muscle puzzle to put your thinking caps on follows.

Dr S Meenakshi - *Editor*

AN APPEAL

A lot of things in this world depend on money - security, shelter, education and even health. But at Nethralaya, money has ceased to be a pre-requisite for sight.

Day after day, year after year, Nethralaya treats hundreds of patients absolutely free of cost and gives them back their sight.

Yet there is no discrimination between the free patient and the one who pays. Apart from the treatment, food, medicines and travel expenses are absolutely free.

Those free patients depend on Nethralaya, and Nethralaya depends on you.

So, come and join the **SANKARA NETHRALAYA OM TRUST INC.**

For questions about tax exempt status and contributions, please contact:

Mr S V Acharya, Treasurer

Sankara Nethralaya OM Trust Inc.

9710, Traville, Gateway Drive, Rockville, MD 20850, U.S.A.

Phone: (301)251 0378

INTERNET e-mail : acharya@omtrust.org, snomtrustusa@yahoo.com

www.omtrust.org

For those of you in India and elsewhere, please contact:

Dr S S Badrinath, President & Chairman-Emeritus

Sankara Nethralaya

(UNIT OF MEDICAL RESEARCH FOUNDATION)

18 College Road, Chennai 600 006

Phone: 2826 1265, 2827 1616 Fax: (044) 2825 4180, 2821 0117

INTERNET e-mail : chairman@snmail.org

LOOK US UP ON THE WEB at <http://www.sankaranethralaya.org>, <http://www.omtrust.org>

GIVE ONLINE @ www.icicicommunities.org

Please notify change in your email to : akila@snmail.org (or) alagiri@snmail.org

COME, GIVE THE GIFT OF SIGHT

PERSPECTIVE:

Acquired Immunodeficiency Syndrome and its Ophthalmic Complications – Part I

Aruj K Khurana - C.U.Shah Post Graduate Ophthalmic Institute, Sudharshan S - Dept of Uvea Services

Acquired immunodeficiency syndrome (AIDS) is an infectious disease caused by a retrovirus, the human immunodeficiency virus (HIV). This syndrome is characterized by a gradual decrease in circulating CD4+ T-lymphocytes and subsequent development of various opportunistic infections and neoplasias. Although recognized initially in the United States, the AIDS epidemic entered its third decade with new cases being reported around the world. Moreover, spread of this infection continues to increase at an alarming rate, particularly in developing countries. The current national adult prevalence of HIV disease is 0.36% with around 2.51 million people being infected with this deadly virus according to the recent National AIDS Control Organization (NACO) estimates.

HIV/AIDS is a multisystem disorder and ophthalmic disease affects 45-70% of patients with HIV infection sometime during the natural history of their infection. HIV can affect the eye either directly or indirectly by means of various opportunistic infections. Visual morbidity is severe and blindness is one of the leading causes of suicide among AIDS patients.

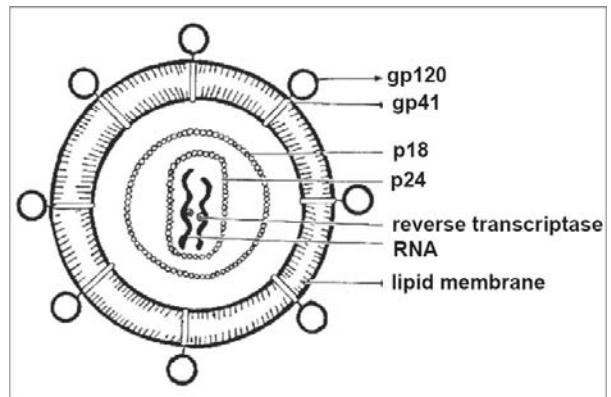
HIV infection is known to have a varied course, which over the years have been categorized into various syndromes such as AIDS-related complex, Persistent generalized lymphadenopathy and Lymphadenopathy Syndrome. However, the term 'HIV disease' better describes the illness. The term AIDS is reserved to define only the severe end of the spectrum, characterized by marked immunologic dysfunction.

The average incubation period from inoculation with HIV to the development of

AIDS is estimated to be 8 years with a reported range of 4 months to 10 years.

HUMAN IMMUNODEFICIENCY VIRUS

HIV is a retrovirus that is a member of the *Lentivirinae* subfamily. The virus (Virion) is 120 nm in diameter consisting of an outer envelope, a core shell of protein and a cone-shaped inner core containing RNA genome, core polypeptides and viral enzymes, including proteinase, integrase, and reverse transcriptase. Surrounding the capsid is a lipid envelope that is derived from the infected host cell and that contains virus-encoded glycoproteins. The viral genome contains three structural genes: *gag*, *pol*, and *env*.



Schematic diagram of a human immunodeficiency virus

IMMUNOLOGY and PATHOGENESIS

HIV affects virtually all components of the Immune system. Most profound consequence of HIV is impairment of cell-mediated immunity (T-Cell). HIV binds to CD4 receptor on T-cells. This host cell can be either latently or actively infected. If latently infected, no viral RNA is produced and a

productive infection may not develop. If actively infected, however, the cell may produce mature virions and cell death, which causes a gradual depletion of CD4+ T-Cells.

The CD4+ T-Cells or Helper T-Cells are responsible for inducing immune responses in other T-Cell and B-Cell systems. The depletion of this single T-Cell population therefore, leaves an immune system less able to mount Cytotoxic T-Cell responses to viral infected cells or cancers, to form Delayed Hypersensitivity reactions and to process foreign substances presented to it.

Humoral immune system is also significantly impaired in HIV infected individuals. Early in the course of HIV disease, a polyclonal B-Cell activation may be seen, leading to elevation of all major immunoglobulin classes (IgG,IgM,IgA). This directly results in fewer B-Cells that are left to respond to other immunologic challenges during the course of the disease. It may also play a role in increased incidence of high grade B-Cell lymphomas seen in AIDS patients.

Stimulated macrophages also express CD4 on their surface, and are thus also infected with HIV. Another mechanism of infection is through phagocytosis of HIV-antibody complexes via the Fc receptor. Observed dysfunctions in the macrophage-monocyte system include a decreased ability of monocytes to present antigens, a decrease in phagocytosis of opsonised bacteria and immune complexes by the macrophages, decreased migration response to chemo-attractants, defective intracellular killing of various microorganisms and a reduced expression of class II molecules. This may explain the increased infection rates of AIDS patients with encapsulated bacteria and excessive production of tumour necrosis factor alpha (by the macrophages), which leads to dementia, wasting syndrome and unexplained fever. The infected macrophages however, rarely undergo lysis or decrease in number. These cells harbour the virus, and are believed to disseminate the HIV virus throughout the body.

Non-specific immunity is also depleted in HIV infection with both a decrease in number and activity of Natural killer (NK) cells.

The illness that results from HIV infection varies from one individual to another. However, there are several predictable stages that lead invariably to death. In approximately half of cases, primary HIV-1 infection remains asymptomatic, whereas rest of the patients develop flu-like symptoms within the first four weeks after infection.

The acute HIV infection lasts usually for about one to two weeks and is characterized by symptoms typical of a non-specific viral illness. This is followed by an asymptomatic phase that can last for two to more than ten years. During this phase the CD4+ lymphocyte count varies from about 750 to 200 cells per cubic millimeter. The asymptomatic phase is followed ultimately by advanced HIV disease, which may last for upto three years; during this stage the CD4+ cells decrease to less than 200 per cubic millimeter. During primary infection, virus titers are extremely high in peripheral blood (up to 10⁸ HIV RNA copies/ml plasma) and the number of CD4+ T lymphocytes decreases significantly. The onset of HIV-specific cellular immune response and the subsequent synthesis of HIV-specific antibodies lead to the decline of plasma viral load to a patient-specific level and chronification of HIV infection. However, the asymptomatic stage of the infection is accompanied by persistent viral replication in lymph nodes and a rapid turnover of plasma virions and CD4+ T lymphocytes. During this clinically asymptomatic phase, the number of CD4+ T lymphocytes decreases continuously. As a consequence the patient's immune system is no more capable of controlling opportunistic pathogens and life-threatening AIDS-defining diseases emerge.

Transmission

Transmission of HIV is predominantly by sexual contact, by parenteral (intravenous drug use or mucous membrane exposure to contaminated blood or blood products), and

perinatally. HIV has been isolated from blood, semen, saliva, cerebrospinal fluid, tears, breast milk, amniotic fluid, vaginal secretions, cervical cells and bronchoalveolar lavage fluid. Transmission by sexual intercourse accounts for 70 to 80% of all cases ; intravenous drug use accounts for 5 to 10%; blood transfusion for 3 to 5%, and perinatal transmission for about 5 to 10% of the cases. The efficiency of transmission by a single exposure through these events varies tremendously.

Diagnosis

Laboratory investigations are essential to establish the diagnosis of HIV infection, which depends on demonstration of virus specific antibodies by enzyme- linked immunosorbent assay (ELISA) , Western blot and indirect immunofluorescence, virus antigen by enzyme immunoassay (EIA), direct isolation of HIV from the blood by culture, or detection of HIV nucleic acid by polymerase chain reaction (PCR) technology.

OPHTHALMIC COMPLICATIONS

Ophthalmic complications of HIV/AIDS can be grouped according to anatomical location, as:

- I. Adnexal and Anterior Segment Complications
- II. Posterior Segment complications.

OR

According to Mechanism, as:

- I. Opportunistic Infections
- II. Neoplasms
- III. HIV microvasculopathy
- IV. Iatrogenic /Post-treatment

Opportunistic Infections

Viral diseases

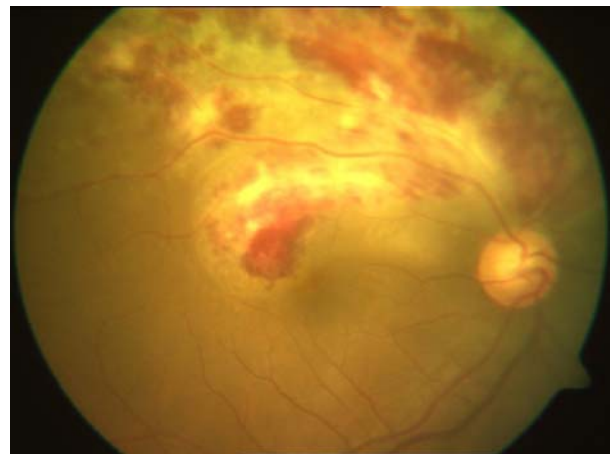
CMV infection

Cytomegalovirus retinitis is the most common AIDS-related ocular opportunistic infection seen in 40 to 50% of pre-HAART

AIDS patients. Infection is a result of hematogenous seeding of retina with infected monocytes, rarely however, it may also come from infected optic nerve. Around 52% cases develop bilateral disease. Cytomegalovirus retinitis occurs almost exclusively in patients whose CD4+ counts are <50 cells/ μ l.

There are two clinical forms of CMV retinitis. Both can occur simultaneously. The classical form is the hemorrhagic type (pizza pie retinopathy or cottage cheese with ketchup), characterized by confluent areas of whitened, necrosed retina with hemorrhages that develop mostly in the posterior retina. The advancing edge of these lesions is usually very sharp and spreads contiguously. The pattern of spread has been termed 'Brush fire pattern'. It typically shows wedge shaped areas of necrosed retina with a yellow-white margin of retinitis.

Patients often have loss of visual field or visual acuity and a scotoma.



Pizza Pie Type CMV Retinitis

In contrast a granular form is seen in the peripheral retina, often with little or no haemorrhages . Patients may notice floaters, or they may be asymptomatic.

Routine screening with dilated indirect ophthalmoscopy has been recommended at monthly intervals in patients with CD4+ counts less than 100 cells/ μ l.

Cytomegalovirus retinitis may result in either serous or rhegmatogenous retinal detachment, with latter being much more

common. Retinal detachment can be seen during active as well as quiescent disease, with retinitis usually extending up to pars plana.

Diagnosis is clinical, with typical features in an immunocompromised patient. Positive blood and urine cultures are not diagnostic and vitreous cultures are usually negative. In atypical cases, polymerase chain reaction (PCR) from intraocular fluids is helpful in diagnosis.

Treatment includes systemic use of anti-CMV drugs and restoration of immune status with HAART. Currently available anti-CMV agents include ganciclovir and its prodrug valganciclovir, foscarnet, cidofovir, fomivirsen, ganciclovir implant. These drugs along with HAART slows progression and sometimes help in resolution of lesions.

Ganciclovir is given i/v with an induction dose of 2.5-5.0mg/kg every 8-12 h for 2-3 weeks followed by 5mg/kg once daily for 5-7 days a week till complete resolution.

An intravitreal injection of 200mg in 0.1ml sterile water through pars plana, 1-3 times per week can also be given as a supplement, or to prevent additive toxicity with zidovudine. Side effects include a reversible bone marrow toxicity with neutropenia and thrombocytopenia and electrolyte imbalance.

Foscarnet is given as i/v bolus injection of 20mg/kg over 30 mins, followed by a continuous infusion of 230mg/kg/day. Nephrotoxicity is the major side effect.

Cidofovir has shown a good response with relatively infrequent dosing. Induction dose is 5mg/kg i/v once a week for 2 weeks, followed by maintenance therapy once every other week. It may cause a paradoxical increase in inflammation, and rarely may lead to hypotony.

Anterior segment involvement in CMV infection is rare. CMV has been reported to be associated with both epithelial and/or stromal keratitis, although both conditions are uncommon.

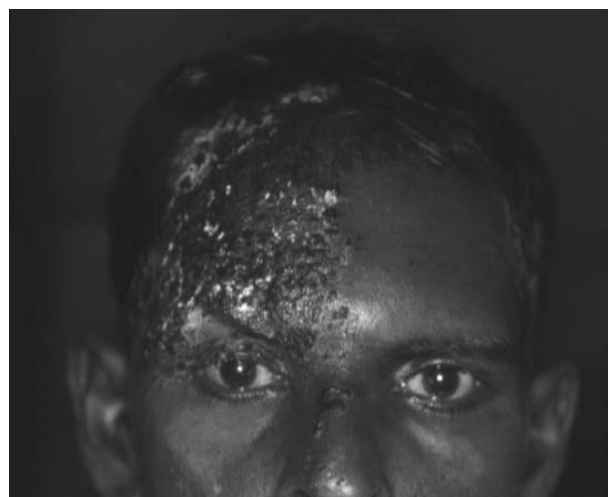Corneal endothelial deposits have been described in eyes with CMV retinitis. These asymptomatic lesions, seen in up to 81% of cases of HIV/AIDS-related CMV retinitis appear as linear or stellate lesions and form a reticular pattern. Best visualized in retroillumination, they are commonly found in the inferior cornea. These deposits are known to be composed of fibrin and macrophages, with no active CMV infection.

Herpes zoster ophthalmicus

Herpes zoster ophthalmicus (HZO) is caused by varicella zoster virus (VZV).

The virus usually remains latent in sensory ganglia, most commonly trigeminal ganglia. It can reactivate in response to local surgery/trauma or in the setting of depressed cell-mediated immunity and is usually seen in elderly. The condition presenting in any young patient should give rise to a suspicion of HIV.

Clinically it is characterized by vesiculobullous rash over the distribution of the ophthalmic branch of the trigeminal nerve and may be associated with dendritiform and stromal keratitis, conjunctivitis, blepharitis, uveitis (with secondary glaucoma), hemorrhagic hypopyon, scleritis, retinitis or encephalitis. Tissue damage can be mediated through a necrotizing vasculitis.



Herpes Zoster Ophthalmicus

Incidence of HZO is greater in HIV-infected individuals than in non-infected, age-

adjusted populations. It can even be an initial manifestation of HIV.

In immunosuppressed individuals, herpes zoster is more likely to be severe, prolonged, and can lead to viremia, which may result in visceral or neurologic infection. Both epithelial and stromal disease has been described in the absence of skin lesions, a condition named as herpetic zoster sine herpete. Another presentation is that of a chronic VZV infection of the corneal epithelium. Lesions of chronic VZV epithelial keratitis in HIV-infected individuals are pleomorphic, often with multiple components and associated with thickened opaque epithelium. They tend to be more delicate and lacy in appearance than the discrete dendrites of HSV epithelial keratitis or the classic, broad, plaque-like VZV dendrites .

Diagnosis of HZO is mainly clinical. To confirm a clinical diagnosis, however, various tests are available, including virus cultures, Tzanck smears, polymerase chain reaction (PCR) techniques for VZV DNA, fluorescent antibody testing, and antigen detection by direct immunofluoresence.

Treatment of HZO in individuals with HIV disease requires aggressive initial treatment, with intravenous acyclovir, followed by a prolonged course of oral antivirals as "maintenance therapy," to prevent recurrence. The regime is intravenous acyclovir 10 mg/kg of body weight eight-hourly for seven days followed by an oral maintenance regimen of 800 mg five times a day for at least three to six weeks. In resistant cases, famciclovir can be used three times daily in 500 mg dosages as well. In cases of resistance to thymidine kinase-dependent acyclovir or famciclovir, IV foscarnet may be used.

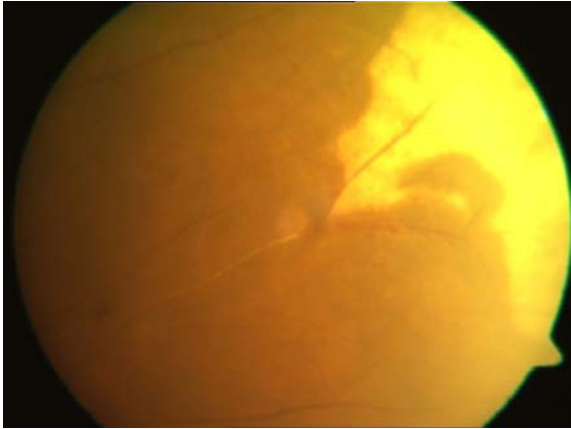
Patients with a history of HZO on a HAART regimen may be susceptible to immune recovery. With increase in CD4 counts, T-cells presumably recognize and respond to residual VZV antigens in the

corneal stroma to cause the keratitis. HAART (with protease inhibitors) may therefore, potentially double the incidence of herpes zoster and related ocular involvement in AIDS patients, although treatment with nucleoside analogue reverse transcriptase inhibitors does not pose the same risk.

Some patients develop severe and debilitating post-herpetic neuralgia after resolution of the oculocutaneous lesions. Post-herpetic neuralgia can be treated with analgesics and anti-inflammatory drugs such as topical lidocaine cream (5%). Acyclovir therapy, initiated within 72 h of onset of skin rash, also reduces the risk of post-herpetic neuralgia. Pain relief in severe cases may be obtained with amitryptiline (25 mg to 150 mg orally daily in slowly increasing dose). Opioids have been found to be more potent and better tolerated than tricyclic antidepressants. Currently, gabapentin, up to 3,600 mg per day in three divided doses, is the first-line treatment for post-herpetic neuralgia.

Retinal involvement shows a variable but continuous spectrum of posterior segment inflammation. Its two most recognizable clinical patterns are Acute Retinal Necrosis (ARN) and Progressive Outer Retinal Necrosis (PORN). Together these clinical presentations have been given the term 'necrotizing herpetic retinopathy', caused by VZV or HSV with VZV being more common.

Acute Retinal Necrosis (ARN), usually occurs in healthy persons and AIDS patients with only mild immune dysfunction and elevated CD4+ counts. Herpes virus reaches retina by neural pathway from brain. Clinical features include ocular pain, photophobia and floaters with an episcleral injection and granulomatous KP's. Fundus shows confluent areas of retinal necrosis which coalesce peripherally, retinal occlusive vasculitis, arteritis, a moderate to severe vitritis and often optic neuritis. 30-80% cases are bilateral. Treatment With i/v Acyclovir may be helpful. Primary cause for vision loss is rhegmatogenous retinal detachment.



Progressive Outer Retinal Necrosis

Progressive Outer Retinal necrosis (PORN), usually develops in those who are severely immunosuppressed. Other features include a primary involvement of outer retina and minimal vitreal inflammation. Retinal vasculitis and anterior segment inflammation are minimal. Response to i/v Acyclovir is poor with early blindness resulting from either retinal detachment or total retinal destruction.

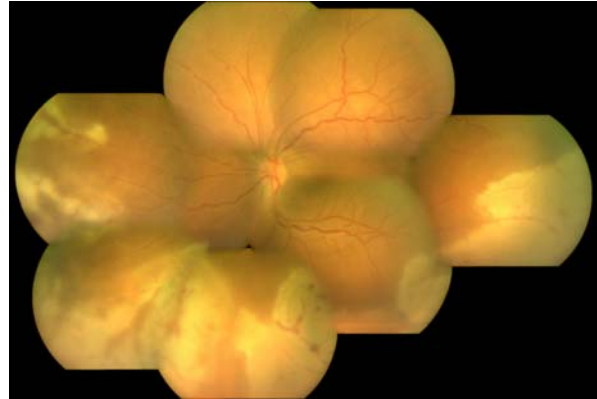
In addition to varicella zoster virus, herpes simplex virus and CMV have been isolated in patients with ARN, and herpes simplex in eyes with PORN.

Herpes Simplex Viral keratitis

Although ocular infection is usually known to occur with HSV-1, documented cases of HSV-2 ocular infection have also been reported.

Herpetic keratitis causes painful and often recurrent corneal ulcerations with a characteristic branching or dendritic pattern on slit-lamp examination. Epithelial keratitis typically appears in conjunction with follicular conjunctivitis and vesicular eyelid lesions; stromal and interstitial keratitis present less frequently. HSV keratitis is usually associated with corneal scarring, iritis and raised intraocular pressure and is known to recur frequently.

VZV keratitis may be accompanied by herpes zoster ophthalmicus in 65% of individuals. Among those with corneal involvement, neurotrophic keratitis occurs in



Acute Retinal Necrosis

25% and rarely, superadded bacterial infection can occur.

Corneal stromal involvement has been reported infrequently in individuals with AIDS or other immunosuppressed states. It is thus possible that the T-lymphocyte dysfunction in HIV-infected individuals may actually protect them from developing HSV stromal disease. Punctate corneal dendritic lesions in HIV-positive hosts do not differ from those seen in immunocompetent hosts except that they are larger and more peripherally located. The pathognomonic bulb-tipped branching pattern seen on slit-lamp examination, however, remains the same in both groups and helps confirm the clinical diagnosis.

Atypical clinical features of the disease, include a predilection for marginal, as opposed to central epithelial keratitis, a relative resistance to treatment and more frequent and lengthier recurrences.

Diagnosis of HSV infection is primarily clinical, but laboratory studies, including viral culture, direct fluorescent antibody tests for HSV antigens and PCR techniques for HSV DNA can help to confirm the diagnosis.

Treatment is commonly with topical agents such as acyclovir eye ointment five times daily or vidarabine ointment 3% five times daily and cycloplegics. Debridement of the ulcer using a cotton-tip applicator may increase the healing rate.

According to Herpetic Eye Disease Study group long-term suppressive oral acyclovir

therapy (400 mg twice daily for one year) reduces the rate of recurrent HSV epithelial keratitis and stromal keratitis. Long-term suppressive oral acyclovir therapy may also benefit HIV-infected individuals with a history of HSV eye disease.

In resistant strains, famciclovir 125 to 500 mg three times daily or foscarnet can be substituted instead of acyclovir.

Interferon has also been used for the treatment and prevention of HSV epithelial keratitis.

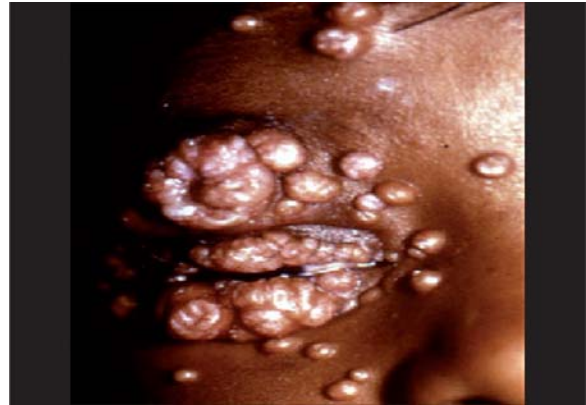Molluscum contagiosum

Molluscum contagiosum, caused by a large DNA called *pox virus*, affects up to 5% of HIV-infected patients and is highly contagious. It is transmitted by direct contact and has an incubation period of six to eight weeks and is seen in children and young adults.

In HIV-positive individuals, lesions can occur in the eyelid and conjunctiva and are characteristically larger in number and size, often confluent, bilateral and resistant to therapy than immunocompetent counterparts. Face, trunk and genitalia are commonly affected. A distribution in the chin-strap region is common in HIV-positive patients.

Molluscum contagiosum lesions of the eyelid have even been reported as the initial clinical manifestation of HIV disease. It is characterized by pink or pearly white wart-

like nodules on the skin. Sections of the lesions show large (20 to 30 microns) eosinophilic hyaline inclusion bodies which displace the nuclei to the margin. These bodies are composed of large numbers of virus particles, embedded in a protein matrix.



Molluscum Contagiosum in AIDS.

Treatment options include usage of topical agents like phenol and trichloroacetic acid or serial applications of liquid nitrogen. Incision with or without curettage, excision, and cryotherapy are equally effective. Despite treatment, eyelid lesions commonly recur in patients with AIDS, usually within six to eight weeks, corresponding to the incubation period of the virus. Administration of HAART with restoration of immunity leads to complete resolution of disseminated molluscum contagiosum and limitation of infection.

Did you know the following employers have supported

Sankara Nethralaya OM Trust Inc.

through their Gift Matching/Payroll Deduction Programmes ?

Please check with your employer and multiply your contribution to the Trust

Microsoft, Deutsche Bank, American Express, Merrill Lynch, J P Morgan Chase, GE Foundation, The Bank of New York Mellon, Google, eBay Foundation, Qualcomm, Educational Testing Services, Cadence, Charles Schwab Foundation, First Data, Mc Graw Hill Cos., Merck, All State, Verizon, and The Northern Trust

PERSPECTIVE:

A New Software for Analysing Iris Shape in Ultrasound Biomicroscopy Images

V Sekar, K Krishnakumar, Elite School of Optometry

Aim: To analyse iris shapes in Ultrasound Biomicroscopy (UBM) images by developing a software using MATLAB 7.2.

Methods: A software using MATLAB 7.2 was developed to trace the anterior iris surface in UBM images. The software flips the images to the left side, enhances the contrast, denoises and resizes the images to 500 x 500 pixels. These images are then rotated to a standard position and binarized. The user is then asked to choose the iris insertion. In case of narrow angles, the iris insertion is chosen and the initial portion of the anterior iris surface is traced manually by the user before binarization. The software then automatically traces the anterior surface of the iris to 2.5 mm horizontally and calculates the area, termed Iris Shape Factor (ISF), under the traced iris at 0.5mm, 1.0mm, 1.5mm, 2.0mm and 2.5mm. Inter and intra-observer reliability of the measurement of ISF was calculated. The ISF was measured on UBM images of 23 normal eyes and 21 narrow angle eyes.

Results: Inter and intra-observer reliability of measurement of ISF for normal and narrow angle eyes were good (CV < 10%). Significant difference in ISF was found between normal and narrow angle eyes at 0.5mm (p=0.002), 1.0mm (p=0.048) and 1.5mm (p=0.017) using student's t-test.

Conclusion: The measurement of ISF using the newly developed software was found to have good inter and intra observer reliability. ISF could differentiate normal angle eyes from narrow angle eyes.

Keywords: Iris shape factor, Narrow angles, Ultrasound Biomicroscopy.

Introduction:

While glaucoma is recognized as a major cause of ocular morbidity worldwide, it has been a clinical impression in India that primary angle closure glaucoma (PACG) is more common than primary open angle glaucoma (POAG).¹

In angle closure glaucoma (ACG), the iris is abnormally positioned and physically impedes the aqueous humor outflow through trabecular meshwork. This condition can be caused by one or more abnormalities in sizes or positions of anterior segment structures or by abnormal forces in posterior segment that alter the anatomy of anterior segment.² Forces generated to cause angle closure in four anatomic sites include, the iris (pupillary block), the ciliary body (plateau iris), lens (phacomorphic glaucoma), behind iris by combination of various forces (malignant glaucoma).³

With the advent of high frequency Ultrasound Biomicroscopy (UBM), the imaging of the anterior segment became easy. The main advantage of UBM is its high reproducibility and its accuracy.⁴ It enables us to measure linear and angular parameters capable of defining the characteristics of normal and glaucomatous eyes.⁵ UBM has in built software, which helps us to do various measurements on UBM images. Software called UBM Pro2000⁶ helps us to measure parameters like the angle recess area, anterior chamber depth, anterior chamber angle, Trabecular Ciliary process distance and iris ciliary process distance. Both softwares are incapable of measuring the iris configuration, either directly or indirectly.

Spaeth et al.⁷ based on subjective observations, have shown variations in iris configuration in both normal and narrow angle eyes. Using slit lamp photographs, Lin et al.⁸ have shown variations in iris configuration in both normal and narrow angle eyes by tracing the iris surface and modeling the trace as a parabolic curve. A radius measured at the apex of the curvature of the parabola, named iris radius (IR), was calculated as a measure of the degree of the curvature of the iris contour. Their study showed mean iris radius to be significantly different between normal and glaucomatous eyes. Wang et al.⁹ also measured the iris radius and showed good inter and intraobserver reliability. Lee, Brubaker and Illstrup used biometric photography to analyse iris configuration before and after surgical iridectomy.¹⁰

Our study, presented in this paper, describes a new algorithm for quantifying the iris configuration. Using this algorithm the area between the iris anterior surface as seen in the UBM image and the horizontal line is measured. We call this area the Iris Shape Factor (ISF). Flatter irises will have smaller values of ISF than convex irises.

Methods:

The research described in this paper was carried out in three distinct phases:

Phase I: Development of new software for quantifying iris configuration by tracing the anterior surface of the iris in UBM images and calculating the area under the traced curve.

Phase II: Measurement of inter and intra-observer reliability of the new software.

Phase III: Comparison of the iris configuration as defined by ISF between normal and narrow angle eyes.

All UBM images used in this study were obtained from the Department of Glaucoma, Medical Research Foundation, Chennai. IRB approval for obtained prior to the conduct of this study and the study was conducted as per the Declaration of Helsinki.

Phase I

Software using MATLAB 7.2 was developed to quantify iris configuration by measuring the area beneath the iris. The flow chart given in figure 1 shows the steps involved in the development of the new software.

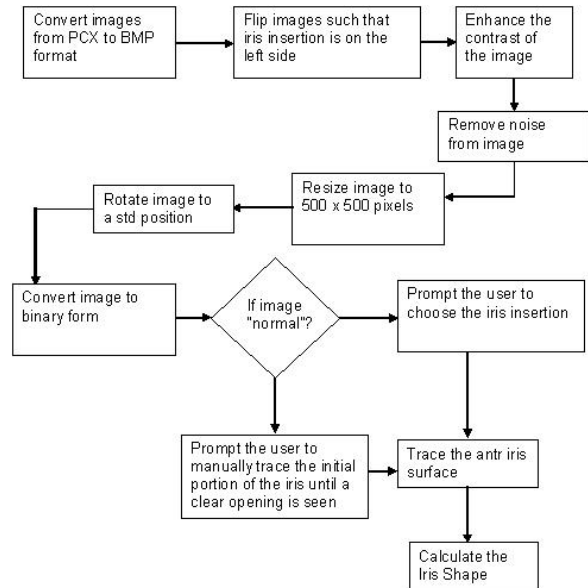


Figure 1: Flow chart showing the steps involved in the development of the software

UBM images (normal angles and narrow angles) were originally in the PCX formats. All images were pre-processed, binarised and then the iris was traced.

Pre-processing consisted of converting the PCX formatted images into bitmap files. The images were then resized to 500 x 500 pixels using nearest neighbour interpolation. This standardization of the size eased the process of comparing images obtained from various patients. These bitmap images were then flipped in such a way that the iris insertion was on the left side of the image (figure 2).

The next step was image enhancement. Image contrast was enhanced such that 1% of the data was saturated at the highest and lowest intensity values. A flood fill operation was performed on the background of the contrast-enhanced image. This helped to remove the noise in the background.

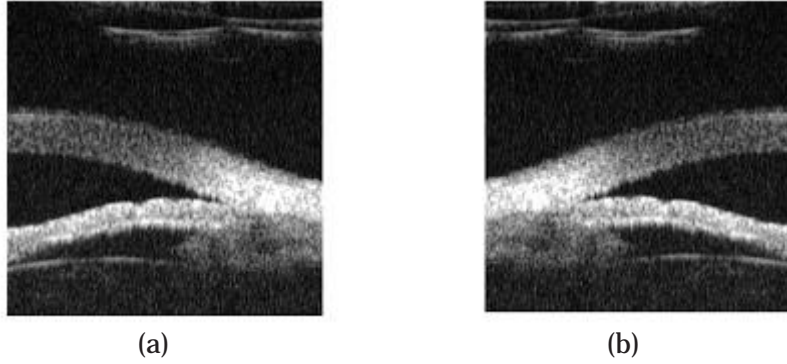


Figure 2: (a) Original Image; (b) Flipped image. The iris insertion in the first image is in the right half of the image while in the flipped image it is in the left half.

Further standardization of the images was done by rotating the image to a standard orientation. For this a standard angle θ was defined as the angle formed by a triangle whose sides were, (i) a line drawn from iris insertion O to a point A that is at a distance of 2.5mm horizontally (The horizontal visible diameter of the iris is about 12mm,¹¹ of which about the central 4mm makes the aperture (pupil). The distance between the pupillary border and the iris root is about 4mm. It will vary from person to person. Therefore, for all images, we traced the anterior surface of the iris to 2.5 mm horizontally from the iris root using our software.), (ii) a perpendicular from A to anterior corneal surface B and (iii) a line joining O and B (figure 3). If the calculated θ for the image was less than the standard, the image was rotated anti clockwise; if it was more then the image was rotated clockwise.

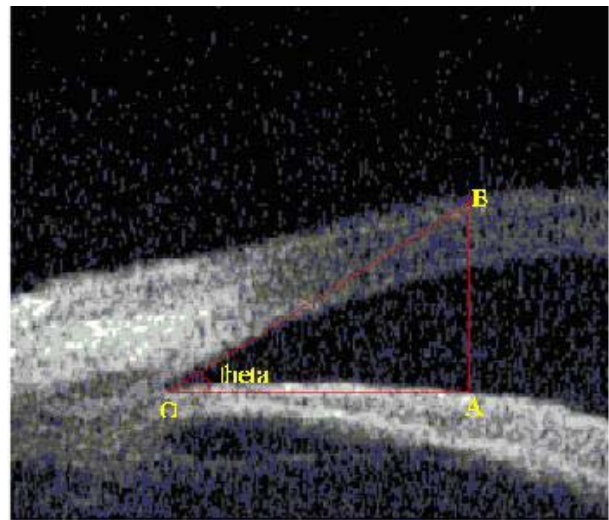


Figure 3: The standardization angle θ (see text for definition).

This angle θ was calculated for all the straight images using UBM Pro2000 software. The average angle (θ) was found to be 43.37 degrees for normal angle images and 33.92 degrees in narrow angle images. The angle of each image was calculated and compared to that of average angle given above. All images were rotated in such a way that they have the angle equivalent to that of the calculated average angle.




Figure 4: Binary image

Following this image rotation, image binarisation was done using Otsu's method of greyscale threshold.¹² Then the perimeter of the binary image was traced (figure 4) and the image was further cleaned of any spurious pixels.

Following binarization, the iris origin was selected manually by clicking the mouse on the white part of the image at iris insertion site. The program automatically traces the iris from the selected point to 2.5mm horizontally. The program connects all the white regions from the selected point to 2.5mm horizontally.

In case of iridocorneal contact (figure 5a), the binary image provides false iris insertion point of origin (figure 5b). Hence, the contact part of iris surface was traced manually before converting into a binary image (figure 5c and 5d). The software automatically traces the remainder up to 2.5mm horizontally.

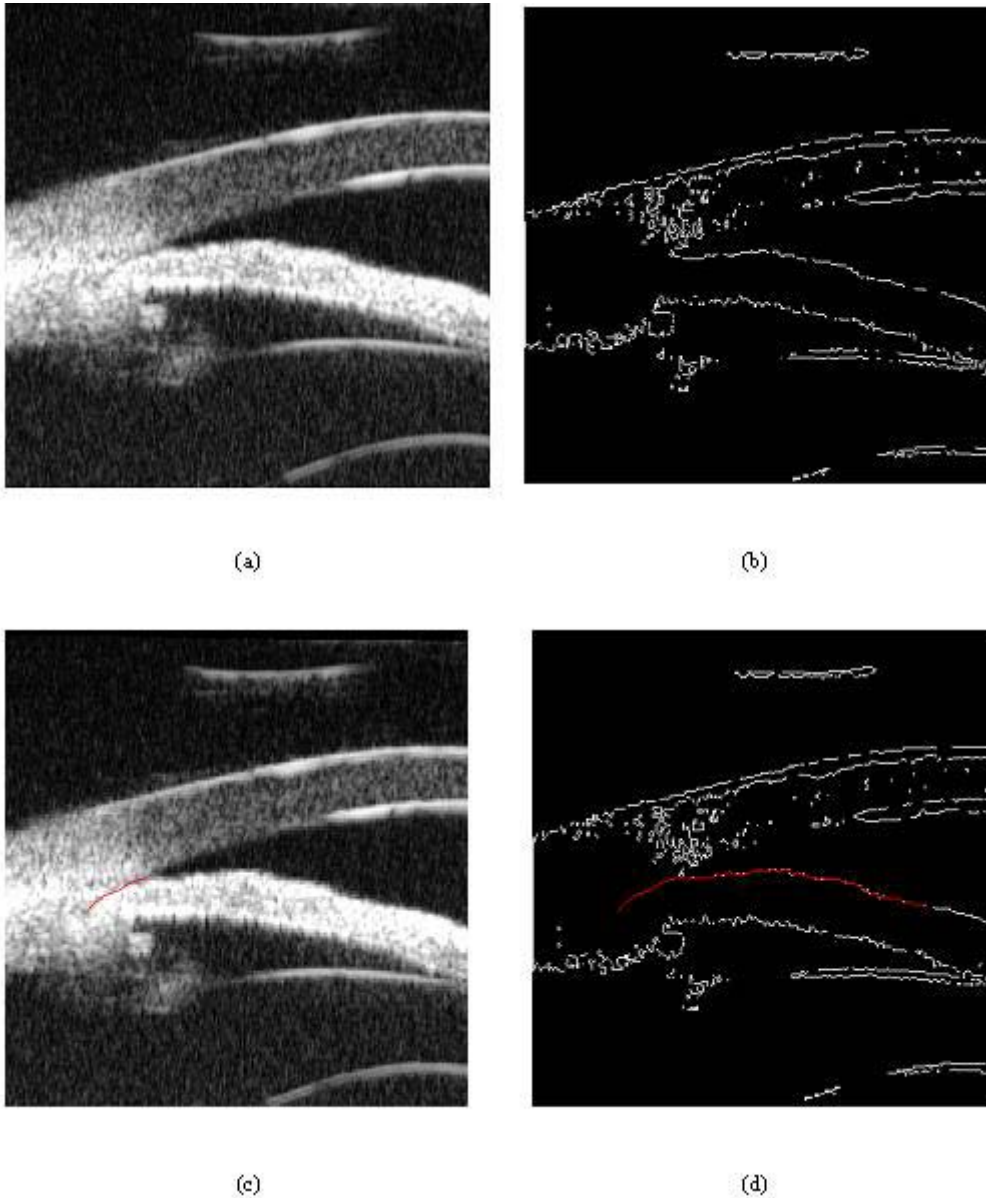


Figure 5: (a) UBM image of an angle closure eye, (b) Binary image showing false iris insertion or origin for trace, (c) Manual tracing of the iris before binarisation, (d) Binary image of figure in (a) with iris traced up to 2.5 mm horizontally. Then the traced iris was plotted in a graph (figure 6).

By integrating the area under the plotted curve, the iris shape was calculated at

0.5mm, 1.0mm, 1.5mm, 2.0mm and 2.5mm. The calculated area gives the Iris Shape

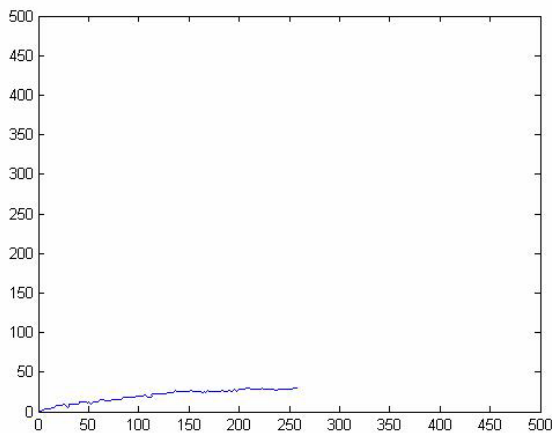


Figure 6: Graph representing the iris traced from a UBM image of an individual eye. The origin is at the iris insertion.

Factor (ISF). The larger the ISF, the more convex will be the iris configuration. For example, the eye with an ISF of 0.5 mm^2 will have a flatter iris than an eye with ISF of 1.0 mm^2 .

Phase II

The goal of this phase of the project was to evaluate inter and intra observer reliability of measurement of ISF. The subjectivity in this project appeared only in the selection of the iris insertion for normal angle eyes and tracing of the initial portion of the iris from iris insertion in narrow angle eyes. This subjectivity could potentially result in unreliable measurements of the ISF. We tested reliability of the ISF measurement by studying both inter and intra observer reliability upto maximum iris length of 2.5mm.

UBM images from all the quadrants were obtained from 57 primary angle closure suspects (PACS) patients seen by one of the authors between March 2003 and July 2003 at the glaucoma clinic of Medical Research Foundation, Chennai. For each patient, one good UBM image was selected. The criteria for selection of a UBM image were clear anterior corneal surface and iris insertion and the presence of the iris insertion in the left half of the image. For inter observer reliability measurement, three experienced examiners, masked to each other, measured the ISF of

11 randomly selected images using the new software. For intra observer reliability measurement, the same 11 images were used to measure ISF twice by all three examiners. The time interval between the first measurement and the second measurement by a single examiner was at least a week. One of the examiners made the second measurement after two months of making the first measurement while the other two had one week gap between the two measurements. Based on the data obtained inter and intra observer reliability using coefficient of variation (CV) was measured. CV less than 10% was considered indicative of good reliability.¹³

Phase III

The goal of this phase of the project was to compare iris configuration in normal and narrow angle eye by measuring their ISF. 21 images of PACS subjects were used for the study. We selected age matched normal angle subjects (defined as Shaffer grade 3 or more) from previously collected normative data for UBM. A trained ophthalmologist performed the UBM and gonioscopy for all the normal subjects using the same protocol.¹⁴ The demographics and ocular biometry data were taken from the medical records except for UBM measurements. 23 images out of 57 normal UBM images were selected randomly. One of the authors calculated the ISF for 23 normal and 21 narrow angle images. Student's "t" test was done to compare the ISF for normal and narrow angle eyes. $p < 0.05$ was assumed to be statistically significant.

Results:

The individual ISF measurements as measured by the three observers are given in the Tables 1. Inter and intra observer reliability for calculating ISF using CV was found to be good (Table 2). The ISF of normal eye was found to be significantly less when compared to that of narrow angles at 0.5mm, 1.0mm, and 1.5mm but there is no significant difference found at 2.0mm and 2.5mm (Figure 7 and Table 3).

Table 1: ISF (mm²) Measurements as measured by three observers on UBM images of 11 normal and 11 narrow angle eyes

Patient	Normal Eyes			Narrow angle Eyes		
	Observer 1	Observer 2	Observer 3	Observer 1	Observer 2	Observer 3
1	0.14	0.3	0.32	1.32	1.46	1.51
2	0.51	0.62	0.62	1.18	1.26	1.19
3	0.53	0.58	0.65	1.33	1.57	1.06
4	0.41	0.49	0.48	0.9	1.61	1.62
5	0.21	0.26	0.25	1.24	0.96	0.95
6	0.53	0.66	0.68	0.98	0.72	0.61
7	0.68	0.7	0.73	0.87	1.39	1.08
8	0.3	0.38	0.38	0.96	0.87	0.8
9	0.32	0.27	0.38	0.82	0.86	0.92
10	0.73	0.68	0.71	1.91	1.82	1.77
11	0.34	0.36	0.38	0.77	0.83	0.79

Table 2: Inter and intra observer reliability of ISF measurement in normal and narrow angle eyes. Percentage coefficients of variation are given for parameters measured by observers

	Intra observer Reliability			Inter observer Reliability
	Observer 1	Observer 2	Observer 3	
Normal	4.17	4.82	5.21	8.65
Narrow angle	2.29	2.29	0.45	4.84

Table 3: Comparison of Mean ISF of normals (n=23) and narrow (n=21) angle eyes

	Normals (in mm ²)	Narrow angles (in mm ²)	95% CI Difference in Means	p value
AT 0.5mm	0.02 ± 0.02	0.04 ± 0.02	(-0.03, -0.007)	0.026*
AT 1.0mm	0.09 ± 0.06	0.15 ± 0.05	(-0.09,-0.01)	0.048*
AT 1.5mm	0.18 ± 0.11	0.26 ± 0.11	(-0.16,-0.01)	0.017*
AT 2.0mm	0.27 ± 0.17	0.37 ± 0.20	(-0.21,0.01)	0.086
AT 2.5mm	0.32 ± 0.27	0.45 ± 0.31	(-0.31,0.04)	0.133

*Significant difference, by Independent student 't' test using p < 0.05 level, CI indicates confidence intervals

Discussion:

This was the first study that developed software to measure the area beneath the anterior contour of the iris and thereby quantifying the iris configuration. There were

studies^{7, 15, 16, 17} that attempted to understand the iris configuration. The study done by Spaeth^{15,7} evaluated the iris configuration subjectively and classified the iris configuration into "q" type when there

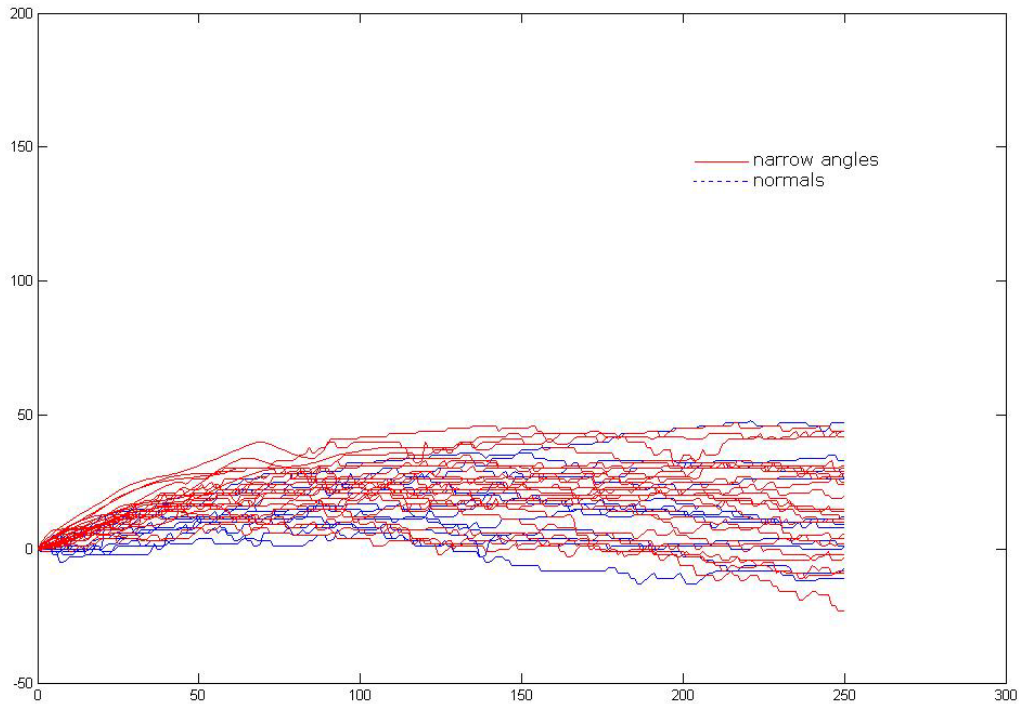


Figure 7: Graph showing the anterior iris surfaces in normal and narrow angle eyes. The x-axis is the distance from the chosen iris insertion (in mm). The y-axis is the height of the iris surface (in mm) from the horizontal through the iris insertion. Continuous red lines are iris surfaces in narrow angle eyes and the blue dashed lines are from normal eyes. It is clearly seen that the ISF of normal eyes are much smaller than those of narrow angle eyes closer to iris insertion site.

was posterior iris concavity, "r" type when there was flat iris or a mild regular curvature without sudden change in the curve and "s" type when there was a plateau appearance with a sudden anterior convexity, bending sharply to a flat iris centrally. The limitation of the study was that it was a subjective evaluation. But, inter and intra observer agreement was high for this subjective measurement.

Potash et al.¹⁶ tried to quantify iris configuration in UBM images with the inbuilt calipers of the instrument. Iris concavity was determined by drawing a line from the most peripheral to the most central points of iris pigment epithelium. A line was drawn from this line to the iris pigment epithelium at the point of greatest concavity or convexity. A concave or convex surface was determined to exist when there was a measurable difference between the plane of the iris pigment epithelium and the initial reference line.

Negative values were assigned to concave irises, positive values indicate convex irises and zero represents planar irises. Though it could solve the problem related to quantification using the callipers in the instrument, the subjective assessment of the greatest concavity or convexity was a limitation. There was no literature on reproducibility of the technique.

Jin et al.¹⁷ attempted to understand the iris contour after iridotomy and demonstrated the iris convexity before iridotomy and no perceptible change after iridotomy. They used photographs obtained using Scheimpflug principle. Computer corrected images of these photographs were used for quantifying the anterior chamber depth. The iris configuration changes were subjectively documented without any quantification.

The present software developed by us using MATLAB 7.2 took into account the limitations of the previous studies and

attempted to solve the major issue of subjectivity in measuring iris configuration. Except for the identification of the reference point at the iris insertion area, the steps in calculating the ISF were automated. The only limitation of the software was that manual iris tracing was required before calculating the ISF in cases of angle closure (synechial or appositional angle) UBM images. The images need to be converted from PCX to BMP format using UBM pro 2000. Inter and intra observer reliabilities among normal angle eyes and narrow angle eyes were good. On analysing the ability of the ISF to differentiate normal angle eyes from narrow angle eyes, it was found that the parameter could differentiate between the two groups quite well upto 1.5mm from the site of iris insertion. However beyond 1.5mm upto 2.5mm it could not differentiate between normal and narrow angle groups. UBM parameters as given by Pavlin et al.¹⁸ have to be measured manually, whereas the ISF measurement was a more automated method.

Patient's clinical data, namely, intraocular pressure, anterior chamber angle, anterior chamber depth, axial length, lens thickness, cup to disc ratio, and severity of the disease were not taken into consideration for the study. Future studies using this software and comparing these traditional parameters measured using conventional techniques with ISF might help us to decide on the usage of ISF in clinical practice. A study with a larger sample size on different types (open angle, angle closure, plateau, pigmentary) and stages of glaucoma would help us to evaluate the efficacy of the software in differentiating one condition from the other.

References:

1. Quigley HA. Number of people with glaucoma worldwide. *Br J Ophthalmol*. 1996 May; 80(5):389-93. Review.
2. Stamper RL, Lieberman MF, Drake MV, Becker. *Shaffer's Diagnosis and therapy of the glaucomas*. 7th ed. St. Louis Mosby, 1999.
3. Huang EC, Barocas VH. Active iris mechanics and pupillary block: Steady-state analysis and comparison with anatomical risk factors. *Ann Biomed Eng*. 2004 Sep; 32(9):1276-85.
4. Pavlin CJ, Harasiewicz K, Sherar MD, Foster FS. Clinical use of ultrasound biomicroscopy. *Ophthalmology*. 1991 Mar; 98(3):287-95.
5. Pavlin CJ, Harasiewicz K, Foster FS. Ultrasound Biomicroscopy of anterior segment structures in normal and glaucomatous eyes. *Am J Ophthalmol*. 1992 Apr 15; 113(4):381-9.
6. Ishikawa H, Liebmann JM, Ritch R. Quantitative assessment of the anterior segment using Ultrasound Biomicroscopy. *Curr Opin Ophthalmol*. 2000 Apr; 11(2):133-9. Review.
7. Spaeth GL, Azuara-Blanco A, Araujo SV, Augsburger JJ. Intraobserver and interobserver agreement in evaluating the anterior chamber angle configuration by ultrasound biomicroscopy. *J Glaucoma*. 1997 Feb;6(1):13-7.
8. Lin D, Jiang YQ, Wu ZZ. A method of measuring iris radius by computerized image analysis. *Zhonghua Yan Ke Za Zhi*. 1994 Nov; 30(6):449-52. (Abstract only)
9. Wang N, Lai M, Zhou W. Quantitative real time measurement of iris configuration in human eyes. *Yan Ke Xue Bao*. 1997 Mar; 13(1):29-34. (Abstract only)
10. Lee DA, Brubaker RF, Illstrup DM. Anterior chamber dimensions in patients with narrow angles and angle closure glaucoma. *Arch Ophthalmol*. 1984 Jan; 102(1):46-50.
11. A.K. Khurana. *Anatomy and Physiology of eye*. 1st edition. CBS Publishers and Distributors; 2004
12. N. Otsu, "A Threshold selection method from gray-level histograms," *IEEE Transactions on Systems, Man, and Cybernetics*, vol. 9, no. 1, pp. 62-66, 1979

13. Tello C, Liebermann J, Potash SD, Cohen H, Ritch R. Measurement of ultrasound biomicroscopy images: intraobserver and interobserver reliability. *Invest Ophthalmol Vis Sci.* 1994 Aug; 35(9):3549-52.
14. Arun N, Vijaya L, Shantha B, Baskaran M, Sathidevi AV, Baluswamy S. Anterior chamber angle assessment using gonioscopy and ultrasound biomicroscopy. *Jpn J Ophthalmol.* 2004 Jan-Feb; 48(1):44-9
15. Spaeth GL. The normal development of the human anterior chamber angle: a new system of descriptive grading. *Trans Ophthalmol Soc U K.* 1971; 91:709-39.
16. Potash SD, Tello C, Liebmann J, Ritch R. Ultrasound biomicroscopy in pigment dispersion syndrome. *Ophthalmology.* 1994 Feb; 101(2):332-9.
17. Jin JC, Anderson DR. The effect of iridotomy on iris contour. *Am J Ophthalmol.* 1990 Sep 15; 110(3):260-3.
18. Pavlin CJ, Foster FS. *Ultrasound biomicroscopy of the eye.* New York: Springer; 1995.



Elite School of Optometry- Sankara Nethralaya

(Unit of Medical Research Foundation)

Pediatric Optometry Fellowship

Pediatric Optometric Fellowship – Six months Programme

Prerequisites:

- **B S degree in optometry or its equivalent degree in optometry (or)**
- **Diploma in Optometry/ Refraction with minimum 2 years of clinical experience**
- **Competitive Mark in the course previously done**

For details about the courses, please visit www.sankaranethralaya.org/op_Elite.htm
or

Write to The Program Coordinator, Pediatric Optometry Fellowship,
Elite School of Optometry, No.8, G S T Road, St. Thomas Mount, Chennai 600016
Email : elite@snmail.org, Phone: 91-44-22349269/ 22346023

PLEASE LOOK US UP ON THE WEB at
<http://www.sankaranethralaya.org>

Please forward your correct address with your E-mail address if any,
to insight@snmail.org to enable us to update our address data base.

INSIGHT & EYELIGHTS are now available on line at
<http://www.sankaranethralaya.org/publication.htm>

Muscle Puzzle

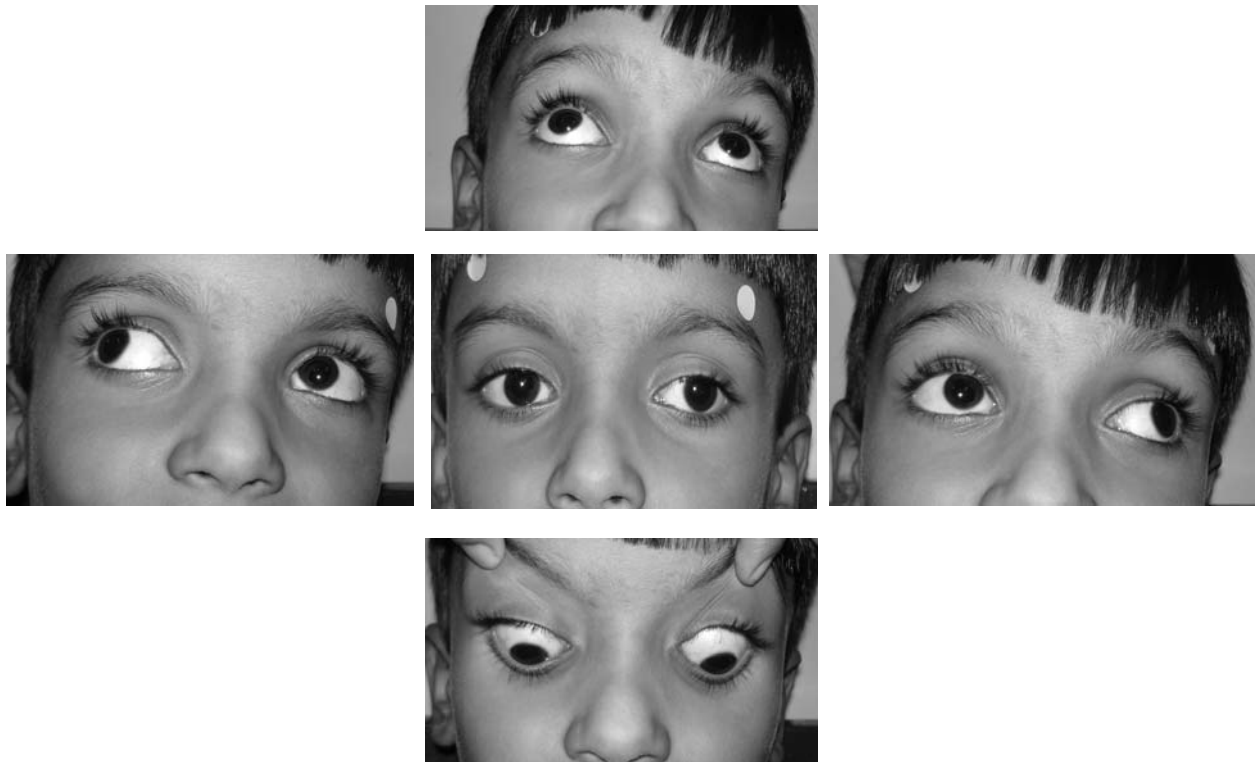
Muralikrishna V, SN_ORBIS POLTC

Nine year old child with parents noticing outward deviation of eyes, on and off during the day, for the past 5 years. Squinting noted mainly for distance.

On examination, visual acuity by Snellen's chart was 6/6; N6 in both eyes. Anterior segment and dilated posterior segment exam was within normal limits in both eyes. Cycloplegic refraction did not reveal any significant refractive error.

The head posture, ocular alignment and motility were as seen in these photographs.

WHAT IS YOUR DIAGNOSIS AND PLAN OF MANAGEMENT?



Muscle Puzzle

Patient has left exotropia for distance in primary position. He manifests right hypertropia on left gaze and left hypertropia on right gaze with increase in the exotropia in upgaze compared to the down gaze. This indicates V-pattern Exotropia. The pattern is due to bilateral inferior oblique overaction, which could be primary (idiopathic, most common cause) or secondary to superior oblique palsy. The V-pattern is described as increasing divergence in up gaze versus down gaze by 15 PD or more.

V-pattern is usually due to an oblique muscle overaction or palsy. Other less common causes are - nerve misdirection, altered muscle course and its pulley systems and a rotated orbit associated with craniofacial abnormalities.

Elevation in adduction can be due to other causes that needs be differentiated.

- 1) Dissociated vertical deviation (DVD): Test by occluding the eye in adduction and abduction; DVD will manifest elevation of eye in both abduction and adduction, while IO overaction will manifest only in adduction. Often DVD co-exists with IO overaction making differentiation difficult.
- 2) Tight lateral rectus muscle: Tight lateral rectus acts as a leash pulling the eye up on slight elevation in adduction causing pseudo IO overaction.
- 3) Aberrant regeneration of inferior oblique and superior rectus muscles.

In this patient the Inferior Oblique muscle overaction has resulted in more abducting force in upgaze (secondary action of inferior oblique) resulting in more divergence in upgaze.

This patient is best managed surgically to restore fusion as he is manifesting squint in primary position. Surgical options vary depending on the associated features.

V-pattern exotropia with bilateral inferior oblique overaction is treated by bilateral lateral recti recessions or uniocular recession of lateral rectus with resection of ipsilateral medial rectus. The IO is weakened to counteract its overaction. Various techniques for IO weakening depending on amount of IO overaction and surgeon preference, they are Myectomy, Recession, Anteriorization, 'Z' myotomy and Myotomy.

If there is no inferior oblique overaction and in cases where an abnormal oblique course of the lateral recti is found on table (as in cranio-facial anomalies), bilateral lateral recti recession with upshift of tendons is recommended.



The e-learning portal of Sankara Nethralaya

A unique distance learning resource catering to the educational needs of various eye care professionals such as ophthalmologists, optometrists*, ophthalmic nursing* etc.

Structured courses, Grand Rounds with case discussions

We invite you to visit us, participate and give us your valuable feedback

*Educational Material for optometrists and ophthalmic nursing
still in the process of being built up.

How you can Donate in the United States

Sankara Nethralaya OM Trust Inc.
9710 Traville Gateway Drive, No. 392
Rockville, MD 20850, Ph: (877) 393-7666
Tax Exempt ID No. 52-1611548

- **United Way** - Mention the above information on your authorization form. Local chapters will remit your contributions to SN OM Trust Inc.
- **Combined Federal Campaign** - If you a US federal employee, make your donations to Sankara Nethralaya OM Trust Inc. CFC No. 68803. We are listed under international independent agencies.
- **Employer Matching Program** - Check with your Human Resources Office if they participate in employer gift matching program. Number of US employers match dollar for dollar for employees' contributions. You may able to double your contributions to SN OM Trust.
- **Credit Card Donations** - Go to our website www.omtrust.org, click on 'Donate Now' button and follow the self explanatory instructions.
- **Draft from Checking Account** - Download Direct debit authorization form from the home page of our web site www.omtrust.org. Complete the form and forward your authorization with a 'void check' to the above address. We will draft the funds on 15th of every month. You can stop your authorization any time by a simple notification to us.
- **Appreciated Stocks** You may donate appreciated stocks to SN OM Trust Inc and avail a tax deduction. For additional information, please contact the Trust at the aforementioned phone number.
- **Payroll Deductions** - Please check with your HR office if they are programmed to withhold from payroll and remit to non profit organization. Number of organizations provide this as a public service.
- **Contributions by check** - Simply make your check payable to SN OM Trust Inc. and mail to the above address.

For additional information, contact –

K.G. Venkataraman kvenkatram@aol.com, S. Kannappansam kannappan@gmail.com
Shankar Iyer sai@omtrust.org S.V. Acharya acharya@omtrust.org



9th Annual Meeting
of the

Uveitis Society Of India



9th USI Meet

December 4th, 5th & 6th 2009
at Sankara Nethralaya,
Chennai, India

Confirmed International Faculty

- Dr. Narsing Rao, USA
- Dr. Dean Elliot, USA
- Dr. John Kempen, USA
- Dr. Russel Read, USA
- Dr. Manfred Ziehrut, Germany
- Dr. S P Chee, Singapore

USI & Host Faculty

Important Dates

Conference Dates: 4th, 5th and 6th December 2009

Basic outline of the Programme

4th December 2009 :

- Morning Session : Indian Uveitis Patient Interest association meet
- Afternoon Session : Basics of uveitis: Instruction courses & Symposia

5th and 6th December 2009 :

- Didactic lectures by experts in the field
- Free papers and challenging case presentations with interactive sessions followed by discussion by panel members

5th December, 2009 : Uveitis Society of India General Body Meeting Followed by Banquet

Registration Form

Name : Dr/Mr/Ms:

Contact Address:

.....

.....

E-mail ID:

Mobile No:

Please find enclosed my DD No

Dated: for Rs. towards registration.

DD should be drawn in favour of : Medical Research Foundation, Chennai, and mailed to the organising secretary.

Registration fee

Important Dates

I.Early Bird Registration Begins **Feb 1, 2009**

II.Early Bird Registration Ends **Sep 30, 2009**

Early Bird payment: Rs. 1500

Late/Spot registration: Rs. 2000

Organising Secretary

Dr Jyotirmay Biswas
Director and Head
Department of Uveitis and Ocular pathology
Medical and Vision Research Foundation
Sankara Nethralaya, Chennai
Ph - +91-44-28271616, Mobile : 9841428151
Email : drjb@snmail.org

Organising Team

- Dr. Jyotirmay Biswas
- Dr. Sudha K Ganesh
- Dr. Amala Elizabeth George
- Dr. Mamta Agarwal
- Dr. Sudharshan S
- Dr. Amitabh Kumar
- Dr. Suchitra Pradeep



www.usichennai2009.org

Introduction to Biostatistics

'Science' has the right to be written well!"

Classifying Variables by type

M. Thennarasu¹, Dr. V. V. Jaichandran², Dr. Vishnu Vahan Prasan¹, Dr. R. R. Sudhir¹

Introduction:

Good research deserves to be presented well, and good presentation is as much a part of the research as the collection and analysis of the data. Critical reviewers of the biomedical literature have consistently found that more than half of the published articles that used statistical methods contained unacceptable errors^{1,2}. These errors mainly concern the sample size, statistical power, agreement between aim and conclusion, distribution of data, as well as description of location and variability of data¹. The common errors can be avoided by understanding the basic statistical concepts. With this brief introduction we would be discussing the various tools of statistics and its application in research study. In this issue we would look into the concepts of variable.

Variable

In statistics, variable refers to any measurable (quantity) characteristic or attributes (quality) which varies from individual to individual. For eg. measurement of blood pressure, age, weight, IOP and attributes such as blood group, stage of diseases, diabetes etc.

Importance of variables:

1. To identify the appropriate statistical tools needed for a study.
2. To interpret the data that has been collected.

Types of Variables:

1. Quantitative variable
2. Qualitative variable

Quantitative variable:

Any data that can be measured (continuous) or counted (discrete) numerically for which meaningful arithmetic calculations make sense.

Types of Quantitative variable

- Continuous data (Interval) : Data that are collected by measuring and are expressed on a continuous scale. For eg. Corneal diameter, thickness, IOP etc
- Discrete data (Ratio): Data that is countable and collected by counting. For eg. Number of right or left eyes operated, number of patients admitted on a day etc.

Qualitative variable:

Any data that can't be measured numerically, but that can be measured in non-numeric quality or characteristics. It is also called as categorical variable.

Types of Qualitative variable

- Nominal data: Attributes that have no numerical meaning and that has no order. In nominal data one cannot perform arithmetic calculations (\times , \div , $+$). For eg. gender, marital status, hair color etc.
- Ordinal data: Attributes can be ordered, but distances between attributes do not have any numerical meaning. For eg. Pain (mild, moderate and severe), Grading of peribulbar block from 0-5 etc.

Special types of Variable:

Independent (Explanatory) variable: A variable whose values are independent of changes in the values of other variables.

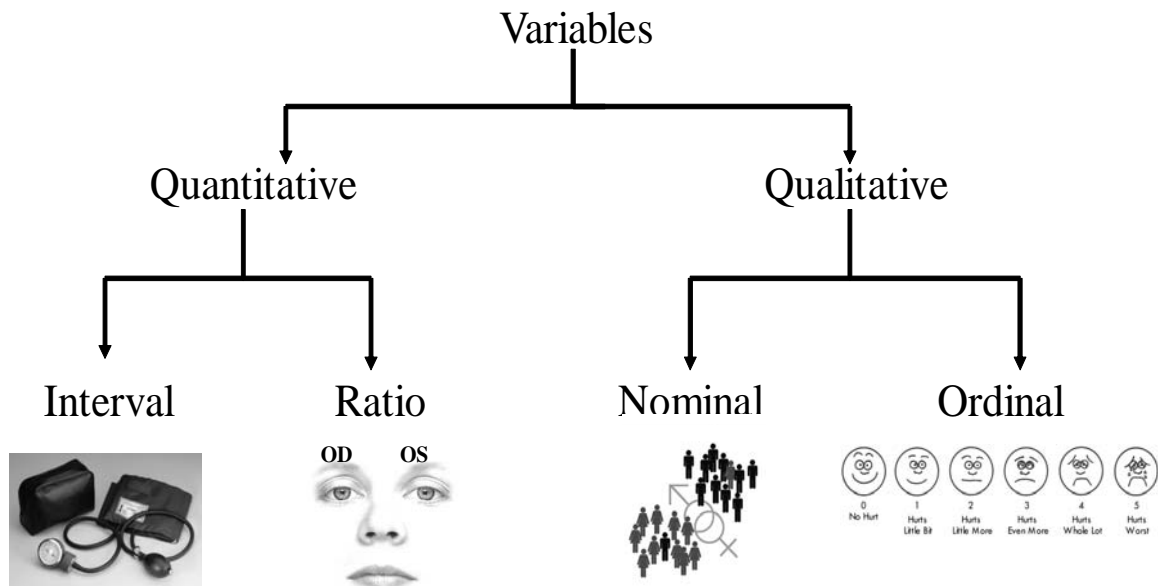
Dependent (Response) variable: Variables that are those observed to change in response to the independent variables. For example,

1. If in a study, males are compared with females regarding their white cell count (WCC), gender could be called independent variable and WCC the dependent variable.
2. In a study to evaluate the effect of anaesthetic drugs on IOP, then IOP will be dependent variable and anaesthetic drugs used will be independent variable.

Binary (Dichotomous) variable: Dichotomous variable is the one that has only two values or outcome. For eg. True/False, Yes/No etc.

Thus, statistical tests need not remain a mystery since level of measurement is the deciding factor for selecting which tests are appropriate for answering the research questions or testing the hypothesis. In the next issue we will be discussing in detail statistical tools that are required for a study using the above different type of variables.

Types of Variable



1. Department of Preventive ophthalmology (Biostatistics & Epidemiology)
2. Department of Anaesthesia

References:

1. Zaugg CE. Common biostatistical errors in clinical studies; *Schweiz Rundsch Med Prax.* 2003 Feb 5; 92(6): 218-24.
2. Glantz SA. Biostatistics: how to detect, correct and prevent errors in the medical literature. *Circulation* 1980; 61: 1-7.

3. Altman DG. Statistics in medical journals: Some recent trends. *Stat Med* 2000; 19:3275-89
4. Altman DG, Bland JM. Improving doctors' understanding of statistics. *JR Stat Soc ser A* 1991; 154(2): 223-67