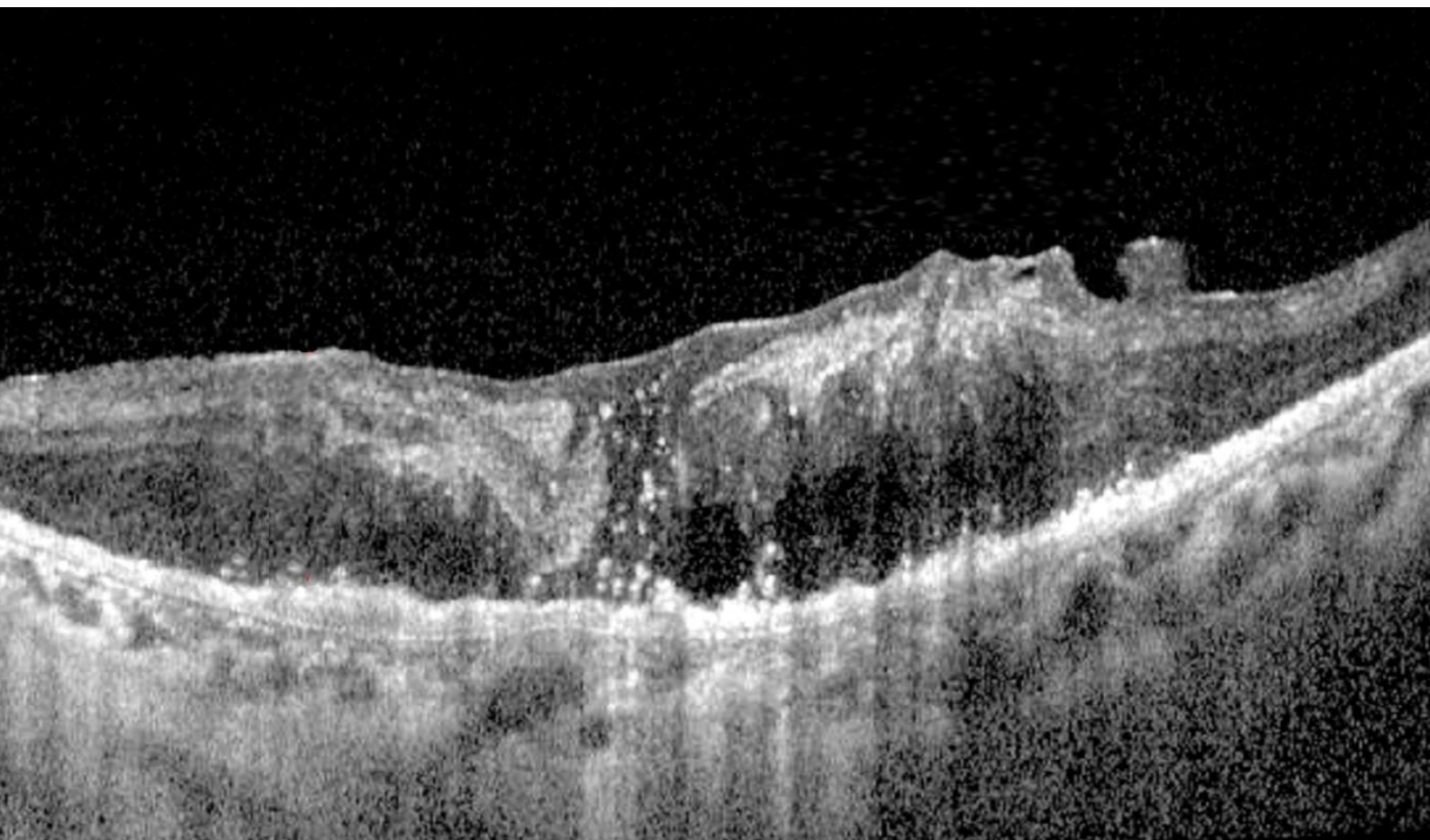


January 2018 Volume 36 No 1

# insight

Scientific Journal of

**MEDICAL & VISION RESEARCH FOUNDATIONS**





# Insight

Scientific Journal of Medical & Vision Research Foundations

Year: 2018

Issue: Vol. 36 | No. 1 | January 2018 | Pages 1 -24

Typeset by: Apon Sen, Sankara Nethralaya, Kolkata

Printed at: Ess Zed Enterprise, 4/1 Topsia First lane Kolkata 700 039

©Medical and Vision Research Foundations



## Sankara Nethralaya – The Temple of the Eye.

It was in 1976 when addressing a group of doctors, His Holiness Sri Jayendra Saraswathi, the Sankaracharya of the Kanchi Kamakoti Peetam spoke of the need to create a hospital with a missionary spirit. His words marked the beginning of a long journey to do God's own work. On the command of His Holiness, **Dr. Sengamedu Srinivasa Badrinath**, along with a group of philanthropists founded a charitable not-for-profit eye hospital.

Sankara Nethralaya today has grown into a super specialty institution for ophthalmic care and receives patients from all over the country and abroad. It has gained international excellence and is acclaimed for its quality care and compassion. The Sankara Nethralaya family today has over 1400 individuals with one vision – to propagate the Nethralaya philosophy; the place of our work is an Alaya and Work will be our worship, which we shall do with sincerity, dedication and utmost love with a missionary spirit.

## Contents

### Editorial Team

<b>Editorial:</b> From the editor's desk	<i>Md. Shahid Alam</i>	1
<b>Guest Editorial:</b> The science of dacryology – Need of the hour	<i>Mohammad Javed Ali</i>	2
<b>Original Article:</b> Comparative evaluation of scheimpflug imaging technique (PENTACAM) in analysing corneal topographic changes after phacoemulsification with rigid IOL implantation and small incision cataract surgery	<i>Deepika Kedia, Anand Agarwal, Karamjit Singh, Prempal Kaur and Atish Pradhan</i>	3
<b>Mini Review:</b> Contact lenses for keratoconus	<i>Manokamna Agarwal, Rajeswari Mahadevan, Asif Iqbal and N Radhika</i>	8
<b>Case Report:</b> Macular combined hamartoma of retina and retinal pigment epithelium (CHRRPE):A multimodal imaging perspective	<i>Kumar Saurabh, Rupak Roy and Samarth Mishra</i>	13
<b>Case Report:</b> Sino–orbital penetrating organic foreign bodies	<i>Kirthi Koka and Bipasha Mukherjee</i>	15
<b>Images in Ophthalmology:</b> Elsching's pearls	<i>Arshad Iqbal</i>	18
<b>Images in Ophthalmology:</b> Complete ocular coloboma: A rare occurrence	<i>Anushree Kumar</i>	19
<b>Teacher's Corner:</b> Teaching and presenting in the virtual space	<i>Meenakshi Swaminathan</i>	20
<b>Nutshell:</b> Microbial keratitis	<i>Raj Shekhar Paul and Aditi Johri</i>	21
<b>Crossword</b>	<i>Akruti Desai</i>	24
<b>Instructions to the Authors</b>		I - III
<b>Crossword- Answer</b>	<i>Akruti Desai</i>	

# Editorial Team

## **Chief Editor:**

Md. Shahid Alam

## **Assistant Editors:**

Jaya Prakash V

Sharanya Sarah Abraham

Sharada R

Anuradha M

## **Section Editors:**

Shweta S Agarwal

Kumar Saurabh

Akila Ramkumar

Eesh Nigam

Durga Priyadarshini S

Nisar Sonam Poonam

Arshee S Ahmad

Tamonash Basu

## **Advisory Board:**

Girish Shiva Rao

Ronnie Jacob George

Smita Vittal

Parthapratim Dutta Majumder



## From the editor's desk

Md. Shahid Alam<sup>1</sup>



Dear friends, colleagues, and seniors. I feel extremely honored to be considered as the next editor of our scientific journal Insight. Dr Parthopratin Dutta Majumdar, the previous editor had done immense hard work in bringing Insight to its present status. We are amongst the

very few educational institutes across the country to have our own institutional scientific journal. It reflects upon the scientific temperament and research aptitude of the institute. The journey of Insight has covered more than 30 years and we have been successful in bringing out the issues on a regular basis though with some difficulty. The greatest hurdle has been the scarce submission of articles. We need to be very proactive in this regard and come forward with great enthusiasm. It will help us in bringing up the issues with quality content on a regular basis. Because of the scarcity of articles I have decided that hence forth we will be publishing Insight bi annually. We can think of increasing the number of issues if the submission increases significantly. Our next aim is to get the journal indexed in a scientific library database. That too will require raising the bars and publishing as much of quality articles as possible at a regular interval without any break. We can also think of creating a submission system in future if things work out well. From now onwards we are also accepting articles from Sankara Nethralaya alumni and it is no more limited to consultants, post graduates and fellows presently employed with Sankara Nethralaya. I sincerely hope to receive whole hearted support from all of you in achieving great heights for our scientific journal. The next issue will be themed on ocular oncology. You are requested to kindly submit your articles for that. Enjoy reading your favorite journal till then.

1. Aditya Birla Sankara Nethralaya  
147, Mukundapur, E M Bypass,  
Kolkata 700099, India

drmsa@snmail.org

How to cite this article Alam M S. From the editor's desk, Sci J Med & Vis Res Foun 2018; 36 : 1.

## The science of dacryology -Need of the hour

Prof. Mohammad Javed Ali



HEAD,  
Govindram Seksaria  
Institute of Dacryology  
(GSID),  
L. V. Prasad Eye Institute,  
Hyderabad, India

HONGLEONG PROFESSOR,  
University of Singapore.

GAST PROFESSOR,  
Friedrich Alexander  
University,  
Nuremberg, Germany

ADJUNCT ASSOCIATE  
PROFESSOR,  
University of Rochester,  
New York

ALEXANDER VON  
HUMBOLDT SCIENTIST,  
FAU University,  
Nuremberg, Germany

drjaved007@gmail.com  
javed@lvpei.org

Dacryology is a science that deals with the lacrimal system of the human body. The first mention of lacrimal system dates back to the Code of Hammurabi (2250 BC) which described an incision for the infected

lacrimal sac. Subsequently, the ancient Egyptian classic, Ebers Papyrus (1500 BC) details the measures to treat lacrimal sac infections. In spite of the issues being recognized so early on along with tremendous advancements over centuries, we yet do not have definitive answers for some of the very basic questions. For example; what is the root cause of any lacrimal duct obstruction? What pathways trigger an obstruction? Why do these disorders have a gender predilection? And on and on it can go!

The great, Sir Winston Churchill once said “No problem can withstand the assault of sustained thinking”. This is where I believe, we were, and we are collectively lacking. There is a need for lacrimal surgeons across the globe to join hands, collaborate on focused methodologies to deal with specific questions. Let’s exemplify it using primary acquired nasolacrimal duct obstructions (PANDO). To ascertain its etiopathogenesis, there is a need to divide the disorder to conquer it! One focused collaborative group can look at lacrimal drainage associated lymphoid tissue up to the molecular pathways, and so on multiple groups can take one issue to solve at a time (lectin mediated inflammation, genetic predispositions, hormonal receptors and their mediators, tear cytokine analysis).

In these contexts, there is a great need of raising and nurturing “Clinician-Scientists”, who are well trained in both the clinical Dacryology and the basic science techniques pertaining to it. This breed of so called “MD-PhD” goes a long way in contributing to translational medicine. They can not only very well understand the clinical problems, but also take

them to the laboratory themselves, collaborate and take the solutions back to the clinics. Dacryology is too serious a job to be left to one group alone!

There are multiple places across the globe where Dacryology is being increasingly given attention. I am glad that India is leading this initiative both in clinical and basic sciences. For example, the evolution of “Govindram Seksaria Institute of Dacryology at the L.V.Prasad Eye Institute would hopefully pave a way for global collaborations and raising, training and supporting a generation of focused “Clinicians- Scientists”, armed to take on the multiple challenges of lacrimal disorders. There is a need for Dacryologists globally to set audacious goals and strive hard to achieve them so that we can make difference to the present and the future!

Those are my principles, and if you don’t like them.....well, I have others. (Groucho Marx)

# Comparative evaluation of scheinplug imaging technique (PENTACAM) in analysing corneal topographic changes after phacoemulsification with rigid IOL implantation and small incision cataract surgery

Deepika Kedia<sup>1</sup>, Anand Agarwal<sup>2</sup>, Karamjit Singh<sup>2</sup>, Premal Kaur<sup>2</sup> & Atish Pradhan<sup>3</sup>

1. Purnima Nethralaya,  
Jamshedpur

2. Government Medical College,  
Amritsar

3. LVPEI, Bhuwaneshwar

Author for Correspondence:

## Deepika Khedia

Purnima Nethralaya, Jamshedpur  
Former Fellow General  
Ophthalmology,  
Aditya Birla Sankara Nethralaya,  
Kolkata  
dr.khedia.11@gmail.com

## Abstract

**Purpose:** To compare changes in surgically induced astigmatism (SIA), corneal curvature, corneal thickness and elevation after Phacoemulsification surgery with rigid IOL implantation and Small Incision Cataract Surgery (SICS).

**Methods:** This prospective, comparative, randomized study was conducted from December 2014 to December 2015 which included 100 eyes with age-related cataracts. Both the groups had 50 patients each. Eyes in group 1 underwent phacoemulsification with temporal incision, whereas eyes in group 2 underwent manual SICS with a superior tunnel. Pentacam examination was performed in 100 eyes to evaluate anterior and posterior keratometry, elevation, astigmatism and corneal thickness. Postoperative best corrected visual acuity, corneal astigmatism and SIA were calculated on the 1, 3, 6 and 12 weeks. Continuous variables between groups were compared by the Student t test.

**Results:** Mean post-operative SIA in Group 1 and in Group 2 was  $1.58 \pm 0.66$  and  $1.70 \pm 0.84$  D ( $p$ -value = 0.4008) at 6 weeks. At 12 weeks follow up mean SIA in Group 1 was  $1.36 \pm 0.53$  D and in Group 2 it was  $2.03 \pm 0.71$  D ( $p$ -value = 0.0001). There was a statistically significant difference in the BCVA between the two groups at 6 weeks ( $p = 0.019$ ). Both phacoemulsification and SICS lead to an increase in corneal thickness postoperatively at 1 week and 3 weeks which came to the original value by 6 weeks. There was no statistically significant difference in the anterior elevation in two groups but change in posterior elevation was statistically significant at 6 weeks and 3 months, respectively ( $p=0.002$ ).

**Conclusion:** Phacoemulsification surgery produces less SIA, less corneal topographic changes and better visual outcomes than SICS.

**Keyword:** Corneal topography, corneal astigmatism, phacoemulsification, corneal thickness.

## Introduction:

Cataract is a condition in which opacification appears in otherwise transparent lens and this opacification makes the person visually handicapped. Cataract is the commonest cause of preventable and curable blindness.<sup>[1]</sup> It is responsible for 47.8% To 51% of world blindness.<sup>[2-3]</sup> Corneal astigmatism plays an important role in recovery of visual function after cataract surgery. Astigmatism of 1 to 3 diopters has been reported in 15% to 29% of eyes with cataracts.<sup>[4]</sup> Cataract surgery has evolved from couching to phacoemulsification.<sup>[5]</sup> The refractive changes are attributed to the diameter of incision, location and shape of corneal incision.<sup>[6]</sup> Reduction of corneal incision size from 3 mm to less than 2 mm has resulted in a reduction of surgically induced astigmatism (SIA) and corneal aberrations.<sup>[7-9]</sup>

Recently, temporal and superotemporal (oblique) approaches have become more popular due to better exposure of the surgical field and a lower degree of SIA.<sup>[10-17]</sup> Options for intraoperative management of astigmatism include toric intraocular lens, limbal relaxing incision, two-stage procedure with excimer laser ablation and placement of surgical wound along steeper axis of astigmatism.<sup>[18-20]</sup> Every wound in cornea makes some structural, morphological and curvatural changes after healing and these changes depend upon the type, length and sharpness of the incision in the cornea.

Corneal surface topography plays a critical role in the performance of visual system, accounting for two-third of total refractive power of eye. Corneal topography also called corneal mapping, provides both qualitative and quantitative evaluation of corneal curvature. Topographic patterns of cornea of both eyes show mirror image symmetry. Various methods of corneal topography are Placido disc, Confocal microscope, Orbscan, Optical coherence topography, Ultrasound biomicroscopy and Pentacam.<sup>[21]</sup> Corneal topographic changes described after SICS and phacoemulsification include corneal steepening secondary to compression of tissue at the wound site, whereas corneal flattening occurs as a result of wound gap and irregular astigmatism.

Presently, only a few studies have compared the effect of incision on posterior corneal astigmatism and elevation changes. The present study is a step towards better differential understanding of corneal topographic change using Scheimplug imaging after small incision cataract surgery and phacoemulsification.

### Materials and Methods:

This prospective, comparative, randomized study was conducted from 1<sup>st</sup> December 2015 to 31<sup>st</sup> December 2016. Institutional review board approval and ethical clearance was obtained and the study adhered to the tenets of Declaration of Helsinki.

100 eyes with cataract (LOCS III: grade III to V)<sup>[22]</sup> [LOCS= Lens opacities classification system III] were enrolled in a prospective randomized study to have phacoemulsification with temporal, and SICS with superior approach. Sample size was calculated by SPSS software.

100 patients were divided into two groups. Both the groups had 50 patients each. Eyes in group 1 underwent phacoemulsification with temporal incision, whereas eyes in group 2 underwent manual SICS with a superior tunnel. Informed consent was obtained from all the participants.

Exclusion criteria were significant corneal opacity, previous intraocular surgeries, previous corneal trauma, glaucoma, uveitis, Fuch's endothelial dystrophy, irregular astigmatism, active blepharitis, maculopathy and retinopathy.

Preoperatively a complete ophthalmic evaluation was performed and corneal astigmatism was assessed by corneal topography. Intraocular Lens (IOL) power was calculated with contact A-scan biometry using SRK II formula. The patients were randomized to receive phacoemulsification and SICS using random number tables.

Phacoemulsification was performed under peribulbar anaesthesia. A 3.0 mm clear corneal incision was made in the temporal quadrant. A capsulorrhexis approximately 5.0 mm in diameter was created and cortical cleaving hydro-dissection was performed. The nucleus was emulsified using the stop-and-chop technique. After irrigation and aspiration of the cortex a single piece optic size 5.25 mm with 12.5 mm overall diameter non-foldable polymethylmethacrylate intraocular lenses was implanted in the bag after enlarging the incision with 5.1 mm keratome.

Small incision cataract surgery was done under peribulbar anaesthesia. A 6 mm scleral frown incision, 1.5 mm from the limbus was made. A funnel shaped sclerocorneal pocket incision was created with a crescent knife. One side-port was made 90 degrees apart of the scleral tunnel with a 15 degree angled knife. With a 3.2 keratome, the anterior chamber was entered 1.5 mm into the clear cornea and the internal incision was enlarged sideways to 8 mm. Similar intraocular lens was implanted into the capsular bag. No suture was placed once the anterior chamber was made watertight. All the surgeries were performed by the same surgeon. All the patients were followed on 1, 3, 6 and 12 weeks postoperatively.

The corneal SIA was studied by vector analysis using Holladay 10 step formula on the basis of results of topography.<sup>[23]</sup> Data were recorded and the results were statistically analyzed using Student's t-test. p value of < 0.05 was considered statistically significant.

### Results:

Out of 100 eyes, 50% were between 51-60 years and 65% were female. Almost 50% of the patients in phacoemulsification and SICS group were in the age group of 50 to 60 years. Mean preoperative anterior and posterior corneal astigmatism in the phacoemulsification group (Group 1) were  $0.67 \pm 0.62$  D and  $0.40 \pm 0.29$  D respectively while it was  $0.71 \pm 0.53$  D and  $0.34 \pm 0.23$  D, respectively in the SICS group (Group 2). There was no statistically significant difference in preoperative anterior and posterior corneal astigmatism between the two groups. The pre and post operative data have been summarized in Table 1 and 2.

The mean BCVA recorded at 6 weeks was  $0.27 \pm 0.18$  log MAR in phacoemulsification group and  $0.20 \pm 0.12$  log MAR in SICS group, it improved further on final follow up at 12 weeks ( $0.14 \pm 0.14$  log MAR and  $0.16 \pm 0.11$  log MAR in group 1 and 2 respectively). The difference was statistically significant at 6 weeks (p value= 0.019).

The mean SIA in group 1 was  $1.58 \pm 0.66$  D and in group 2 was  $1.70 \pm 0.84$  D at 6 weeks. On the final follow up mean SIA was  $1.36 \pm 0.53$  D and  $2.03 \pm 0.71$  D in group 1 and 2 respectively. The difference was statistically significant at 12 weeks (p value= 0.0001).

The cylindrical error prescribed at 12 weeks was between 0.5-1 D in 82% of the patients in Group 1 and between 1.01 to 2 D in 46% of the patients in Group 2. No patients in Group 1 were prescribed > 2 D of cylindrical correction whereas 6% of the patients were prescribed a cylinder of >2 D in the group 2.

Both phacoemulsification and SICS caused increase in peripheral corneal thickness postoperatively at 1 weeks and 3 weeks which came to preoperative value by 6 weeks and was maintained at 12 weeks.

The changes in anterior surface elevation was statistically not significant between the two groups while changes in posterior surface elevation was statistically significant. Details of anterior and posterior elevation changes have been summarized in Table 3 & 4. Corneal topography after phacoemulsification and SICS have been depicted in Figures 1 & 2 and 3&4, respectively.



	Group	Mean±SD	p-value
Preoperative	1	0.67±0.67	0.101
	2	0.71±0.53	
Postoperative week 1	1	2.30±1.22	0.293
	2	2.08±0.63	
Postoperative week 3	1	2.35±1.20	0.221
	2	2.09±0.61	
Postoperative week 6	1	2.31±1.07	0.191
	2	2.05±0.62	
Postoperative week 12	1	1.67±0.62	0.043
	2	2.06±0.71	

Table 1: Comparison of Anterior Surface Astigmatism in Group 1 and 2

	Group	Mean±SD	p-value
Preoperative	1	0.40±0.29	0.014
	2	0.34±0.23	
Postoperative week 1	1	1.04±0.49	0.0002
	2	0.72±0.30	
Postoperative week 3	1	1.05±0.50	0.0001
	2	0.67±0.26	
Postoperative week 6	1	1.01±0.43	0.0001
	2	0.69±0.29	
Postoperative week 12	1	0.98±0.42	0.0001
	2	0.68±0.30	

Table 2: Comparison of Posterior Surface Astigmatism in Group 1 and 2

	Group	Mean±SD	p-value
Preoperative	1	-2.46±12.29	0.133
	2	-2.60±0.691	
Postoperative week 1	1	1.44±16.69	0.649
	2	0.00±13.61	
Postoperative week 3	1	0.70±15.50	0.768
	2	-0.20±13.70	
Postoperative week 6	1	0.08±15.09	0.797
	2	-0.70±13.35	
Postoperative week 12	1	0.10±14.99	0.925
	2	-0.38±13.49	

Table 3: Comparison of Anterior Elevation on Pentacam in Group 1 and 2

	Group	Mean±SD	p-value
Preoperative	1	10.70±12.89	0.130
	2	-14.38±16.93	
Postoperative week 1	1	6.50±15.56	0.002
	2	-4.76±18.14	
Postoperative week 3	1	6.02±14.95	0.002
	2	-5.22±18.33	
Postoperative week 6	1	6.30±14.68	0.001
	2	-5.62±18.02	
Postoperative week 12	1	5.38±13.73	0.002
	2	-5.31±17.66	

Table 4: Comparison of Posterior Elevation on Pentacam in Group 1 and 2

Discussion

Modern day cataract surgery with IOL implantation has become one of the safest, most successful, simple, consistent and most frequently performed surgery. SICS is gaining popularity in developing countries as an inexpensive alternative to phacoemulsification. SICS and phacoemulsification have advantages like early visual rehabilitation, less of SIA, and no suture-related complications as compared with the conventional Extracapsular Cataract Extraction (ECCE). However studies analyzing direct head to head comparison between SICS and phacoemulsification have been relatively few and far.[24]

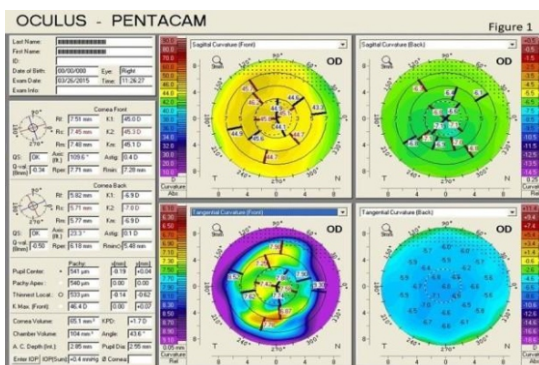


Figure 1. (Phacoemulsification) pentacam image showing sagittal curvature maps (front and back).

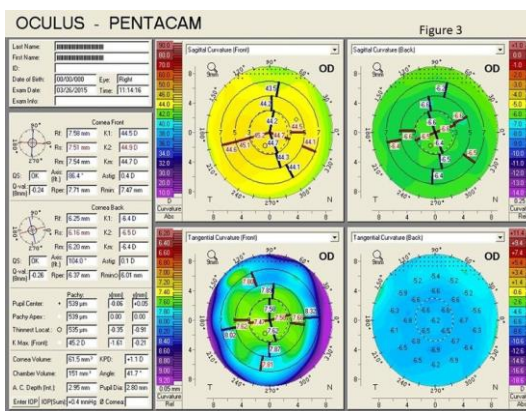


Figure 3. Pre operative (SICS) pentacam image showing sagittal curvature maps (front and back cornea) and tangential curvature map ( front and back cornea).

Postoperative astigmatism can be controlled and modified during phacoemulsification. Mild to moderate corneal astigmatism (<2.50 D) can be corrected or improved by modifying the parameters of the incision (length, distance from corneal center, corneal meridian; e.g, on-axis incision). The correction of higher astigmatism (>2.50 D) requires additional surgical procedures such as limbal relaxing incisions, arcuate keratotomies or the use of toric intraocular lenses. The quick visual restoration with phacoemulsification is attributed to little inflammation and less surgical induced astigmatism. High SIA is an important cause of poor uncorrected visual acuity and visual morbidity after cataract surgery.[25-26]

Our results of SIA in SICS seems to be consistent with previous studies. Jauhari et al found that straight incision induced SIA of 1 D in 27% patients and between 1.25 to 2 D in 50% patients who underwent SICS on 4<sup>th</sup> week postoperatively.<sup>[27]</sup> Radwan et al studied SIA in 35 eyes of 24 patients who underwent SICS with superior incision. They recorded SIA in the range of  $2.1 \pm 0.9D$  (against the rule astigmatism) on the 4<sup>th</sup> postoperative day.<sup>[28]</sup> Kagnici et al studied 68 eyes of 65 patients undergoing phacoemulsification. They found that 2.8 mm superior limbal incision induces less SIA than 2.8mm clear corneal incision, although the difference was not statistically significant ( $p > 0.05$ ).<sup>[29]</sup>

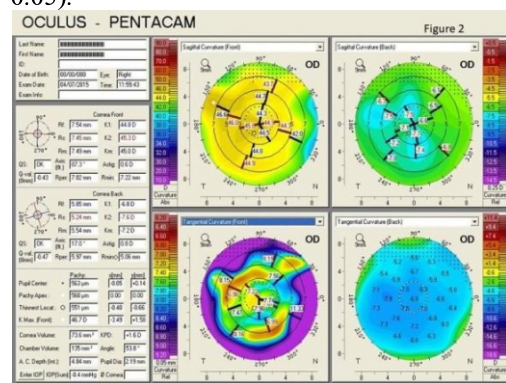


Figure 2. Post operative (Phacoemulsification) 1 week pentacam image showing sagittal curvature maps (front and back cornea) and tangential curvature map (front and back cornea).

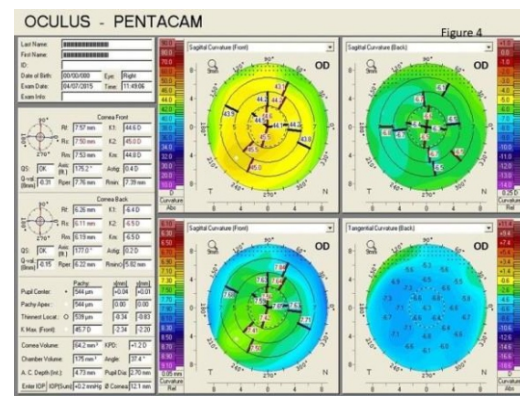


Figure 4. Post operative (SICS) pentacam image showing Sagittal curvature maps (front and back cornea) and Tangential curvature map (front and back cornea).

SIA in phacoemulsification group in our study was more than stated in literature. It can be attributed to the 6 mm non-foldable polymethylmethacrylate intraocular lenses were implanted because of non affordability issues with foldable intraocular lenses.

Furthermore, SIA in phacoemulsification was still less as compared to manual SICS in our study ( $p=0.0001$ ). Superior incision in SICS caused more astigmatism which might be attributed to the effect of upper eyelid on the incision site and this effect becomes negligible in temporal incision in phacoemulsification.

Hayashi et al analysed topographic changes after phacoemulsification and extra capsular cataract extraction. Topographic analysis clearly demonstrated that smaller wound in phacoemulsification surgery produced less corneal steepening and stabilized more rapidly than a larger wound in ECCE.<sup>[30]</sup>

The mean SIA in Group 1 at 6 weeks was found to be  $1.58 \pm 0.66 D$ , while it was  $1.70 \pm 0.84 D$  ( $p = 0.4008$ ) in Group 2. At 12 weeks of follow up the mean SIA in Group 1 improved to  $1.36 \pm 0.53 D$ , while it worsened in Group 2 to  $2.03 \pm 0.71 D$  ( $p = 0.0001$ ). These findings indicate that SIA stabilizes earlier in temporal approach phacoemulsification when compared with superior approach SICS. The difference in BCVA in both the groups at 12 weeks was not statistically significant. Both SICS and phacoemulsification lead to increase in corneal thickness postoperatively at 1 week and 3 weeks which came to preoperative value by 6 weeks.

There were significant changes in posterior surface elevation in both the groups at 6 and 12 weeks. Further studies are required to look into posterior elevation changes and their impact on postoperative refractive outcomes in both phacoemulsification and SICS.

The major limitations of our study were its short follow-up duration and the small sample size. Despite these limitations, we believe that the strengths of this study, which include its prospective nature and the examination of a homogenous population.

**Conclusion**

Phacoemulsification induces early healing and stability of wound and causes less corneal topographic changes than SICS. Thus, phacoemulsification is recommended for rapid visual rehabilitation of cataract patients. Further studies in cataract surgery are advisable for better understanding the effect of topographic changes on final visual outcome after surgery.

**Financial disclosure :**

All the authors have no financial interest to disclose.

**Conflict of interest:**

The authors have no financial or proprietary interest in the materials presented herein.

**References:**

1. Pascolini D, Mariotti SP. Global estimates of visual impairment:2010. Br J Ophthalmol.2012; 96:614–18.
2. Murthy G, John N, Shamanna BR, Pant HB. Elimination of avoidable blindness due to cataract: where do we prioritize and how should we monitor this decade? Indian J Ophthalmol.2012; 60; 438–45.
3. Li EY, Liu Y, Zhan X. Prevalence of blindness and outcomes of cataract surgery in Hainan Province in South China. Ophthalmology. 2013;120;2176–83.
4. Hoffer KJ. Biometry of 7,500 cataractous eyes. Am J Ophthalmol.1980;90:360-68.

5. West S. Epidemiology of Cataract: Accomplishments over 25 yrs and Future Directions. *Ophthalmic Epidemiol.* 2007;14; 173-78.
6. Mohammad-Rabei H, Mohammad-Rabei E, Espandar. Three methods for correction of astigmatism during phacoemulsification. *J Ophthalmic Vis Res.* 2016;11;162-67.
7. El Kady B, Alio J, Ortiz D, Montalban R. Corneal aberrations after microincision cataract surgery. *J Cataract Refract Surg.* 2008;34;40-45.
8. Yao K, Tang X, Ye P. Corneal astigmatism, higher order aberrations, and optical quality after cataract surgery: microincision versus small-incision. *J Cataract Refract Surg.* 2006;22; 1079-82.
9. Jiang Y, Le Q, Yang J, Lu Y. Changes in corneal astigmatism and high order aberrations after clear corneal tunnel phacoemulsification guided by corneal topography. *J Cataract Refract Surg.* 2006;22; 1083-88.
10. Rainer G, Menapace R, Vass C, Annen D, Findl O, Schmetterer K. Corneal shape changes after temporal and superolateral 3.0 mm clear corneal incisions. *J Cataract Refract Surg.* 1999;25; 1121-26.
11. Holweger RR, Marefat B. Corneal changes after cataract surgery with 5.0 mm sutured and 3.5 mm sutureless clear corneal incisions. *J Cataract Refract Surg.* 1997;23;342-46.
12. Olsen T, Dam-Johnson M, Bek T, Hjortdal Jo. Corneal vs scleral tunnel incision in cataract surgery; a randomized study. *J Cataract Refract Surg.* 1997;23;337-41.
13. Long DA, Monica ML. A prospective evaluation of corneal curvature changes with 3.0 to 3.5 mm corneal tunnel phacoemulsification. *Ophthalmology.* 1996;103;226-32.
14. Beltrame G, Salvat ML, Chizzolini M, Druissi G. Corneal topographic changes induced by different oblique cataract incisions. *J Cataract Refract Surg.* 2001;27;720-27.
15. Ermis SS, Inan U, Ozturk F. Surgically induced astigmatism after superotemporal and superonasal clear corneal incisions in phacoemulsification. *J Cataract Refract Surg.* 2004;30;1316-19.
16. Simssek SX, Yasxar T, Demirok A, Cinal A, Yilmaz OF. Effect of superior and temporal clear corneal incisions on astigmatism after sutureless phacoemulsification. *J Cataract Refract Surg.* 1998;24;515-18.
17. Roman SJ, Auclin FX, Chong Sit D, Ullern MM. Surgically induced astigmatism with superior and temporal incisions in cases of with the rule preoperative astigmatism. *J Cataract Refract Surg.* 1998;24; 1636-41.
18. Astbury N. Converting from ECCE to SICS. *Community Eye Health.* 2009;22; 6-7.
19. Ayala MJ, Perez SJ, Artola A. Laser in situ keratomileusis to correct residual astigmatism after cataract surgery. *J Cataract Refract Surg.* 2001;17; 12-16.
20. Matsumoto T, Hara T, Chiba K, Chikuda M. Optimal incision sites to obtain an astigmatism free cornea after cataract surgery with a 3.2 mm sutureless incision. *J Cataract Refract Surg.* 2001;27; 1615-19.
21. Fine IH. The evolution of phacoemulsification. *Cataract Refract Surg Today.* 2007;1; 143-47.
22. Tan AC, Loon SC, Choi H, Thean L. Lens Opacities Classification System III: Cataract grading variability between junior and senior staff at a Singapore hospital. *J Cataract Refract Surg.* 2008;34; 1984-52.
23. Morlet N, Minassian D, Dart J. Astigmatism and the analysis of its surgical correction. *Br J Ophthalmol.* 2001;85;1127-38.
24. George R, Rupauliha P, Rajesh AV, Vahan PV, Praveen S. Comparison of endothelial cell loss and surgically induced astigmatism following conventional extracapsular cataract extraction, manual small incision surgery and phacoemulsification. *Ophthalmic Epidemiol.* 2005;12;293-97.
25. Prajna NV, Chandrakanth KS, Kim R. The Madurai intraocular lens study II: clinical outcomes. *Am J Ophthalmol.* 1998;125; 14-25.
26. Yorston D, Foster A, Wood M, Foster A. Does prospective monitoring improve cataract surgery outcomes in Africa? *Br J Ophthalmol.* 2002;86; 543-47.
27. Jauhari N, Chopra C, Chaurasia RK, Agarwal A. Comparison of surgically induced astigmatism in various incisions in manual small incision cataract surgery. *Int J Ophthalmol.* 2014;7;1001-04.
28. Radwan AA. Comparing surgical induced astigmatism through change of incision site in manual small incision cataract surgery. *J Clin Exp Ophthalmol.* 2011;2;161.
29. Kagnici DB, Kocaturk T, Cakmak H, Dundar SO. Surgically induced corneal astigmatism following cataract surgery. *Open J Ophthalmol.* 2015;5;47-53.
30. Hayashi K, Nakao F. Topographic analysis of early changes in corneal astigmatism after cataract surgery. *J Cataract Refract Surg.* 1993;19; 43-47.

How to cite this article Comparative evaluation of scheimpflug imaging technique (PENTACAM) in Analysing Corneal Topographic changes after phacoemulsification with rigid IOL implantation and small incision cataract Surgery, Kedia D, Agarwal A, Singh K, Kaur P, Pradhan A, *Sci J Med & Vis Res Foun* 2018; 36 : 3 -7



## Contact lenses for keratoconus

Manokamna Agarwal,<sup>1</sup> Rajeswari Mahadevan,<sup>2</sup> Asif Iqbal<sup>2</sup> & N Radhika<sup>1</sup>

Author for Correspondence:

1.  
Department of Cornea and  
Refractive Surgery,  
Medical Research Foundation,  
Sankara Nethralaya,  
Chennai, Tamilnadu – 600006  
India.

2.  
Contact lens Department,  
Medical Research Foundation,  
Sankara Nethralaya,  
Chennai, Tamilnadu – 600006  
India.

### Abstract:

Keratoconus is a progressive, often asymmetric, non-inflammatory, ectatic disease of cornea, which results in irregular astigmatism and higher-order aberration. The distortion of the anterior corneal curvature results in the reduction of visual acuity along with different symptoms like monocular diplopia, image ghosting, ocular irritation, itching and dry eye symptoms, in these patients. These changes occur due to irregular astigmatism. Irregular astigmatism in keratoconus can be dealt in various ways depending on the size, shape, and severity of the cone. Various options are available for non-surgical visual rehabilitation for such conditions ranging from the use of spectacles to different modality of lenses including soft lenses, hybrid lenses, rigid lenses, piggyback systems, corneo-scleral, mini-scleral, and scleral lenses. Spectacles and soft toric contact lens can provide acceptable vision in the early stage of the disease, as the disease progresses, the specialty contact lenses are becoming the mainstay for correction of vision. This article will provide comprehensive details on different contact lens modalities available for the optical management of keratoconus.

### Introduction:

As Ophthalmology in today's world is evolving surgically to manage irregular corneas, contact lenses have also evolved with time, giving equal or sometimes better results compared to surgical options. Irregular astigmatism in keratoconus can be dealt with in various ways depending on the size, shape and severity of cone.

### Spectacles

Mild to moderate cases of keratoconus and in small cylindrical refractive error caused by keratoconus (<3Diopter), spectacles can be considered as a feasible option, as it gives a fair improvement in visual acuity.

### Soft Toric Contact Lenses

With the advancement in manufacturing technology, several soft toric contact lens designs are available in the market to fit keratoconic corneas. These specially lathed quadrant specific curve design soft toric lenses can also be considered over spectacles as they not only improve the quantity of vision but also give a superior quality of vision. Moreover, high oxygen permeability and modulus of elasticity make them better suited for keratoconic corneas. For better performance, several custom-made aberration control soft contact lenses also have been manufactured which can reduce the symptoms like shadowing, ghosting of image and glare.

**Case Scenario-1:** Let's consider an example of a 21-years old male with bilateral moderate keratoconus who underwent collagen cross-linking in both eyes (Figure 1A and 1B). The pachymetry was 530 and 490 microns respectively in the right and left eye, with the refraction of -1.00 Dsph/-0.75 Dcyl x 10° in the right eye and -1.50 Dsph/-2.50 Dcyl x 130° in the left eye. The best-corrected vision was 6/6 in both eyes with spectacles, still, the patient felt well with the use of soft toric CLs (Table 1).

### Rigid Gas Permeable Contact Lenses

Moderate to severe cases of keratoconus where astigmatism is more than 3 Diopters, various rigid gas permeable contact lenses (RGP CLs) can be considered. RGP CLs create a tear layer in between the posterior surface of the lens and anterior surface of the irregular cornea, which neutralizes corneal astigmatism and improves the visual performance by reducing the higher-order aberrations. Options of different RGP CLs are conventional RGP CLs with a spherical or aspheric back surface, RGP with front surface toric, special design lenses like Rose-K family of lenses, corneo-scleral, mini-scleral (Rose-K XL, Mc Asfeer, Boston commercial) and scleral lenses (PROSE: Prosthetic Replacement of Ocular Surface Ecosystem lenses). The choice of lens is made according to the patient's comfort, affordability, corneal health, fitting parameters and best visual acuity attained.<sup>1</sup> As the diameter of the cone increases, so should the back optic zone diameter (BOZD), the base curve radius and the lens diameter should increase, resulting in a better match between the sag of the cone and sag of the back optic zone.<sup>2</sup>

On the basis of lens diameter, RGP CLs are classified as corneal (8.0-12.8mm), corneo-scleral (12.9-13.5mm), mini-scleral (15.0-18.0) and scleral (18.1-24) lenses. The Scleral lens Education Society (SLS) has described scleral lenses based on the resting zone area of the lens on the ocular surface, not on lens diameter (Table 2).<sup>3</sup>

### A. Rose-K Contact Lenses

Rose-K family of lenses is designed with complex computer-generated peripheral curves based on the data collected by Dr. Paul Rose. Rose-K lens is a special design corneal RGP lens, has a multi-curve structure with a small optic zone and was initially designed for keratoconus. Rose-K 1 has a spherical back surface and causes spherical aberrations. Rose-K 2 has an aspheric design, which thereby eliminates spherical aberrations. At present, varieties of Rose-K lenses include Rose-K 2 standard (with a diameter of 8.7mm), Rose-K 2 NC (with a diameter of < 8.5mm and specially designed for nipple cone of keratoconus). The working principle of this lens design is decreasing the optic zone diameter as the base curve becomes steeper.<sup>4</sup>



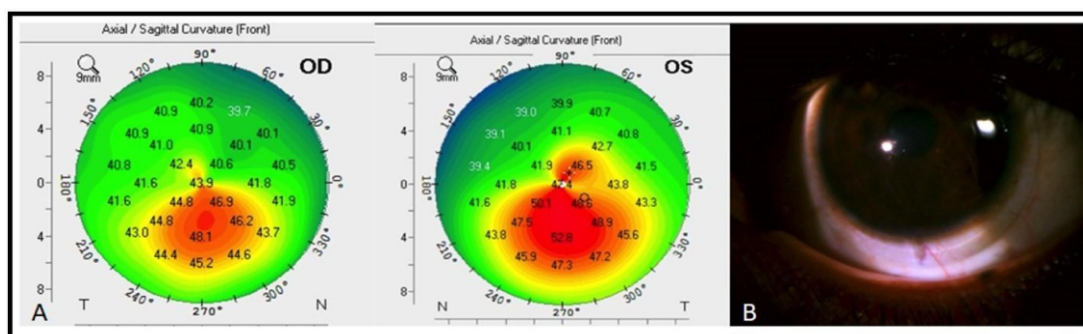


Figure 1A: Axial curvature map of both eyes showing moderate inferior steepening with steepest keratometry of 48.1 Diopters and 52.8 Diopters in right and left eye respectively.

Figure 1B: Soft toric contact lens fitting in keratoconic eye.

**Case scenario-2:** A 14-years old male, with advanced keratoconus, underwent collagen cross-linking in the right eye (Figure 2A and 2B). The refraction noted was 0.00 Dsph/ -5.00 Dcyl x150° in the right eye and 0.00 Dsph/ -3.00 Dcyl x40° in the left eye. The best spectacle-corrected vision was 6/9 and 6/12 in right and left eye respectively. With the Rose-K 2 lens, the vision was 6/6 in both the eyes. This prompts the use of special design RGP CLs like Rose-K2 over spectacles in such cases (Table 3).

#### B. Piggy-back Contact Lenses

Piggy-back CLs include two lenses on one eye. The RGP CL piggybacks on a soft CL. It is indicated in corneas where corneal RGP CL fitting is compromised and patient complaints of discomfort or intolerance with RGP CLs.<sup>5</sup> The soft lens is used for better comfort and a corneal RGP lens is used to provide good visual acuity.

#### C. Hybrid Contact Lenses

Hybrid lenses have a central rigid lens and a skirt made of soft contact lens. The soft skirt improves wearing comfort and the RGP part provides good vision. The available lenses are Soft perm and Synerg eye lenses. The advantage of the hybrid lens is that it allows significantly more oxygen to reach the cornea. These lenses are fitted with no or minimal apical touch in the central cornea. The disadvantage of the hybrid lens is that it needs to be frequently replaced (every 6 months) and are expensive.<sup>6</sup>

#### D. Corneo-scleral Contact Lenses

Corneo-scleral lenses have diameter ranges from 12.9 mm and 13.5 mm, lenses rest partly on the cornea and partly on the sclera. These lenses are fitted with slight apical clearance and alignment over the corneo-scleral junction with minimal limbal clearance.

**Case Scenario-3:** A male patient 29-year old, with moderate keratoconus (Figure 3A and 3B), had refraction of -3.75 Dsph/ -2.00x40° Dcyl in right eye and -4.00 Dsph/ -2.50x120° Dcyl in left eye. The best spectacle-corrected vision was 6/9 in both eyes. With the Rose-K 2 XL lens (Corneo-scleral CL), the vision was 6/6 in both eyes (Table 4).

#### E. Mini-scleral and Full-Scleral Contact Lenses

Mini-scleral lenses are the smaller versions of scleral lenses as discussed earlier, have diameters between 15.0mm to 18.0 mm, up to 6 mm larger than horizontal visible iris diameter (Figure 4A).<sup>7</sup> Full Scleral contact lenses are the larger version of scleral lenses, diameter ranges from 18.1 mm to 24 mm, rest entirely on the sclera and is more than 6 mm larger than horizontal visible iris diameter (Figure 4B).<sup>8</sup>

Fitting of mini-scleral and scleral lenses requires an understanding of the shape of the corneo-scleral junction and scleral topography. Fitting these lenses without the use of impression molding techniques is challenging, but the recent introduction of trial sets and optical coherence tomography (OCT) as means of visualizing the anterior segment of the eye has aided in the design and fitting of these lenses. These lenses are designed to align and rest on the scleral conjunctiva and to vault over the cornea (Figure 5), without touching the cone. The cornea is completely vaulted and almost perfect opposite corneal shape is created by tears pooling between the cornea and back surface of the lens creating an equal and opposite keratoconic surface ultimately restoring uniform optical lens and elimination of astigmatism, which results in less ghosting of images.<sup>7</sup>

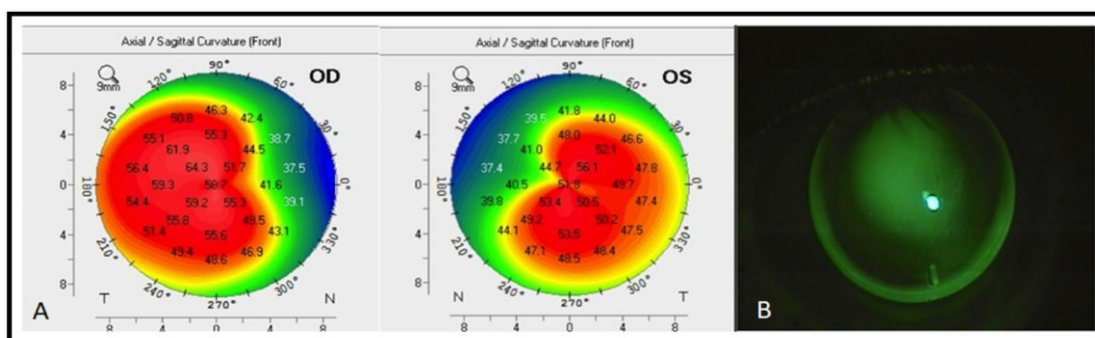


Figure 2A: Axial curvature map of both eyes showing advanced global steepening with steepest keratometry of 64.3 Diopters and 56.1 Diopters in right and left eye respectively.

Figure 2B: Rose K2 ideal fitting.

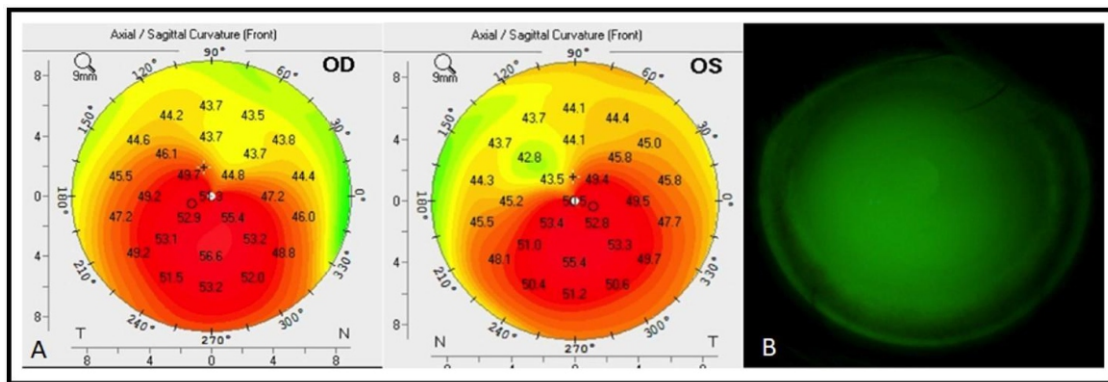


Figure 3A: Axial curvature map of both eyes showing almost global steepening with steepest keratometry of 56.6 Diopters and 55.4 Diopters in right and left eye respectively.  
 Figure 3B: Rose K2 XL ideal lens fitting.

In trapping tears beneath the lens, they have a therapeutic advantage for the dry eye patients in addition to masking very large areas of corneal irregularity. PROSE lenses are customized scleral devices for each patient's condition and unique eye shape. Scleral lenses are indicated when all other contact lenses fail to improve the vision, inability to get an optimal fit with RGP CLs, RGP CL intolerance, 3 and 9 o'clock staining of the cornea, vascularization with piggy-back CLs, advanced keratoconus, or scarring in the cornea.<sup>8</sup>

**Case Scenario-4:** Another example of bilateral advanced keratoconus with poor vision with spectacles was corrected to 6/6p with Boston commercial scleral lenses (Figure 6A, 6B and 6C). The details are enumerated in Table 5.

**Fitting principles for Rigid Gas Permeable Contact Lenses**

Proper fitting of corneo-scleral lens is very crucial in the visual rehabilitation of keratoconus patients. The central corneal (Back optic zone radius and diameter) zone, corneo-scleral zone and sclero-conjunctival zone need to be considered in corneo-scleral lens fitting and to be adjusted independently. Compare to corneal lenses these lenses improve the level of comfort and also the quality of vision.<sup>3</sup> Full and mini-scleral contact lenses should vault the cornea and limbal area while resting entirely on the bulbar conjunctiva and Tenon's capsule. For fitting of scleral lenses, the optic zone, transition zone and landing zone should be considered carefully. The optical zone is responsible for the optical effect, the transition zone is also known as limbal zone it creates the sagittal height of the lens and the landing zone is the area where the lens edge rests on scleral, also known as scleral zone.

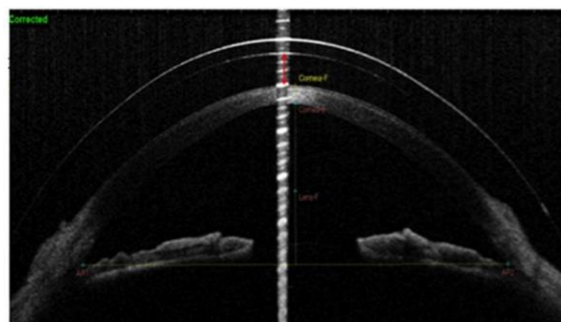


Figure 5: The AS-OCT Casia shows measurement of central corneal clearance or vault with a scleral contact lens.

To accurately estimate the amount of vaulting (clearance) underneath the posterior surface of a scleral lens, Ferris State University has designed a scale or an anterior segment Optical coherence tomography can be used.<sup>9</sup> In most scleral lens designs, the ideal amount of clearance is about 200-300 microns.

For choosing the correct lens design, a few general points should be considered.

- Case history
- Tear assessment
- Lids and lid margins assessment
- Keratometry
- Videokeratography
- Refraction
- Trial lens fitting
- Over-refraction
- Fluorescein pattern analysis

For an RGP CL fitting, three points should be considered.

1. Diameter based on the location of the cone, size and steepness.
2. Base curve
3. Power

After allowing for an adaptation period of 30 minutes for the lens on the eye after insertion, both the dynamic and static fit should be assessed.

**Dynamic fit:** Lens fit is considered to be acceptable when the lens is centered on the cornea adequately during post-blink movements, good stability in different gazes and the patient is comfortable during all these movements. The movement should be no more than 1mm with every blink and the lens should not cross the limbus.

**Static fit:** Assessed after instilling fluorescein in the eye with cobalt blue filter.

Because of three-point touch conventional fitting philosophy, bearing is on the irregular cornea, which results in corneal scar in long standing cases. Thus, feather touch or fitting towards apical pooling can be considered keeping in mind the progression of ectasia and non-compliance to periodic follow-up in patients.<sup>10</sup>

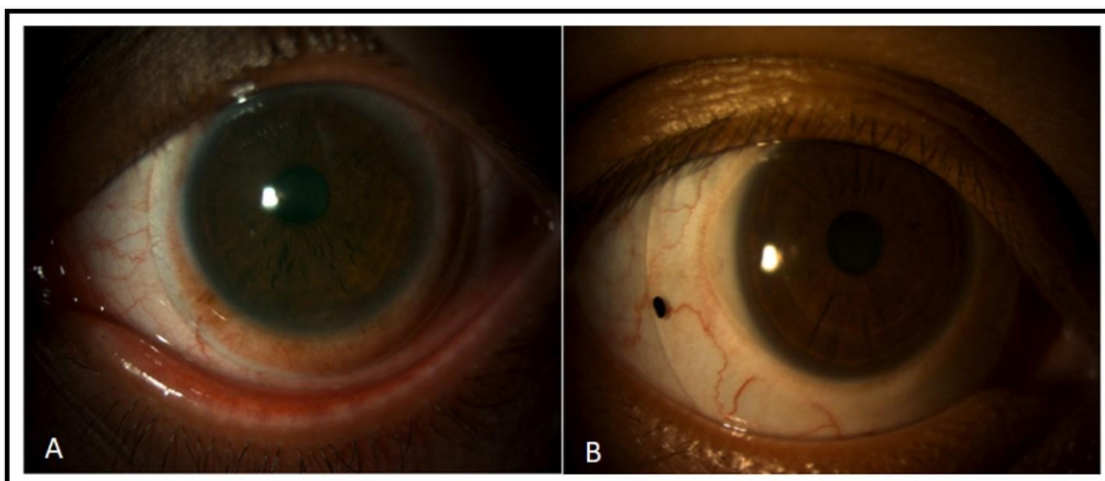


Figure 4A: Mini-scleral contact lens.

Figure 4B: Full-scleral contact lens.

### Complications of Rigid Gas Permeable Contact Lenses

Complications with RGP CLs include corneal staining (solution toxicity, 3 and 9 o'clock staining, patch or linear staining due to abrasion or foreign body), apical staining (whorl staining over the cone due to too small diameter and steep fit), dimple veiling (the impression made by air bubbles on the corneal surface), lens decentration, corneal indentation, microbial keratitis and infiltrates, air bubbles, lens adhesion, neovascularization, bulbar redness after lens removal and giant papillary conjunctivitis due to prolonged periods of lens wear. Hypoxia and edema can also occur.<sup>11</sup>

Extra caution should be taken in fitting the scleral lenses in patients with corneal grafts and aphakia. Patients with grafts may have low endothelial cell counts, which can make them more susceptible to adverse hypoxic sequelae.

The minimum recommended endothelial cell count for considering scleral lens fitting is 800 cells/mm<sup>2</sup>.

Increasing options for modifying the haptic portion of a scleral lens include the addition of toric peripheral curves, notching, and vaulting. This has allowed successful scleral lens fitting in patients with challenging conjunctival conditions. Although it may be acceptable for the haptic to lightly rest upon relatively benign lesions such as pingueculae. Pressure on a bleb may result in reducing the bleb's ability to lower IOP.

Some of the most challenging patients that scleral lens fitters face is those who are non-compliant, whether through negligence, lack of education, or some combination. Patient education is crucial in achieving long-lasting and healthy scleral lens wear. Even a well-fit lens can result in damaging sequelae if it is not worn and cared for appropriately. Indeed, poor scleral lens handling is one of the most common reasons for complications of scleral lens wear.<sup>12</sup>

### Frequently Asked Questions from Patients

Patients are usually apprehensive about the scleral lenses when they try it for the first time. They have various queries regarding the fitting and use of these lenses. Some most frequently asked questions from the patient's side are:

#### Can they wash lenses with soap and water?

No. Even tap water can harbor pathogens including *acanthamoeba*, which causes vision-threatening keratitis. It is recommended to rinse lenses with non-preserved sterile saline.

#### Can they use eye drops with lenses in?

If they require putting eye drops for conditions like glaucoma or allergy, it is recommended to instill at least 30 minutes before application of lenses or after lens removal. Ocular lubricants, which are compatible with lenses, can be used.

#### How long the application and removal plungers last for?

Plungers should be replaced yearly or sooner as needed.

#### How long the lenses last?

Depends on the ocular condition, progression, use of medication and handling. If cared properly, most of the lenses last for one year.

Answering patient's queries can help in better compliance and acceptance to use these lenses. The CL fitting expert should also ask the patient regarding their level of comfort, nature of work, and various other parameters before finalizing the type of lens.

### Frequently asked questions from Contact Lens Fitters

Before choosing the type of CL for an individual patient, the CL fitting experts also enquire about the following questions:

#### How often the patient wants to wear lenses?

RGP CLs must be worn consistently on a daily basis for them to be comfortable. On the other hand, soft CLs can be worn full-time or part-time.

#### Does the patient wear a bifocal spectacle?

There are options available for multifocal CLs, which can eliminate the need for reading glasses. But most people with presbyopia find mono-vision contacts more comfortable.

#### How affording the patient is?

There are various options in RGP CLs to choose from, ranging from Indian lenses to customized imported lenses.

#### Do they have eye allergies?

Eye allergy may affect the comfort and limit the ability to wear CLs for long hours. Before fitting of lenses, the status of the lids and ocular adnexa should also be assessed to decide on going ahead with the fitting of lenses.

Various other factors should also be considered like nature of the day-to-day activity (to advice on convenient wearing schedule and wearing period), water exposure, outdoor work, nature of job and sports activities.

### Pearls of Fitting from Experts

In irregular corneas we have to have a holistic approach for tailoring a lens or device considering all aspects like visual rehabilitation, corneal health, corneal and scleral shape, and affordability of the patient. If done so, fitting is highly successful and helps patients to have a drastic change in their quality of life. Each eye needs to be considered a unique case.

When explaining patients about choice of lenses, it's always better to give the array of options available and discuss their pros and cons, for the patient to choose the lens depending on lifestyle and affordability. Never leave a lens touching the cornea or the limbus or the sclera harder.

### References:

1. Atebara NH, Asbell PA, Azar DT. Contact lens, Chapter 5. Clinical optics, Basic and Clinical Science Course. San Francisco: American Academy of Ophthalmology 2009:167-200.
2. Edrington TB, Barr JT, Zadnik K, Davis LJ, Gundel RE, Libassi DP, McMAHON TT, Gordon MO. Standardized rigid contact lens fitting protocol for keratoconus. *Optom Vis Sci* 1996;73:369-375.
3. Michaud L, Lipson M, Kramer E, Walker M. The official guide to scleral lens terminology. *Cont Lens Anterior Eye* 2019;S1367-0484(19)30219-X.
4. Ozkurt YB, Sengor T, Kurma S, Evciman T, Acikgoz S, Haboglu M, Akı S. Rose K contact lens fitting for keratoconus. *Int Ophthalmol* 2008;28:395-398.
5. O'Donnell C, Maldonado-Codina C. A hyper-Dk piggyback contact lens system for keratoconus. *Eye Contact Lens* 2004;30:44-48.
6. Abdalla YF, Elsahn AF, Hammersmith KM, Cohen EJ. SynergEyes lenses for keratoconus. *Cornea*. 2010;29:5-8.
7. Rico-Del-Viejo L, Garcia-Montero M, Hernández-Verdejo JL, García-Lázaro S, Gómez-Sanz FJ, Lorente-Velázquez A. Nonsurgical procedures for keratoconus management. *J Ophthalmol*. 2017;2017:9707650
8. Rathi VM, Mandathara PS, Taneja M, Dumpati S, Sangwan VS. Scleral lens for keratoconus: technology update. *Clin Ophthalmol (Auckland, NZ)* 2015;9:2013.
9. Lotoczky J, Rosen C, Norman C. Scleral lens fit scales. Ferris State University website.ferris.edu/HTMLS/colleges/michopt/vision-research-institute/pdfsdocs/Scleral-lens-fit-scales\_v2.pdf.
10. Cardona G, Isern R. Topography-based RGP lens fitting in normal corneas: the relevance of eyelid and tear film attributes. *Eye Contact Lens* 2011;37:359-364.
11. Walker MK, Bergmanson JP, Miller WL, Marsack JD, Johnson LA. Complications and fitting challenges associated with scleral contact lenses: a review. *Cont Lens Anterior Eye* 2016;39:88-96.
12. Fadel D. The influence of limbal and scleral shape on scleral lens design. *Cont Lens Anterior Eye*. 2018;4:321-328.



# Macular combined hamartoma of retina and retinal pigment epithelium (CHRRPE): a multimodal imaging perspective

Kumar Saurabh<sup>1</sup>, Rupak Roy<sup>2</sup> and Samarth Mishra<sup>1</sup>

<sup>1</sup> Department of Vitreo Retina, Kamalnayan Bajaj Sankara Nethralaya, DJ16, Action Area 1D, Newtown, Kolkata, West Bengal, India-700156

<sup>2</sup> B B Eye foundation, Shree Tower, RAA-36, II, VIP road, Raghunathpur, Kolkata, West Bengal, 700059

Author for Correspondence:

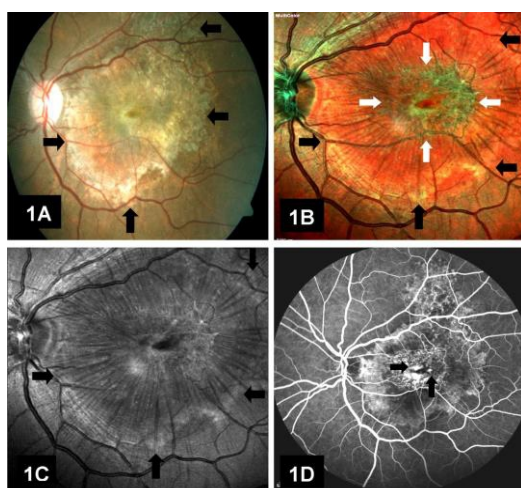
## Kumar Saurabh

Senior Consultant,  
Department of Vitreo Retina,  
Sankara Nethralaya,  
Kolkata  
Email: vrfellow@gmail.com

## Abstract

Combined hamartoma of the retina and retinal pigment epithelium (CHRRPE) is a rare, congenital and benign tumour. It is characterized by a combination of glial, vascular and pigmented components. CHRPE is typically unilateral, while bilateral presentation is more frequently seen in association with phakomatoses such as neurofibromatosis. It is typically seen as a greyish lesion with thickened preretinal tissue which contracts and displaces the surrounding retina and blood vessels. Our report highlights the multimodal imaging characteristics of macular CHRRPE.

**Keywords:** Combined Hamartoma of Retina and Retinal Pigment Epithelium, CHRRPE, Hamartoma, MultiColor imaging



1A: Irregular area of greyish discoloration due to ERM with displacement of the retinal vasculature. Black arrows show the extent of the retina involved

1B: MultiColor image showing the ERM as greenish area (White arrows) with a surrounding area of orange red hue circumferentially (Black arrows)

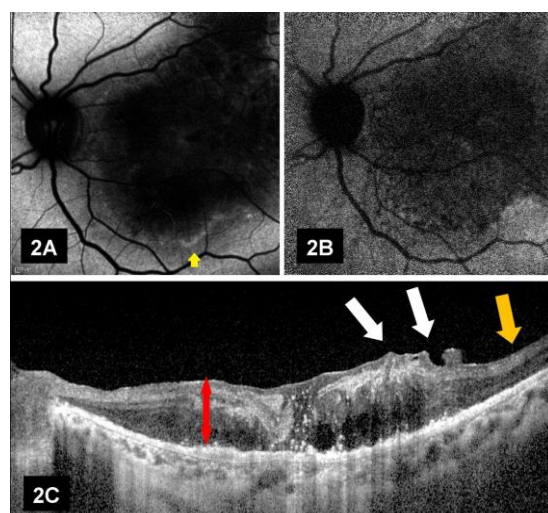
1C: Prominent, dark radiating ILM striae from the lesion in blue reflectance image with a clear delineation of the retina involved and extending beyond the lesion area seen on fundus photo (Black arrows)

1D: FFA showing central area multiple leaks (White arrows) with tissue staining in the late phase (Black arrows)

## Case:

A 41-year-old male presented with complaints of blurring of vision in the left eye for 10 years. Visual acuity at presentation was 6/6, N6 and counting finger 3 meter, N36 in the right and left eye, respectively. Anterior segment was within normal limits in both eyes. Fundus was normal in right eye. Color fundus photograph (CFP) of the left eye showed an area of grayish discoloration with retinal elevation due to epiretinal membrane (ERM) with significant displacement of the retinal vasculature. [Fig 1A] MultiColor composite image (MCI) showed the ERM as greenish lesion with a surrounding area of

orange hue circumferentially. [Fig 1B] Blue reflectance (BR) showed prominent, dark radiating retinal folds. [Fig 1C] On fluorescein angiogram, multiple point leaks were seen. Hypofluorescence of choroidal background in the arterial phase was noted. [Fig 1D] On blue autofluorescence, a large area of generalised hypoautofluorescence suggesting a probable loss of retinal pigment epithelium (RPE) with blocked fluorescence due to ERM was seen. [Fig 2A] Infrared autofluorescence showed an area of generalised hypoautofluorescence. [Fig 2B] Spectral domain optical coherence tomography (SDOCT) (Heidelberg engineering, Germany) demonstrated a disorganisation of outer and inner retinal layers. [Fig 2C]



2A: Blue autofluorescence showing a large area of generalised hypoautofluorescence suggesting a loss of RPE, with an inferior rim of hyperautofluorescence, probably due to RPE stress (yellow arrow).

2B: An area of generalised hypoautofluorescence with a stippled pattern seen in the infrared autofluorescence.

2C: Disorganisation of the outer and inner retinal layers with corrugations of the inner retinal layer caused due to ERM (White arrows) seen on SDOCT. Increased retinal thickness seen in the involved area (Double red arrow) with normal retina (Yellow arrow)

## Discussion:

CHRRPE was first described by Gass [1] as a hamartomatous malformation involving the retina, retinal pigment epithelium and overlying vitreoretinal interface. On SDOCT, CHRRPE is characterized by disruption of the inner neurosensory retina with variable degree of involvement of the external retina. Gupta et al have reported a filigree vascular pattern on optical coherence tomography in CHRRPE with a high density of these patterns in peripapillary lesions. [2] Herein, we have described the multimodal imaging characteristics of a typical macular CHRRPE lesion.

CFP showed a larger area of RPE involvement compared to MCI whereas the inner retinal involvement in the form of internal limiting membrane striae and ERM as such were rendered better on MCI. The blue channel of MCI, namely blue reflectance (BR) which is responsible for imaging the most superficial retinal layers showed the ERM and extent of internal limiting membrane striae better than CFP. The internal limiting membrane striae seen on MCI and BR extended well beyond the boundaries of the lesion noted on CFP. CFP and MCI complemented each other in delineating the deep and superficial boundaries of CHRPE respectively. Study of a series of cases of CHRPE will further substantiate our findings.

References:

1. Gass JD .An unusual hamartoma of the pigment epithelium and retina simulating choroidal melanoma and retinoblastoma. *Trans Am Ophthalmol Soc.* 1973; 71:171-183, 184-185.
2. Gupta, R., Pappuru, R. R., Fung, K. A. T., Lupidi, M., Kaliki, S., Yannuzzi, et al. (2019). Filigree vascular pattern in Combined Hamartoma of Retina and Retinal Pigment Epithelium on Optical Coherence TomographyAngiography. *Ophthalmology Retina.*

How to cite this article Sourabh K, Roy R, Mishra S. Macular combined hamartoma of retina and retinal pigment epithelium (CHRPE):A multimodal imaging perspective, *Sci J Med & Vis Res Foun* 2018;36:13–14.

## Sino-orbital penetrating organic foreign bodies

Kirthi Koka<sup>1</sup>, Bipasha Mukherjee<sup>1</sup>

<sup>1</sup> Orbit Oculoplasty  
Reconstructive and Aesthetic  
Services, Sankara Nethralaya,  
Medical Research Foundation,  
Chennai, Tamil Nadu.

Author for Correspondence:

### Kirthi Koka

Consultant Orbit Oculoplasty  
Reconstructive and Aesthetic  
Services,  
Sankara Nethralaya,  
Medical Research Foundation,  
Chennai, Tamil Nadu.  
E mail: drkka@snmail.org

### Abstract:

Penetrating injuries by foreign bodies (FB) are not uncommon. Organic FB are poorly tolerated and associated with sight and even life-threatening complications necessitating urgent removal. Clinical features are varied and depend on the mode of injury, size of the FB, and time of presentation. Imaging helps delineate the extent of penetration. We report 2 patients, one reported within hours of injury with decreased vision, a wooden FB protruding through the medial canthus, and extending through the ethmoid-sphenoid sinus up to the clivus. The other presented 3 months after an injury with epiphora without external signs of trauma. Imaging showed a FB breaching the lamina papyracea and extending up to the sphenoid sinus. A combined external approach with endoscopic trans-ethmoidal visualization was used to remove the FB with a gratifying post-operative outcome. Thus, a detailed history and high index of suspicion should be maintained, regardless of the interval between trauma and presentation. A multispecialty approach is imperative.

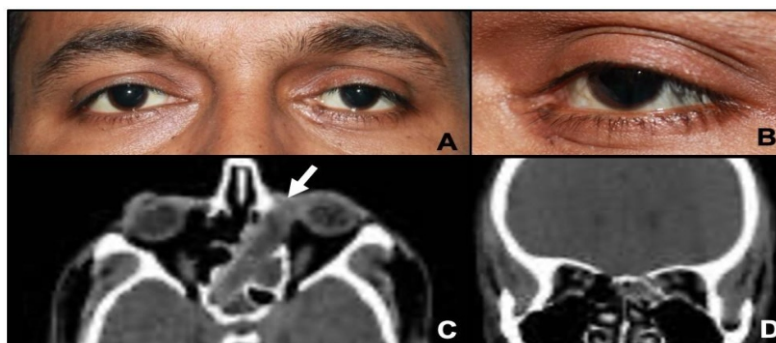
### Introduction:

Penetrating injuries by organic foreign bodies are not uncommon. However, their diagnosis is a challenge, both to the ophthalmologist and radiologist. The radiolucent nature of the organic material prevents easy localization by routine radiographic techniques. <sup>1</sup> In contrast to metallic foreign bodies, that remain quiescent for prolonged periods, organic foreign bodies are associated with sight and life-threatening complications such as orbital cellulitis, abscess, or chronic draining sinus, necessitating urgent removal. <sup>2,3</sup> We herein report two patients presenting with large penetrating organic foreign bodies lodged in the orbit with extension into the adjacent sinuses, who ultimately escaped unharmed.

### Case report: Case 1

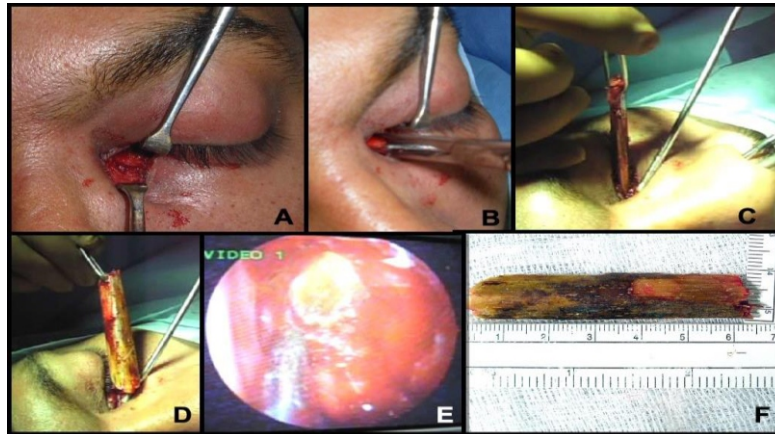
A 33-year-old male presented to our clinic with a history of having a head-on collision with the rear end of a sugarcane laden truck 3 months back on his way home from work. He was driving a 2-wheeler following the truck without any protective headgear, and sustained a lacerated wound below his left lower eyelid. He was rushed to a nearby hospital where his eyelid wound was sutured. He did not lose consciousness and there was no history of epistaxis. Soon after, the patient developed a sinus with mucopurulent discharge from the wound 25 days following the incident. His local physician ordered a Computerized Tomography (CT) scan of the brain and orbit which reported left sided orbital cellulitis with left ethmoid and right sphenoid sinusitis. He was treated conservatively with antibiotics and had resolution of symptoms.

He presented to us with the chief complaint of watering from the left eye 3 months following trauma. A thorough ophthalmic examination was done. We recorded a best-corrected visual acuity (BCVA) of 6/6, N6 in each eye. Extraocular movements were full and free. External examination showed tethering of his lower eyelid skin along the inferior orbital rim with a sinus but no active discharge. (Fig 1A & B) Regurgitation on pressure over the lacrimal sac (ROPLAS) was negative. Considering the nature of trauma and the course of symptoms, we strongly suspected a retained intraorbital organic foreign body. We requested for a repeat CT scan. Much to our surprise, it showed a large blow out fracture of the left medial wall with a large linear isodense foreign body of 6 X 1 cm, extending from the left medial canthal area through the ethmoid sinuses to the contralateral sphenoid sinus,



**Figure 1:**

A and B) External color photograph of a young 33-year old male who sustained an injury with a sugarcane foreign body 3 months back, showing mild tethering of left lower eyelid skin.  
C and D) Computed tomography scan of the orbit axial and coronal view showing a large linear hypodense foreign body of approximately 6 X 1 cm extending from the left medial orbit (white arrow) through the ethmoid sinus to the contralateral sphenoid sinus.



**Figure 2:**  
A and B) Intraoperative photograph showing external skin incision and wooden foreign body being grasped with a forceps.  
C, D, and E) Wooden foreign body being removed by combined external – endoscopic approach.  
F) Wooden foreign body measuring 6 X 1cm removed in toto.

likely to be a sugarcane foreign body considering the history.(Fig 1C & D) Keeping in mind the high risk of complications, we advised the patient to undergo an urgent wound exploration with removal of the foreign body with endoscopic guidance under general anesthesia.

An incision was made along the left infraorbital rim over the fistula and the medial canthal area explored. The sugarcane foreign body was identified. (Fig 2A & B) Under endoscopic guidance, granulation tissue encasing the foreign body was removed. The foreign body was grasped with forceps and removed intact.(Fig 2C-F) The post-operative period was uneventful. On follow up after two months, the patient was perfectly normal with no complications or functional impairment.

### Case 2:

The second case is that of a 9-year-old male child who presented to the emergency department within hours following an accidental stick injury while trying to pluck fruits from a guava tree. On examination, his best-corrected visual acuity was counting fingers in the right eye and 6/6, N6 in the left eye. The affected eye showed marked restriction of ocular motility with the eye fixed in adducted position, the pupil was mid dilated and sluggishly reacting to light. External examination showed 2-3 cm of a wooden foreign body protruding out from the medial canthus along with marked lid edema and conjunctival chemosis.

Considering the nature of the injury, we suspected deeper penetration of the wooden foreign body and requested for a magnetic resonance scan (MRI). MRI showed a long linear foreign body probably a wooden stick which was hypointense on T1 and T2, extending from the right medial orbit, entering into the ethmoid and sphenoid sinus up to the clivus with associated

fracture of the medial wall of the right orbit. (Fig 3 A and B) The patient was referred to a pediatric neurosurgeon and foreign body removal was done on an emergent basis via an endoscopic trans-ethmoidal approach. (Fig 3 C and D) Postoperatively he received a course of intravenous antibiotics.

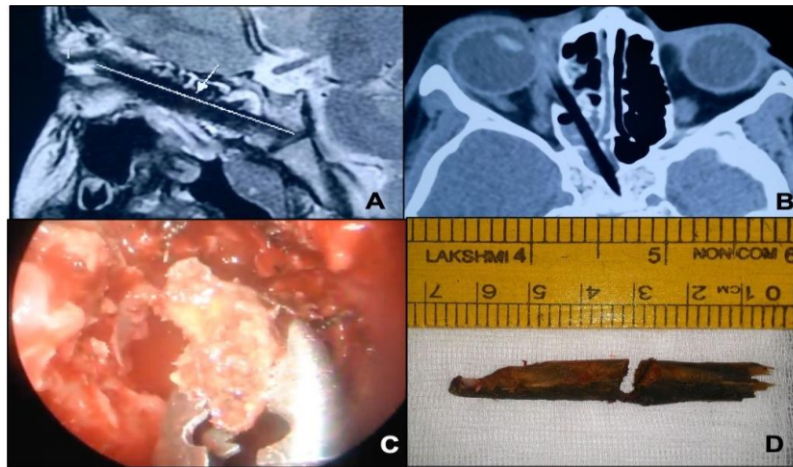
On follow up, the best-corrected visual acuity in the right eye had improved to 6/9, N6 with almost full ocular motility and nil functional or cosmetic deficit.

### Discussion:

Intra orbital organic foreign bodies like wood and sugarcane are often missed at the initial presentation. 4 In most cases the injury is trivial and the patient is unaware of their entry into the orbit. High-velocity injuries often have small external wounds, thus reducing the index of suspicion. 3 The presentation and management depend upon their size, location, and composition. Organic foreign bodies, being porous inconsistency, provide a good medium for microbial agents. Infection resulting from retained organic foreign bodies can lead to acute purulent inflammation, granulomatous tissue reaction, fistula formation, chronic osteomyelitis, and restrictive strabismus, thus necessitating urgent removal. 2,3

Radiological investigations to detect intraorbital organic foreign bodies are a challenging task due to their radiolucent nature. Plain film radiography does not play any role in localization. Axial and coronal CT views of 1-1.5 mm cuts are best suited for this purpose. They not only help in localization but also help detect any associated globe rupture or fractures involving the bony orbit. However, the radiodensity of wood varies with the time of presentation, thus mimicking air or orbital fat on CT scan and causing the diagnosis to be missed. 3





**Figure 3:** Magnetic resonance imaging sagittal view T 1 weighted image (A) and computed tomography scan axial view (B) of a 6-year-old boy who sustained wooden stick injury showing long linear foreign body extending from the right medial orbit into the ethmoid and sphenoid sinus and upto the clivus with associated fracture of the medial wall of the right orbit. C) Endoscopic view showing removal of the foreign body via a trans ethmoidal approach. D) Wooden foreign body removed as 2 fragments.

Magnetic resonance imaging (MRI) is a far superior modality to detect wooden foreign bodies as it depends on the proton density of tissues. This property of wood is dissimilar from that of the soft tissues in the orbit and thus appears hypointense on both T1 and T2 weighted images. Therefore in all suspected cases of wooden foreign bodies with a negative CT, MRI should always be taken to confirm the diagnosis.

Once diagnosed all organic foreign bodies warrant immediate removal due to the risk of vision and life-threatening complications. Penetrating foreign bodies involving the adjacent paranasal sinuses, extending into the intracranial cavity, or causing fracture of the orbital walls require a combined effort of an ophthalmologist, otolaryngologist, neurosurgeon and oro-facio-maxillary surgeon based on the extent of penetration. A multidisciplinary approach is mandated for expedient yet cautious and safe treatment.

Both our patients presented at different time intervals from injury with diverse clinical presentations. Both had very large organic foreign bodies invading the orbit and the sphenoid sinus. Timely management under endoscopic guidance helped remove the foreign bodies completely without any functional or cosmetic impairment. To conclude, In patients presenting with a history of trivial trauma with organic foreign body, a detailed history, along with thorough clinical examination, supplemented with radio-imaging is mandatory, especially in children to rule out retained intraorbital foreign bodies. Irrespective of

the time of presentation, appropriate and timely management in a multidisciplinary fashion under endoscopic guidance when required helps achieve good cosmetic and functional outcomes in penetrating sino-orbital organic foreign bodies.

#### Acknowledgements:

Dr. Olma Veena Noronha  
Consultant Radiologist, VRR scan, Chennai  
Dr. Balamurugan  
Consultant Neurosurgeon, Apollo Speciality Hospitals, Chennai

#### References:

- Reddy SC. Retained wooden foreign body in the orbit. *Int J Ophthalmol.* 2013;6(2):255-258.
- Panda BB, Kim UR. Complications of retained intraorbital wooden foreign body. *Oman J Ophthalmol* 2014;7:38-9.
- Kim YH, Kim H, Yoon ES. Unrecognized intraorbital wooden foreign body. *Arch Craniofac Surg.* 2018;19(4):300-303.
- Kumar D, Saxena S, Goel U. Retained wooden foreign bodies in the orbit: A case report. *Indian J Ophthalmol* 1995;43:195-6.
- John SS, Rehman TA, John D, Raju RS. Missed diagnosis of a wooden intra-orbital foreign body. *Indian J Ophthalmol* 2008;56:322-4.
- Lefebvre DR, Chandra RV. Diagnosis and treatment of penetrating orbital cranial foreign body injuries. *Digit J Ophthalmol.* 2012;18(4):9-11. Introduction

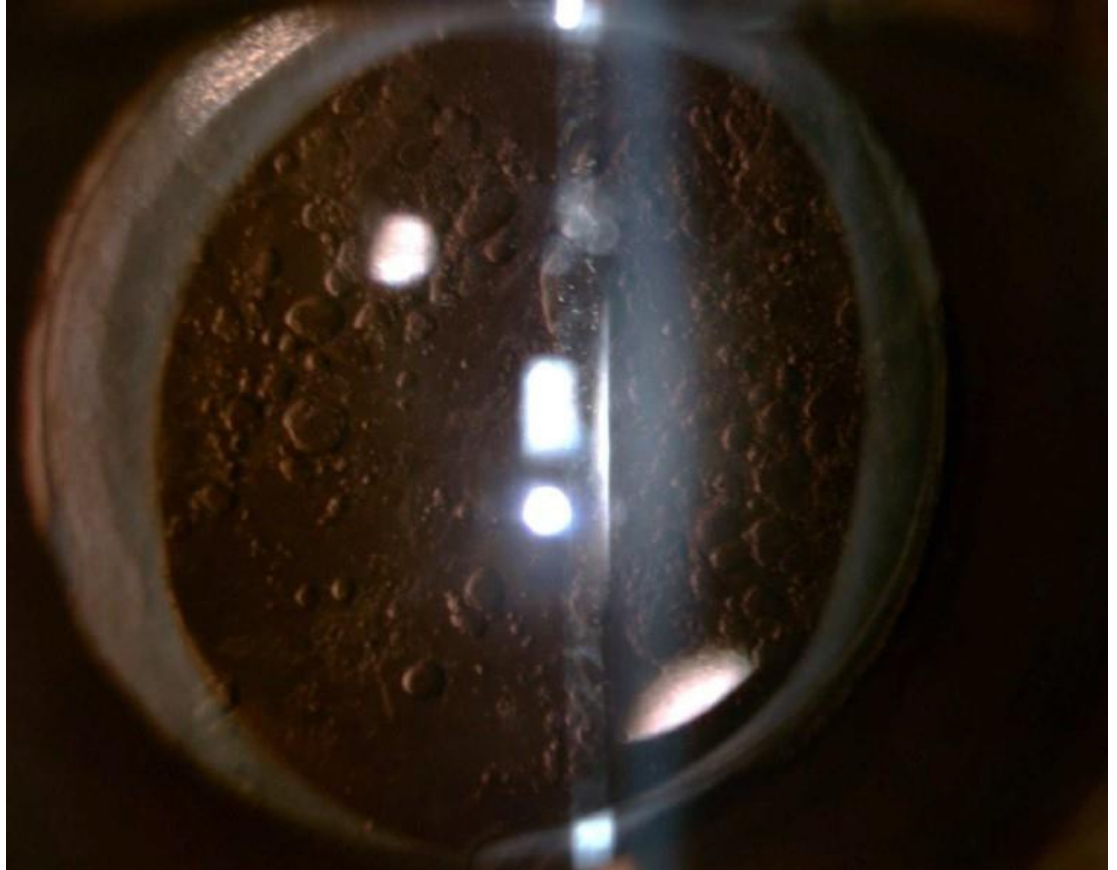
## Elsching's pearls

Arshad Iqbal

Author for Correspondence:

**Arshad Iqbal**

Fellow Comprehensive Glaucoma,  
Aditya Birla Sankara Nethralaya,  
Kolkata  
docarsh\_jlmc@yahoo.com



Elschnig's pearls (EP) or posterior capsule opacification (PCO) or secondary cataract or after cataract, is a common postsurgical complication following cataract surgery and intraocular lens (IOL) implantation. EP results from the proliferation, growth, migration and trans-differentiation of the residual lens epithelial cells (LECs) over the anterior capsule after cataract surgery. Cataract surgery induces a wound healing response in the lens releasing several cytokines and growth factors which play a major role in the pathogenesis of PCO. These growth factors include transforming growth factor (TGF), fibroblast growth factor 2 (FGF-2), hepatocyte growth factor, interleukins-1 and 6, and Epithelial growth factor. Clinically, there are 2 morphological types of PCO; Fibrous type and Regenerative or Pearl type. Fibrous type PCO is caused by the proliferation and migration of LECs which undergo epithelial mesenchymal transition resulting in fibrous metaplasia. This leads to formation of a thick fibrous folds and wrinkles over posterior capsule causing significant visual morbidity.

Pearl type PCO is caused by the LECs located at the equatorial lens region. There is a regeneration of crystallin-expressing lenticular fibers forming syncytial PCO which later transforms to Elschnig pearls (Figure above) and Soemmering ring. All types of PCOs can be effectively treated with Nd-YAG laser capsulotomy.

Hydrodissection enhanced cortical clean up, extensive and meticulous irrigation/aspiration, adequate anterior capsulorhexis, and manual polishing of the anterior and/or posterior capsule are some of the methods described for reducing the formation of PCO. Hydrophilic acrylic material IOL has higher PCO development rates compared to Polymethylmethacrylate (PMMA) or hydrophobic acrylic materials. Design wise the sharp edge optic IOL and the formation of a capsular bend are highly effective in reducing PCO. Surface modifications of PMMA IOLs by gas plasma, polyethylene glycol, carbon and titanium, heparin, and polytetrafluoroethylene have proven effective in preventing formation of PCO.

How to cite this article Elsching's pearls, Iqbal A, Sci J Med & Vis Res Foun 2018; 36 : 18

## Complete ocular coloboma: A rare occurrence

Anushree Kumar<sup>1</sup>

1. Dept of Glaucoma  
Kamalnayan Bajaj Sankara  
Nethralaya  
Newtown, Rajarhat, West  
Bengal, India  
anushree2203@gmail.com

Coloboma derived from the greek word "KOLOBOMA" meaning curtailed or mutilated is a rare congenital malformation of the neuroectodermal tissue of the optic cup.

During the 7th week of gestation, the optic cup is formed by the closure of the choroidal fissure, which leaves a round opening that later becomes the pupil. Failure of this process results in a persistent cleft which can involve the anterior or posterior parts of the eyeball.

Coloboma iridis which is the most common form, the malformation occurs anteriorly and is limited to the iris.

Anterior colobomas may also involve the ciliary body and Posterior colobomas may involve the optic nerve, retina and choroid. It has been estimated that the incidence of coloboma is around 0.7 cases per 10,000 live births. Colobomas are not usually familial, but they have been observed to be occasionally inherited in an autosomal recessive or, rarely, an X-linked pattern. Colobomas may also be associated with a with PAX2 gene mutations.

Colobomas can be unilateral, bilateral, it can also be associated with other ocular and extra ocular malformations or manifestations.

Here we report a case of a 20 yrs old young male patient who presented to our out patient department who was referred to our hospital from another city for further medical evaluation.

Patient came with a complain of poor vision of the right eye since early childhood which had progressed in the last five years. Family ocular history was not significant.

On examination the best corrected visual acuity was counting finger close to face and 6/5 for the right and left eyes respectively with latent nystagmus in the right eye.

On slit lamp examination (SLE), the eyelids, conjunctiva and cornea were normal bilaterally. The anterior chambers of both eyes were deep and quiet. Congenital cataract with zonules missing in the infero nasal quadrant with a notch in the infero nasal quadrant denoting lenticular and iris coloboma were noted with other eye lens and iris being normal.

Posterior segment examination of the right eye revealed retinochoroidal coloboma involving the optic disc, with left eye being within normal limit.

Systemic examination showed no abnormalities or any apparent congenital anomalies.

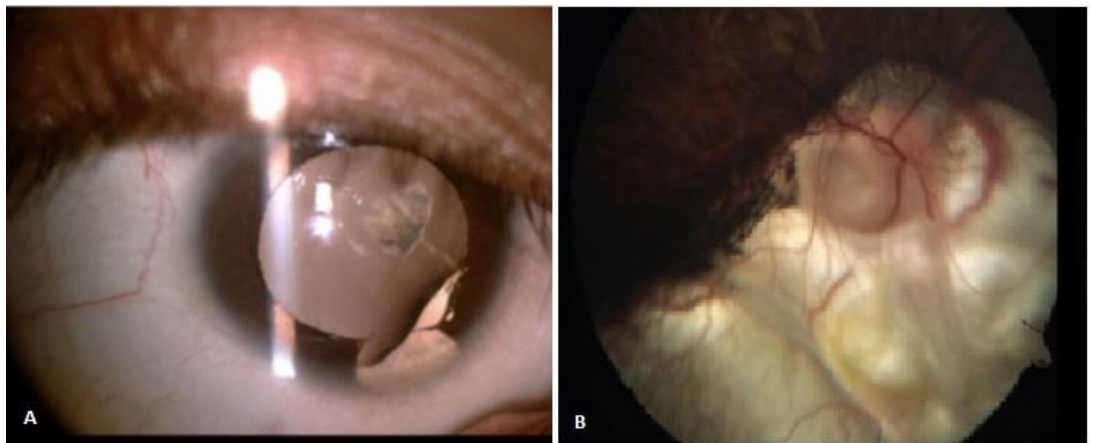


Fig of the right eye A) Lenticular and iris coloboma in the infero-nasal quadrant with zonules absent in the infero-nasal quadrant.

B) Retinochoroidal coloboma involving the optic disc.

How to cite this article Kumar A. Complete ocular coloboma: A rare occurrence, Sci J Med & Vis Res Foun 2018; 36 :19

## Teaching and presenting in the virtual space

Meenakshi Swaminathan<sup>1</sup>

<sup>1</sup> Department of Pediatric  
Ophthalmology and Strabismus,  
Sankara Nethralaya, Chennai

Author for Correspondence:

**Meenakshi Swaminathan**

Senior Consultant, Department of  
Pediatric Ophthalmology and  
Strabismus,  
E mail: drms@snmail.org

For those of us who have practised teaching to students in a physical classroom, or presenting to a room full of people, a shift to the virtual space, with hardly any preparation or training, may be a daunting experience. The virtual space is indeed a new environment and one can get comfortable in it, by following a few guidelines. This article outlines the tips and tricks to not just survive but excel in the virtual class room or conference.

There are a few reasons why the virtual environment may seem scary-distractions of a home, or office, use of technology, anticipated or feared boredom of the audience especially if you cannot see their reaction, and a feeling of inability to connect with your virtual audience. There are two parts to a successful presentation in the virtual space- design, delivery.

Let your slides not have too much content. Your presentation should pay attention to three elements. These are structure, style and emotion. First let us consider certain aspects of structure. A technique that is used commonly in presentations is called Chunking. Content is broken down into bite-size chunks. This makes it easier to absorb and integrate into long term memory. You can also use the magic of 3s, for example 'Reduce, Reuse, Recycle' as seen in popular slogans. The whole content can also be broken down into three segments- beginning, middle and end. The presentation should be designed in terms of outcomes-what you wish the audience to think, feel and be able to do at the end of your talk. Moving on to style, liberal use of contrast helps keep the audience attention. It is also not necessary to read everything that is on the slide. It is best to keep your Powerpoint or any other slides that you use simple and clutter free. When you think of emotions, it is important to trigger the right ones. Use of appropriate pictorial content along with paying attention to the pace, articulation, tone, modulation and repetition are all important.

On the day of the presentation there are certain do's and don'ts that have been termed as 'Netiquette'. It is good to keep your background at home or in your office with less clutter.

Camera positioning is crucial and you should ensure that there is no glare if you are wearing glasses and that you do not appear to be looking down into the camera. Adequate lighting on your face is important too. Your attire should be business casual even if you are in your home space. Be on time and practice looking at the camera. Ensure that you have adequate bandwidth for a smooth sail. Wearing a lapel microphone can also help with capturing your voice well.

It is good to familiarize yourself with the technology beforehand as different platforms may vary in some key features. Getting to know how to share the screen and use chat to keep in touch with audience and other speakers makes your presentation stress free. It is even more important if you are the host that transitions are smooth.

If it is a class, you may wish to request audience to keep their microphones on mute. Video too can be muted and you can converse with the chat. You can also ask a specific person to unmute his/her audio and answer during a question-answer session. You can also appoint a student or a co-instructor to interrupt and ask questions from the Chat. Absence of visual cues can be a challenge but interaction especially in smaller groups can make the session lively.

With these tips and tricks anyone should be able to master teaching and presenting in the virtual space.

How to cite this article Swaminathan M. Teaching and presenting in the virtual space, Sci J Med & Vis Res Foun 2018;36:20.



## Microbial keratitis

Raj Shekhar Paul,<sup>1</sup> Aditi Johri<sup>1</sup>

1. Department of Cornea and Ocular Surface, Aditya Birla Sankara Nethralaya, Kolkata-700 099, West Bengal, India

Corresponding Author:

**Raj Shekhar Paul**

Department of Cornea and Ocular Surface, Aditya Birla Sankara Nethralaya, Kolkata-700 099, Email: rsl@snmail.org

### Introduction

Microbial keratitis ( MK ) or corneal ulcer is a potentially sight threatening ocular emergency. Ocular trauma remains the major cause of corneal ulcer in developing countries with worldwide burden of ocular morbidity ranging from 1.5 – 2 million whereas in the developed world, contact lens wear remains a major risk factor. The major causative organisms include a variety of bacteria, fungus, viruses and acanthameba induced keratitis.

### History Taking

Following important histories should be ruled out in any case of suspected MK :

Trauma

Previous ocular surgeries

Contact lens wear

Bathing in ponds

Long term use of topical medications especially corticosteroids

History of systemic diseases like diabetes mellites , rheumatoid arthritis , AIDS, hepatitis , tuberculosis and malignancies

Pre-existing ocular adnexal morbidities concerning ocular surface e.g. Steven Johnson Syndrome, Congenital corneal anaesthesia, lacrimal outflow obstruction, eyelid malpositions and lagophthalmos

### Clinical Features

#### Bacterial Keratitis

**Gram positive cocci** (Fig A)

Localized round or oval ulceration

Greyish white stromal infiltrates

Distinct borders and

Minimal surrounding stromal haze

**Gram negative bacilli** (Fig B)

Dense stromal suppuration and

Hazy surrounding cornea giving ground glass appearance

Rapid worsening of clinical signs

**Atypical Mycobacteria keratitis** (Fig C)

cracked windshield appearance

ring infiltrate

satellite lesions

infectious crystalline keratopathy

#### Fungal Keratitis (Fig D)

Dry looking ulcer

Stromal infiltrates with feathery edges

Satellite lesions

Thick endothelial exudates

Hypopyon

#### Viral Keratitis (Fig E)

##### **Herpes simplex keratitis**

Epithelial - Superficial punctate lesions which coalesce to form linear lesions classically seen as dendrites with swollen terminal bulbs

enlarge to form geographical configuration

Dendrites are double stained , i.e. base stained by fluorescein and borders by Rose Bengal.

Stromal involvement - immune or necrotizing stromal keratitis

Endotheliitis (disciform , diffuse , linear pattern)

-inflammatory cells and keratic precipitates on endothelium

Reduced corneal sensation

#### Protozoal Keratitis

##### **Acanthameba keratitis** (Fig F)

Epithelial irregularities

Stromal infiltrates , classically arranged in ring shaped configuration

Radial keratoneuritis: Pathognomonic sign

#### Others

##### **Nocardia keratitis** (Fig G)

Multiple small white infiltrates arranged in wreath pattern

##### **Microsporidial Keratitis** (Fig H)

Raised, coarse epithelial lesions (‘stuck on’ appearance)

Deep stromal keratitis

##### **Pythium keratitis** (Fig I)

Multiple linear tentacle like lesions

Dot – like or pin-head like infiltrates

Raised white/off white plaque like infiltrate surrounded with peripheral thinning (guttering)

## Laboratory diagnosis

Routine stains	10% potassium hydroxide Gram stain Giemsa Calcofluor white
Special stain	Modified Ziehl Neelsen (nocardia, microsporidia, atypical mycobacteria)
Routine culture media	Blood agar MacConkey agar Chocolate agar Sabouraud dextrose agar Brucella blood agar Brain heart infusion broth
Special culture media	Non nutrient agar (1.5%) with E. Coli overlay (Acanthameba) Lowenstein-Jensen Media (Atypical mycobacteria)

Table 1 : Various stains and culture media

GPC- gram positive cocci, GNC- gram negative cocci, GPB- gram positive bacilli, GNB- gram negative bacilli, PHMB – polyhexamethylene biguanide

### Surgical Options:

Tissue adhesives ( cyanoacrylate or fibrin glue) with bandage contact lens (impending perforations or perforations  $\leq$  2mm)

Tenons or corneal patch graft ( for perforations  $>$ 2 mm)

Amniotic membrane transplantation

Conjunctival flap

PACK – CXL (Photoactivated chromophore for infectious keratitis – Collagen cross linking)

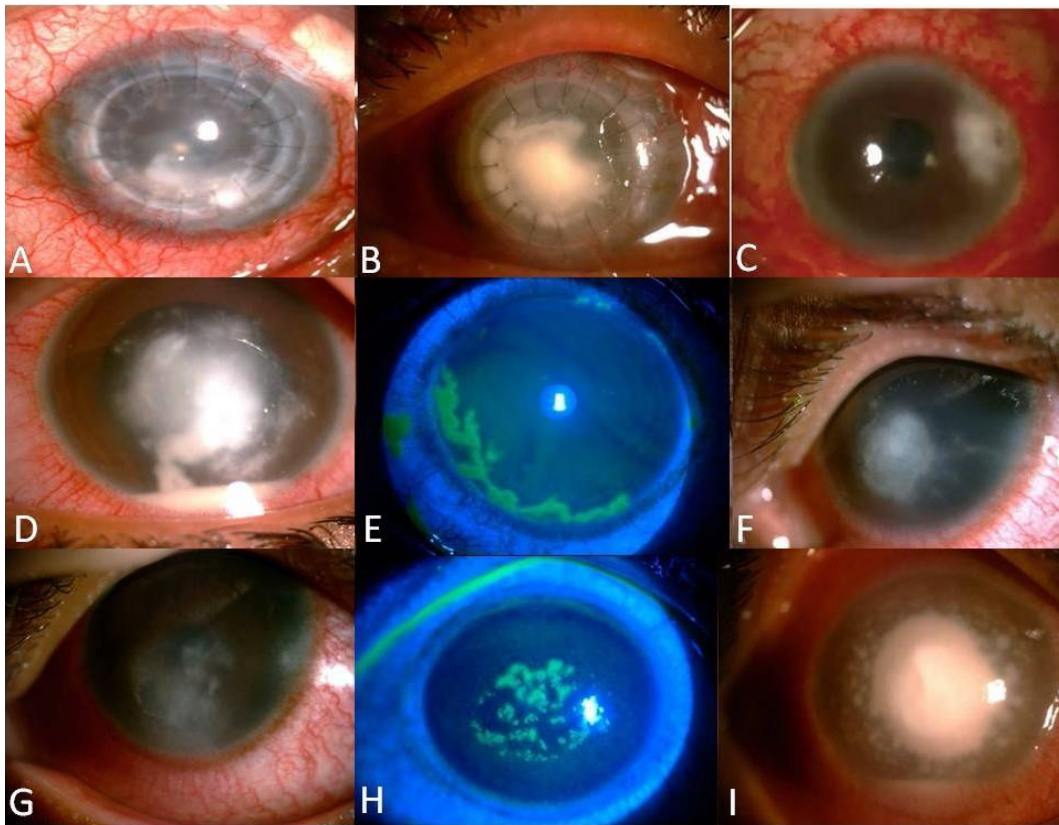
DALK (Deep Anterior Lamellar Keratoplasty)

TPK (Therapeutic Penetrating Keratoplasty)

	GPC	GNC	GPB	GNB
Antibiotics	Fluroquinolones Cefazolin Vancomycin Linezolid	Ceftriaxone Ceftazidime Fluroquinolones	Amikacin Fluroquinolones Clarithromycin	Fluroquinolones F. Tobramycin Amikacin Ceftazidime Piperacillin Imipenem Colistin
Anti fungals	Polyenes		Imidazoles	
	5% Natamycin (Filamentous Fungi) 0.15% / 0.25% Amphotericin B (Yeast)		Ketoconazole Voriconazole Fluconazole Itraconazole	} Filamentous Fungi
Antiviral	Acyclovir , Ganciclovir , Valacyclovir , Foscarnet			
Antiamoebic	Biguanides	Diamidines	Azoles	Aminoglycosides
	0.02% Chlorhexidine 0.02 % PHMB	0.1% Propamidine Isethionate	Voriconazole Posaconazole	Neomycin Paromomycin

Microbial Keratitis

Table 2: Summary of medical management of microbial keratitis



A: Streptococcal keratitis (suture infiltrate)	B: Pseudomonas keratitis	C: Mycobacterial keratitis
D: Fungal keratitis	E: Viral keratitis	F: Acanthamoeba keratitis
G: Nocardia keratitis	H: Microsporidial keratitis	I: Pythium keratitis

**Additional Pearls**

Mydriatics and cycloplegics (1% atropine, 2% homatropine and 1% cyclopentolate) should be prescribed to relieve ciliary spasm and pain. Antiglaucoma medications may be required in select cases.

Pythium keratitis is currently being treated with topical linezolid (0.2%) and topical (1%) and oral azithromycin.

Topical amikacin (2.5%) has been found to be sensitive for nocardia keratitis along with topical trimethoprim-sulfamethoxazole and imipenem.

Topical fluoroquinolones along with systemic albendazole have been studied for microsporidial keratitis.

Topical corticosteroids are contraindicated in fungal keratitis and have shown no benefit in bacterial keratitis.

Topical steroids can be prescribed in Herpetic stromal keratitis and Acanthamoeba keratitis to prevent sequelae under the cover of antivirals and antiamebics respectively.

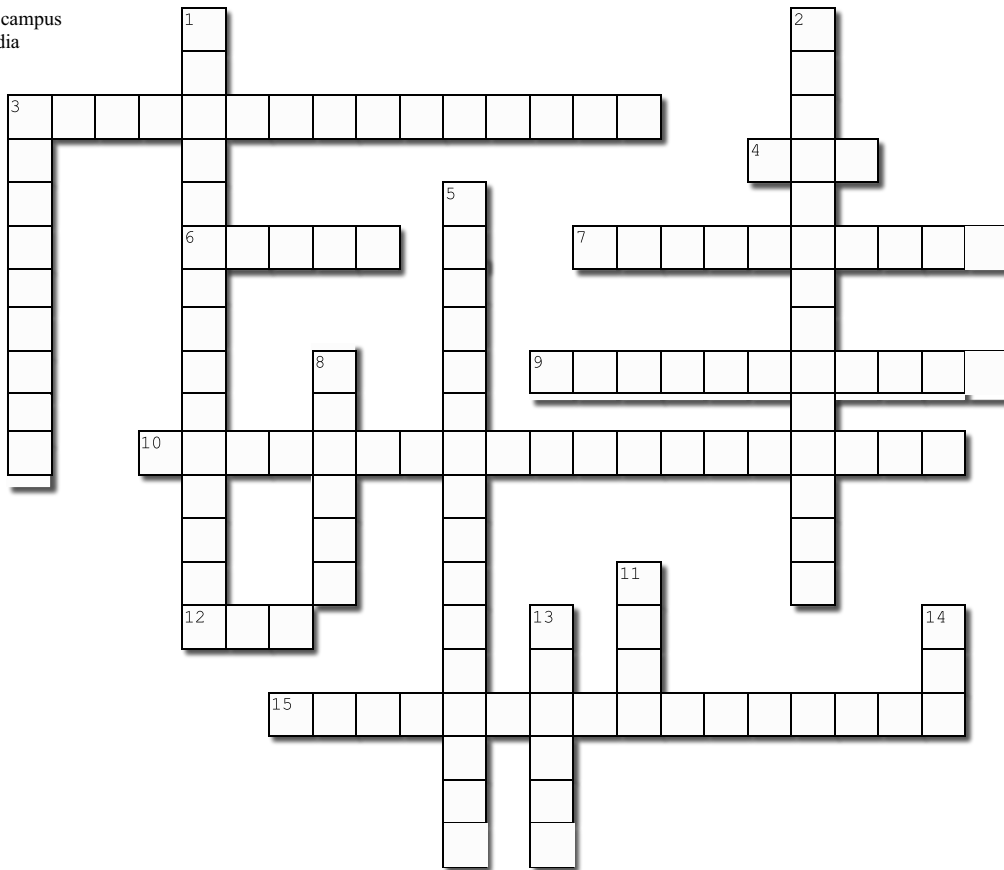
How to cite this article Paul R S, Johri A. Microbial keratitis, Sci J Med & Vis Res Foun 2018;36:21 - 23

**Akruti Desai**  
 Consultant  
 Ophthalmic Plastic  
 Surgery Services  
 L V Prasad Eye Institute  
 GMR Varalakshmi campus  
 Visakhapatnam, India

Name: \_\_\_\_\_

## CROSSWORD

Complete the crossword puzzle below



Created using the Crossword Maker on TheTeachersCorner.net

**Across**

- 3. Frasers syndrome includes partial syndactyly, renal and genital abnormalities and which ophthalmic condition [15]
- 4. Raised ICT without SOL, papilledema, empty sella and normal CSF . Who am I ?(abbr) [3]
- 6. Syndrome - Brushfield spots on iris [5]
- 7. Homocystinuric the lens is \_\_\_\_\_subluxated [10]
- 9. A condition in which Schwalbe's ring is visible on slit lamp examination [11] (clue:posterior)
- 10. In infants, glaucoma in Struge-Weber syndrome is due to [19]
- 12. Cracked windshield appearance of cornea at the edge of central infiltrate in early course of this infection (abbr)[3]
- 15. Drug-induced cicatrising conjunctivitis [16]

**Down**

- 1. Hyper-echoic spot on the disc persisting even in low gain [5,4,6]
- 2. Small breaks in Bruch's membrane seen in pseudoxanthoma elasticum [7,6]
- 3. Word keloid derived from Greek word cheloid which means \_\_\_\_\_[5,4]
- 5. Ocular inflammatory reaction to foreign bodies such as caterpillar hairs is known as ? [10,6]
- 8. Pathognomonic finding of nocardia keratitis on slit lamp is anterior stromal infiltrates arranged in which form? [6]
- 11. Central serous retinopathy with a double layer sign , \_\_\_\_\_ should be ruled out ( abbreviation) [4]
- 13. Dot & fleck retinopathy seen in a syndrome affecting kidneys, ears and eyes [6]
- 14. Condition with tendency of eye to elevate (slow), abduct and extort when binocularity is suspended(abbr) [3]



## Instructions to the Authors

### Types of Manuscripts

Article Type and Description	Word limit	Maximum references	Maximum Tables and Figures	Types of Study	Abstract
Original articles	2500 (Excluding abstract and references)	30	Maximum 5 including all	<p>Randomized Controlled Trials</p> <p>Prospective Observational / Interventional</p> <p>Retrospective observational / Interventional</p> <p>Descriptive Data</p> <p>Research about diagnostic test / accuracy of tests/modalities</p> <p>Parts – Introduction, Materials &amp; Methods, Results, Discussion, Conclusion &amp; References</p>	Structured abstract (Purpose, Material and Methods, Result and Conclusion) Word limit: 300
Review articles	For Major review- 4000, For Mini review - 3500	No limit for major review 50 for mini review	Maximum 5 figures and 5 tables	<p>Parts –Introduction: Include the statement for your literature search Rest of the portion can be written in different sub headings as per authors' preference</p>	Unstructured abstract Word limit: 300
Case Report / Case Series	1500 (Excluding abstract and references)	12	Maximum 3 including all Authors are suggested to make collages of their images	<p>Case Report – reporting a single case which should be a unique or a rare entity. It should be well documented.</p> <p>Case Series – A minimum of 3 to a maximum of 5 cases on the same entity</p> <p>Parts -Introduction, Case Report, Discussion, Conclusion&amp; References</p>	Unstructured abstract Word limit: 200

Ophthalmic Images	350	Not required	One image with maximum 4 composite pictures	Unique entities or good quality images of routine clinical entities. The images should be self-explanatory	Not required
Nutshell	1500	Not required	Maximum 3 including tables and flowcharts	Invited guest column. Overview of management of a particular ophthalmic ailment. Flowcharts and algorithm format are preferred.	Not required
Letter to the Editor	1000	5	One image with maximum 2 composite pictures	Any opinion regarding previously published articles in the journal and description of a novel technique or a case which raises awareness in the ophthalmological society	Not required
Miscellaneous	700	Optional	Maximum 1 including all	Includes short communication, perspectives, crosswords, poetries or other miscellaneous interesting articles with ophthalmology as the central idea	Not required

### **Ethics**

Do not reveal patient's identity and record number in the manuscript or in the illustrative documents. Do not duplicate other research papers or textual materials. Images reproduced from books, chapters, internet or other articles will require a permission form from the publishers or the owner.

### **References**

References should be numbered on the order of their citation in the text. Put the citation in numerical form as superscript after the punctuations. Refer to Vancouver style of quoting the references.

For example:

*Koka K, Alam MS, Subramanian N, Subramanian K, Biswas J, Mukherjee B. Clinical spectrum and management outcomes of Langerhans cell histiocytosis of the orbit. Indian J Ophthalmol 2020;68:1604-8*

For more than six authors, list the first six followed by et al.

For books

Author(s) of the chapter. Title of the chapter. In: Name of the chief editor, editor. Name of the book, edition no. City of publication: Name of the Publisher;Year:page no.

### **Tables**

Do not embed the tables in the manuscript. Submit the tables separately as word files.

The tables should be called in the text wherever they are relevant.

The legends for the tables should be mentioned in the header.

The expanded form of the abbreviations should be mentioned in the footnote.

Do not duplicate tables from other text materials.

## **Figures & Illustrations**

All the figures should be in JPEG or TIFF format.

The pictures should be of high resolution (300 dpi).

Maximum of 6 composite pictures are allowed per figure. The pictures should be labelled as “a”, “b” and so on in Arial font, (black or white text color whichever would serve as a contrast).

All the figures should be numbered and called out consecutively according to the order in which they appear in the manuscript .

Do not embed the figures in the manuscript file or do not send it as a word document. Submit all images separately in the JPEG or TIFF format.

The legends should describe the image briefly (50 words) and should be included in the manuscript file after the references.

## **Presentation Format**

Text font: Times New Roman / Arial

Font size: 12

Double spacing

Headings in title case (not ALL CAPS)

Write the expanded form of each abbreviation at its first use in the title, abstract and text separately, with the abbreviation appearing in the brackets.

Numerals from 1 to 10 spelt out and numerals at the beginning of the sentence should be written in word form and not figure.

## **Submission of Manuscripts**

All manuscripts should be submitted online through mail at email id: drmsa@snmail.org. The submitted manuscripts not adhering to the instructions would be returned to the authors for technical correction.

The manuscript should be submitted in the following parts.

1. Cover Letter
2. Title Page (MS Word file) – The type of the article  
The Title of the article  
Name, designation, and email id of all the authors  
Corresponding author name, his/her designation, and email id  
Total word count (Separately for the abstract and manuscript)
3. Article File (Manuscript and abstract) \
4. Tables (MS Word file)
5. Images – to be submitted as JPEG or TIFF files only.

**Akruti Desai**

Consultant

Ophthalmic Plastic

Surgery Services

L V Prasad Eye Institute

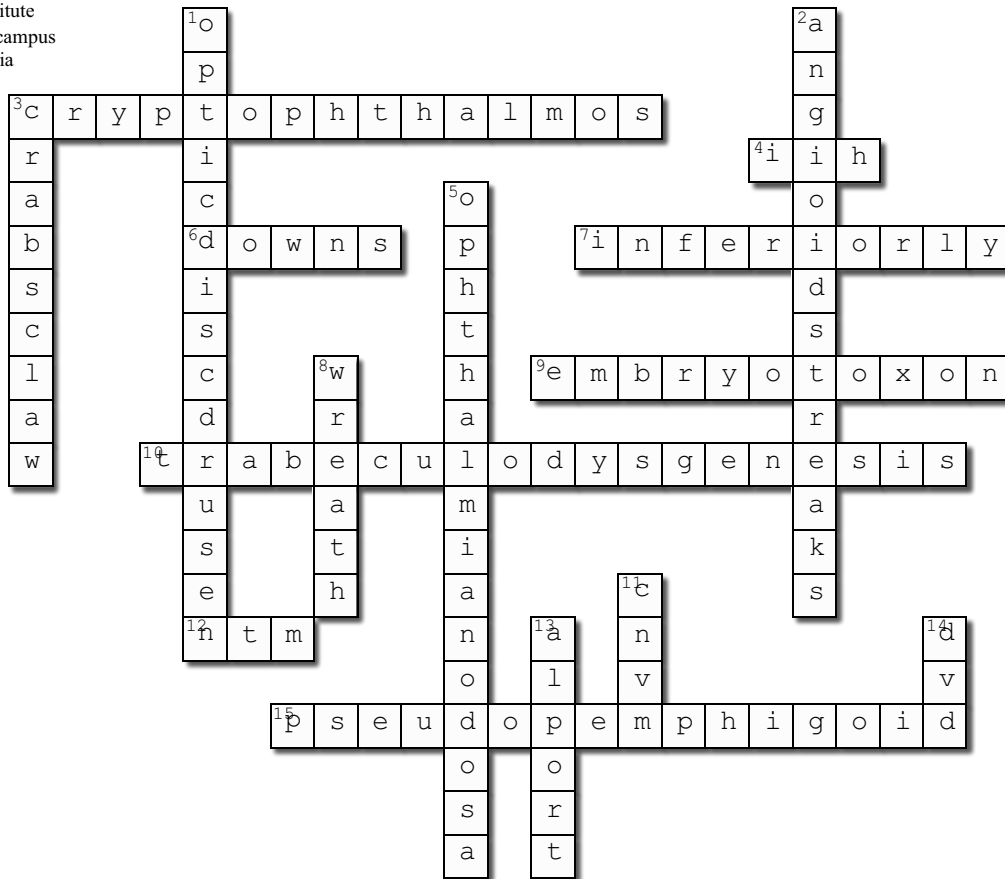
GMR Varalakshmi campus

Visakhapatnam, India

Name: \_\_\_\_\_

## CROSSWORD

Complete the crossword puzzle below



Created using the Crossword Maker on TheTeachersCorner.net

### Across

3. Frasers syndrome includes partial syndactyly, renal and genital abnormalities and which ophthalmic condition [15] (**cryptophthalmos**)
4. Raised ICT without SOL, papilledema, empty sella and normal CSF . Who am I?(abbr) [3] (**iih**)
6. Syndrome - Brushfield spots on iris [5] (**downs**)
7. Homocystinuric the lens is \_\_\_\_\_subluxated [10] (**inferiorly**)
9. A condition in which Schwalbe's ring is visible on slit lamp examination [11] (clue:posterior) (**embryotoxon**)
10. In infants, glaucoma in Struge-Weber syndrome is due to\_[19] (**trabeculodysgenesis**)
12. Cracked windshield appearance of cornea at the edge of central infiltrate in early course of this infection (abbr)[3] (**ntm**)
15. Drug-induced cicatrising conjunctivitis [16] (**pseudophigoid**)

### Down

1. Hyper-echoic spot on the disc persisting even in low gain [5,4,6] (**opticedrusen**)
2. Small breaks in Bruch's membrane seen in pseudoxanthoma elasticum [7,6] (**angioidstreaks**)
3. Word keloid derived from Greek word cheloid which means \_\_\_\_\_[5,4] (**crabsclaw**)
5. Ocular inflammatory reaction to foreign bodies such as caterpillar hairs is known as ? [10,6] (**ophthalmianodosa**)
8. Pathognomonic finding of nocardia keratitis on slit lamp is anterior stomal infiltrates arranged in which form? [6] (**wreath**)
11. Central serous retinopathy with a double layer sign , \_\_\_\_\_ should be ruled out ( abbreviation) [4] (**cnvm**)
13. Dot & fleck retinopathy seen in a syndrome affecting kidneys, ears and eyes [6] (**alport**)
14. Condition with tendency of eye to elevate (slow), abduct and extort when binocularity is suspended(abbr) [3] (**dvd**)