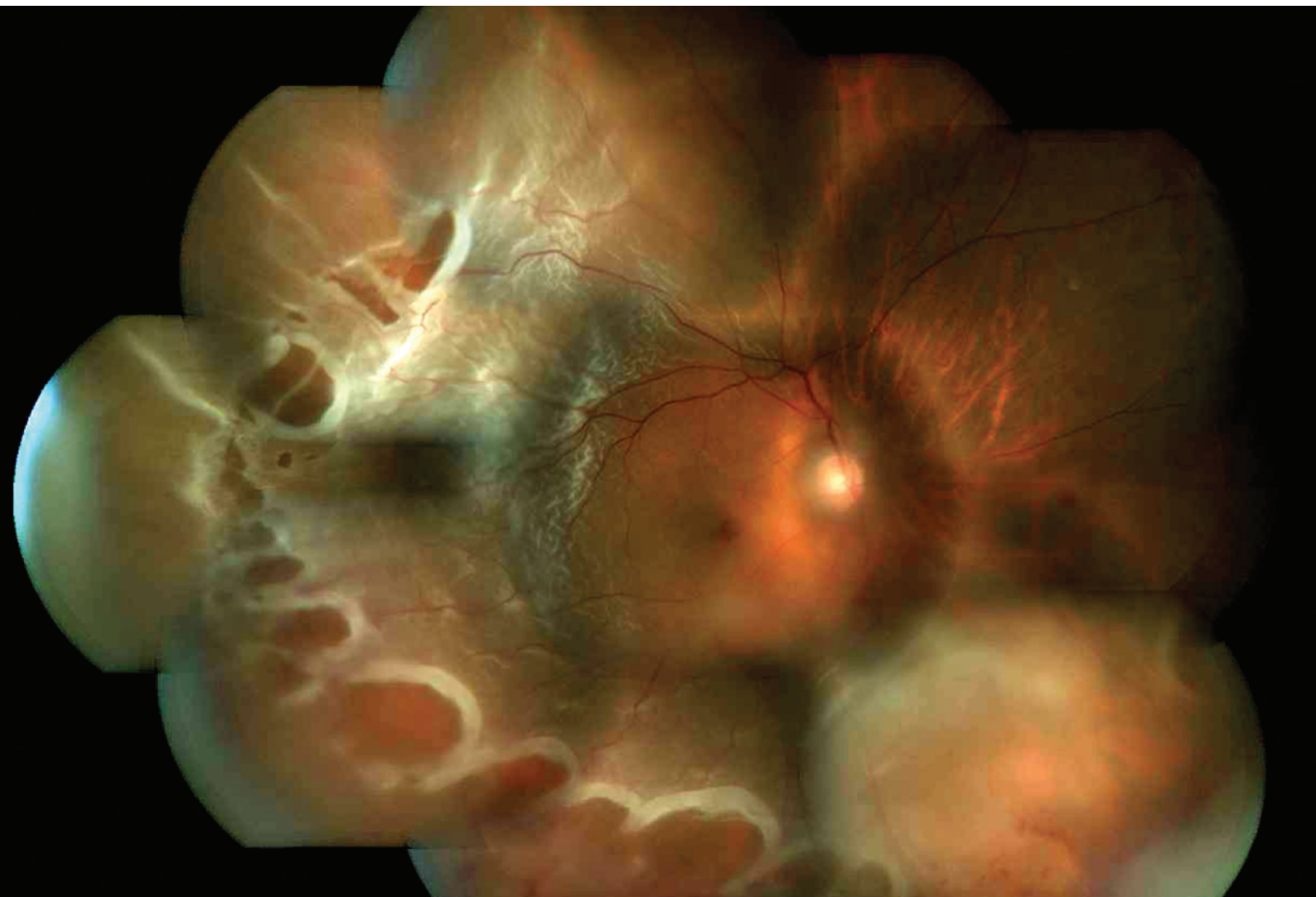

insight

Scientific Journal of

MEDICAL & VISION RESEARCH FOUNDATIONS



insight

Scientific Journal of **Medical & Vision Research Foundations**

Year: 2017

Issue: Vol. XXXV | No. 2 | July 2017 | Pages 1–55

Typeset at: Nova Techset (P) Ltd., Chennai, India

Printed at: Gnanodaya Press, Chennai, India

©Medical and Vision Research Foundations



Sankara Nethralaya – The Temple of the Eye.

It was in 1976 when addressing a group of doctors, His Holiness Sri Jayendra Saraswathi, the Sankaracharya of the Kanchi Kamakoti Peetam spoke of the need to create a hospital with a missionary spirit. His words marked the beginning of a long journey to do God's own work. On the command of His Holiness, **Dr. Sengamedu Srinivasa Badrinath**, along with a group of philanthropists founded a charitable not-for-profit eye hospital.

Sankara Nethralaya today has grown into a super specialty institution for ophthalmic care and receives patients from all over the country and abroad. It has gained international excellence and is acclaimed for its quality care and compassion. The Sankara Nethralaya family today has over 1400 individuals with one vision – to propagate the Nethralaya philosophy; the place of our work is an Alaya and Work will be our worship, which we shall do with sincerity, dedication and utmost love with a missionary spirit.

Contents

Guest Editorial: Retinal detachment—evolution and changing trends in management <i>Pramod Bhende</i>	1
Major Review: Evolution of retinal detachment surgery down the ages <i>Bikramjit P Pal and Kumar Saurabh</i>	3
Tips & Tricks: Managing retinal detachment: tips for the beginners <i>Lingam Gopal</i>	7
Major Review: Scleral buckling versus vitrectomy for primary rhegmatogenous retinal detachment <i>Aditya Maitray, V Jaya Prakash and Dhanashree Ratra</i>	10
Literature Search: Rhegmatogenous retinal detachment: Contribution of Sankara Nethralaya to literature <i>Rupak Roy and Rajiv Raman</i>	20
Major Review: Surgical implications in exudative retinal detachment <i>Suganeswari Ganesan and Ekta Rishi</i>	29
Case Report: Managing a case of buckle intrusion with recurrent vitreous haemorrhage: a case report <i>Sharan Shetty and Muna Bhende</i>	37
Case Report: Scleral buckle infection presenting as subretinal inflammatory mass lesion <i>Kalpita Das, Gaurav Mathur and Muna Bhende</i>	41
Case Report: Macular buckle for myopic retinal detachment <i>Anmol Naik and Pradeep Susvar</i>	44
Case Report: Retinal vein occlusion following vitrectomy for rhegmatogenous retinal detachment: a case report <i>Eesh Nigam and Debmalya Das</i>	48
Case Report: Some holes need no peeling: a case report of spontaneous closure of macular hole in a case of treated rhegmatogenous retinal detachment <i>Debmalya Das and Eesh Nigam</i>	51
Current Practice Pattern: Practice pattern for managing retinal detachment: a narrative of three generations of vitreoretinal surgeons <i>Chetan Rao and Girish Rao</i>	53

Retinal detachment—evolution and changing trends in management

Pramod Bhende

Correspondence:

Pramod Bhende, Director
Shri Bhagwan Mahavir
Vitreoretinal Services,
Medical Research Foundation,
Sankara Nethralaya,
Chennai, India.
Email: drpb@snmail.org



Since the first successful report by Gonin, retinal detachment (RD) surgery has come a long way and over the last 70–80 years, the anatomical success rate has increased to over 90%.

The evolution of RD surgery is both exciting and fascinating. RD, from being an inoper-

able problem to one where surgery has an over 90% success rate, is probably one of the greatest success stories in the world of medicine. Although Ware gave the first description of RD in 1805, an accurate clinical diagnosis of RD was possible only after Helmholtz invented the ophthalmoscope (1850). With further modification over time, an indirect ophthalmoscope, introduced by Schepens, became the main diagnostic tool for retinal disorders even today.

Many procedures were proposed to reattach the retina but with hardly any success until Gonin proposed that a retinal break was responsible for the detachment. He reported successful reattachment of the retina by sealing the retinal break (1920) using a cautery (*Ignipuncture*). With this technique, Gonin could achieve a success rate of more than 50%. Subsequently, many researchers contributed to the advancement and success of retinal surgery by trying various innovative techniques and surgical methods. Modern established surgical techniques for RD repair, such as, retinopexy, scleral buckle, vitrectomy and internal tamponade, have evolved over a period of time but revolve around the basic principle of '*closure of retinal break and relieving vitreous traction*'.

Kasner proposed and proved that the eye can tolerate removal of vitreous and was the first to advocate open sky vitrectomy. Although Dodo (1955) and Haruta (1959) from Japan published their vitrectomy techniques years earlier, Robert Machemer, considered as the 'Father of modern VR surgery', reported his first pars plana vitrectomy in 1970 for non-resolving vitreous haemorrhage and went on to propose newer instruments, techniques and indications for vitrectomy. Miniaturization of instruments and the development of operating microscope contributed to establish current standard three-port vitrectomy techniques.

Scleral buckle, vitrectomy or any other procedure? Despite significant improvement in techniques, instrumentation and better understanding of

patho-anatomy leading to dramatic success in RD management, reasonable disagreement exists as to which approach is best as far as surgical intervention is concerned. In the past, scleral buckling was considered as the 'Gold standard' and pars plana vitrectomy was used either in recurrent RD following scleral buckling or primarily in complicated detachments. In 1985, Escoffery published his first report of vitrectomy without scleral buckling for the management of RD. Since then we know that the process of vitrectomy which includes near complete removal of vitreous traction, ability to clear media opacities leads to better visualization and identification and hence better treatment of retinal break/s and further improvement in surgical outcomes.

With the availability of smaller gauge instrument (MIVS) with better fluidics, wide angle visualization and brighter illumination, there is an increased safety margin leading to reduced intraoperative complication rate, reduced overall surgical time and reduced post-surgery morbidity with a final better reattachment rate. There is an increasing trend to use vitrectomy as the primary option for retinal reattachment surgery, although there is no clear evidence of superiority of one procedure over the other. The combined surgical approach of vitrectomy with scleral buckle has also been an area of debate and multiple studies have shown conflicting results. There is a general consensus that primary vitrectomy is better for RD in pseudophakic/aphakic eyes and SB yields a better single-surgery success rate in phakic eyes. The available set-up, training and competence and technical familiarity of the operating surgeon also influence the selection of surgical procedure, and we may need '*expertise-based*' trials to eliminate a surgeon factor while performing newer trials for better interpretation of the results.

The introduction of MIVS has made a paradigm shift in the way we approach our cases. The speed, efficiency, early rehabilitation and most importantly 'no suture technique' are appealing for both surgeons and the patients. There are further attempts to go for thinner, smaller instruments with higher cut rates. Do we really need these? What is an ideal gauge for microsurgery? Are they really superior for patient care? What about surgical efficiency and safety? Should we go for it just because they are available, or due to peer pressure? We do not have answer to all these questions at present.

With increasing options in the VR surgeons' armamentarium, it is becoming more and more difficult for us to choose the appropriate technique in a given case and it is here that experience and familiarity with various techniques matters. While training our young retina surgeons to adopt these newer exciting technology and techniques, it is equally important to ensure that they learn their basics right.

Sankara Nethralaya is organizing the 'Retina Summit 2017', our second theme based annual retina meeting, in July 2017. The focus of this year's meeting is 'Retinal detachment'. Eminent and experience faculty from India and across the globe will be discussing various management options for simple and complex RDs including controversies in management and associated

complications. I hope the meeting will be a great learning experience for both practicing surgeons and retina surgeons in training.

This issue of '*Insight*' is rolling out at the time of the 'Retina Summit 2017' and is dedicated to the management of RD, the very focus of this meeting. This issue covers diverse topics related to evolution of RD surgery, tips for beginners, current trends and controversies in the management of retinal reattachment surgery, surgery for exudative RD and case reports of management of unusual complications of surgery. As Sankara Nethralaya is known for its expertise in VR surgery, we would also highlight SN's contribution in establishing VR surgery as a specialty in Indian subcontinent and it's contribution to the existing published literature on RD.

How to cite this article Bhende P. Retinal detachment—evolution and changing trends in management, *Sci J Med & Vis Res Foun* 2017;XXXV:1–2.

Evolution of retinal detachment surgery down the ages

Bikramjit P Pal¹ and Kumar Saurabh²

^{1,2}Associate consultant,
Consultant,
Vitreoretinal Services,
Sankara Nethralaya,
Kolkata, India

Correspondence:

Bikramjit P Pal,
KamalNayan Bajaj Sankara
Nethralaya,
NewTown, Rajarahat,
Kolkata, India.
Email: drbpp@snmail.org

“Treatment of retinal detachment associated with retinal holes should not be urged except in only eyes as a last clutch at a straw of hope”. These lines by Lister from 1927 and the famous survey by Vail a decade prior (1912),¹ which found a success rate of retinal detachment (RD) as 1 in 1000 speaks for themselves, suggest a grave prognosis for RD. Although the current success rate in managing uncomplicated RDs is greater than 90%, the journey has been the most intriguing with the emergence of many heroes. One such hero who stands apart is Jules Gonin, whose patience and perseverance have led to the current understanding and treatment of RD as we know it. The evolution of RD surgery has always been divided into ‘Pre-Gonin’ and the ‘Post-Gonin’ phases. With no intent to change the same, we hereby briefly describe the evolution of RD surgery as it unfolded.

Pre-Gonin era (before 1920)

Although retinal break was known to be associated with RD, the focus was solely on RD with no attention to the causative break. Various theories were put forward and treatment was directed towards them. The first theory talked about RD as being spontaneous with the main culprit being abnormal leakage from choroid. Breaks in retina were thought as a result of increased pressure from fluid generated behind the retina. This led to treatments in the form of scleral and retinal puncture to relieve the pressure. Various treatments were directed towards draining the subretinal fluid (SRF) only to meet with obvious failure. A combination of SRF drainage along with the idea to induce retinopexy was probably introduced for the first time by Fano in 1866.¹ He induced chemical retinopexy in the form of injection of iodine solution into the subretinal space to achieve a chemical reaction. Apart from chemical retinopexy, other modalities employed were galvanocautery, pioneered by Deutschmann.¹

The second theory prevalence in this era saw a role of hypotony and associated circulatory alterations as the cause of RD. Various treatments were put forward to counter the same. Injection of materials like rabbit vitreous and gelatin to increase the intraocular pressure were attempted. Lagrange introduced a procedure known as ‘colmatage’ whereby intraocular pressure was increased by applying three rows of scleral cautery in a circumferential manner in order to increase hydrostatic pressure in the retina.¹ Various

osmotic agents were also injected into the subconjunctival space in the hope of reduction of SRF. These included saline, gelatin, cane sugar, glycerine and mercury salts.

A ray of hope appeared when Leber and Nordenson² put forward their theory of vitreous traction in the genesis of RD. They postulated that the alterations in vitreous generated secondary traction on the equatorial retina forming retinal tears with RD. This concept was of paramount importance as we know today but alas it met with severe resistance and criticism. Treatment aiming to relieve vitreous traction was introduced by likes of Deutschmann (who did the same by using Von Graefe knife).

Various non-surgical manoeuvres were also employed. Samelsohn¹ insisted on bilateral compression bandages with bed rest with idea of increasing intraocular pressure. Dietary modifications with salt restriction were another treatment on offer.

Jules Gonin and methods of retinopexy

Jules Gonin (1870–1935) legacy in history of RD dares to show how ones persistence and perseverance can change an idea. Taking Leber and Nordenson’s idea ahead with two decades of experimentation and self-belief, Gonin proved the role of retinal break in the pathogenesis of RD. He introduced a procedure called as ‘Ignipuncture’ whereby retinal breaks were painstakingly localized pre- and intraoperatively (not an easy task in those days). Under local anaesthesia, subretinal space was entered after making a radial scleral incision near the causative break and SRF was drained. Thermocautery was then introduced to create a retinopexy. In 1931, Gonin published his series of 221 patients who underwent ignipuncture with a success rate of 63%.³ Gonin’s theory of primarily treating the break was cemented when his disciples namely Amslers, Weve and Arruga⁴ reported similar success in their operations.

In the coming decades, various modifications of retinopexy were developed to treat the retina surrounding the causative break. The use of chemical cauterization for retinopexy in the form of potassium hydroxide after creating holes in sclera (trephining) was introduced by Guist and Lindner¹ in 1931. Diathermy was introduced by Larsson, Weve and Safar. It was used either on the bare sclera (surface diathermy) or after trephining the sclera (penetrating diathermy). Drainage of SRF was performed along with diathermy. This

procedure was commonly employed for around two decades. Complications of diathermy in the form of thinning and perforation led to search of other modalities for retinopexy. Electrolysis was reintroduced by Imre in 1932, but was seen to be less effective when compared with diathermy; hence never became popular. Although cryotherapy was introduced by Deutschmann and Bietti, the credit for its current use goes to Harvey Lincoff and Amoils who made its use easy by creating a specially designed cryo-probe with use of liquid nitrogen. The use of light for retinopexy was also being studied with the first human use by Moran-Sales, although their results were published after Meyer Schwickerath. Dr Schwickerath initially used sunlight, then carbon arc and finally krypton for retinopexy. Ruby laser and then argon laser became available with first report of its use in 1969 by L'Esperance.

Evolution of the indirect ophthalmoscope¹

The introduction of ophthalmoscope by Helmholtz in 1850 was the stepping stone to the current indirect ophthalmoscope of the modern era. Ruete was the first to introduce indirect viewing of retina with his monocular indirect ophthalmoscope. The first binocular indirect ophthalmoscope was devised by Giraud Teulon, which was a hand-held model developed in the nineteenth century. Charles Schepens devised the first clinical head mounted an indirect ophthalmoscope in 1947. Four years later, a modified version was introduced by Schepens who incorporated the light source and viewing system on the headband as we know it today. He also described the use of scleral depression which historically was first described by Trantas in 1900, although he used his thumb-nails for doing so.

Localization of retinal breaks as put forward by Gonin was tiresome and needed hours of training and patience. Various methods were described for localization of breaks, most of which relied on major anatomical landmarks and their distances from the break. Amsler and Dubois were first to devise a fundus chart for mapping extent of RD and its causative break in 1928. A combination of ophthalmoscopy and perimetry was also used for the same first described by Lindner.

Evolution of scleral buckling

Shortening of globe by scleral resection was the first step towards scleral buckling although the initial idea was globe shortening and not supporting the break. Creating an inward ridge for supporting break was initially achieved either by full or partial thickness scleral resection with SRF drainage and putting mattress sutures across the defect. The techniques were laborious and dangerous with high complication rates. In view

of the same, scleral surgeries without tissue excision were attempted. Weve's reefing procedure by placing lamellar suture bites, scleral outfolding and infolding techniques was some of these.

The first 'accidental' temporary scleral indentation during scleral buckle was done by Jess in 1937¹ where a cotton swab was used for the purpose to counteract hypotony secondary to SRF drainage. The first scleral buckling procedure using an episcleral exoplant was performed by Ernst Custodis in 1949.¹ He used a material made of polyviol and postulated a non-drainage surgery and advised reoperation if SRF failed to clear in 4 days. Charles Schepens⁵ gets the credit for doing the first scleral buckling surgery in the USA in 1951. He popularized segmental and encircling bands made of polyethylene tubes and used the same after making lamellar scleral flaps. Complications secondary to polyethylene tubes led Schepens to introduce the silicone rubber implants in 1960. It was Brockhurst in 1965 who introduced the scleral buckle procedure done worldwide for decades. His technique included lamellar scleral dissection, diathermy to the scleral bed followed by implant placement. The first use of non-absorbable sutures for scleral buckling was devised by Arruga in 1958.

It was Harvey Lincoff in 1965 who modified the original procedure by Custodis.¹ The changes included use of silicone sponge, use of improved scleral needles and use of cryotherapy instead of diathermy for retinopexy. Silicone sponges were used in a radial or circumferential fashion depending on the clinical scenario.

Evolution of vitrectomy and associated procedures

Ocular sustenance without vitreous was deemed impossible and its removal a crime. David Kashner with help of cellulose sponge and scissors performed the first vitrectomy (open sky) in a child with trauma on 28 July 1961⁶ and proved how an eye could survive without vitreous. Subsequently, he operated two cases with vitreous amyloidosis in 1967–1968 which cemented his theory. His pupil, Robert Machemer, performed the first pars plana vitrectomy in a patient of vitreous haemorrhage on 20 April 1970. He performed the same with help of VISC (vitrectomy, infusion, suction and cutter) developed by Jean Marie Parel. It was Connor O' Malley and Ralph Heinz⁷ who introduced a divided 20-G vitrectomy system called Ocutome 800 working on principle of pneumatic cutting. Gholam Peyman introduced the electric solenoid-driven guillotine cutter.

Steve Charles⁷ led the way in developing the vitrectomy machines. He was instrumental in developing the linear or proportional mode for the first commercial vitrectomy machine: Ocutome 800. Further on, he designed the ocular

connection machine (OCM), the forerunner for various vitrectomy machines like Accurus and Constellation. Dr Charles is also credited for developing fluid air exchange, flute needle, internal drainage of SRF and endophotocoagulation techniques. He was also instrumental in developing various scissor segmentation and delamination techniques. As success for treating simple rhegmatogenous RDs evolved, so did various instruments for complex RDs. Machemer with his bent needle technique and O'Malley with his pic forceps made peeling of membranes easier. End-grasping forceps by Steve Charles and diamond dusted membrane scrapper by Yasuo Tano were other innovative instruments which are still widely used today.

It was Ohm who gets credit for the first use of tamponade: although air in conjunction with RD surgery in 1911. This was then routinely adopted by Arruga⁸ and then Rosengren who was a leading figure in propagating the pneumoretinopathy. The use of sulphur hexafluoride (SF₆) as a tamponade agent was devised by Edward W.D Norton.^{1,4} Perfluorocarbon gas and its use in RD were introduced by Vygantas and Lincoff. Giant retinal tears and its complex treatment with nothing short of gymnastics being performed by the surgeon were eliminated with the introduction of perfluorocarbon liquids (PFCL). It was Haidt who first introduced PFCL in 1982 although Stanley Chang gets credit for making its use popular in treating complex RDs. Paul Cibis⁹ trained by Schepens himself was first to use silicone oil in RD surgery. However, he did not use it as a tamponade but as a tool to dissect preretinal membranes in cases with proliferative vitreoretinopathy. Interestingly, Paul Cibis was part of operation 'paper clip', a secret program offered by the government of USA to employ scientist and doctors from Germany after the World War II. It was Zivojnovic who pioneered the use of silicone oil and its use as a tamponade.

Early 21st century saw the introduction of the 25 gauge by Eugene Dejuan and then the 23-gauge system by Klaus Eckardt, making RD surgery less cumbersome and much faster with excellent results. The introduction of 27-gauge vitrectomy by Oshima has further made patient rehabilitation faster.^{7,10}

Viewing systems used during vitrectomy have also seen their share of evolution. From the initial days of Goldmann planoconcave lens and Landers lens system where peripheral vitreous was mostly untouched, various contact and non-contact wide-angled viewing systems have revolutionized the way we see and operate retina. The introduction of binocular indirect ophthalmomicroscope (BIOM) by Manfred Spitznas and its variants have greatly eased performing an RD surgery.

RD surgery in India

Looking into the evolution of RD surgery in India has proved to be more laborious than operating a complex RD. The following paragraph was formulated based on the inputs from eminent individuals in the field of vitreoretinal surgery in India as well as with help of old issues of *Indian Journal of Ophthalmology*.

Probably, the first person to start vitreoretinal services was Dr JM Pahwa from All India Institute of Medical Sciences (AIIMS), New Delhi (personal communication). However, literature search has not provided any concrete evidence of same. The same search showed Dr Bijayananda Patnaik from Maulana Azad Medical College publishing his results of scleral buckling in 100 cases in the year 1974.¹¹ Dr PK Khosla from AIIMS published their results of scleral buckling in 1977 followed by another one in 1981.¹² Another legend Dr DN Gangwar from Postgraduate Institute of Medical Education and Research, Chandigarh, published their results of scleral buckle in 1983.¹³

The first vitrectomy in India was done by Dr Gholam Peyman in a case of vitreous haemorrhage during a workshop in Madurai Medical College in 1974 (personal communication). Those attending this workshop were Dr. SS Badrinath of Sankara Nethralaya and Dr. P Namperumalsamy of Arvind Eye Care System; who later became the doyens in developing vitreoretinal surgery and trained many more who themselves became authorities.

It is ironic to say the least that we know so little of our past. We hope this rich history of ours gets unfolded too. RD surgery is still evolving and its history is a candid example of how persistence and perseverance of human endeavours can shape an idea. We conclude with following lines by Dr Charles Schepens.

"Never stop dreaming; what seemed impossible yesterday can become a reality tomorrow"

Acknowledgements We thank Dr Lingam Gopal and Dr Muna Bhende: Sankara Nethralaya, Chennai, Dr P Namperumalsamy: Arvind Eye Care System and Dr Pradeep Venkatesh: AIIMS for providing inputs in preparing the manuscript. We also thank Dr Abhinav Dhami: Senior Resident, Department of Vitreoretina, Sankara Nethralaya in providing materials for the above review.

References

1. Wilkinson CP, Rice TA. (1997) *Michels retinal detachment*, 2nd edn. Mosby, St Louis, MO, pp. 241-333.
2. Gloor BP, Marmor MF. Controversy over the etiology and therapy of retinal detachment: the struggles of Jules Gonin. *Surv Ophthalmol.* 2013;58(2):184-95.
3. Wolfensberger TJ, Gonin Jules. Pioneer of retinal detachment surgery. *Indian J Ophthalmol.* 2003;51(4):303-8.

4. Rezaei KA, Abrams GW. (2005) *Chapter 1: the history of retinal detachment surgery: primary retinal detachment: options for repair.*, 1st edn. Springer, pp. 1–25.
5. McPherson A. Charles Schepens 1912–2006. *Retina.* 2006;26(6): 597–98.
6. Blodi CF, Kasner David, MD, and the road to pars plana vitrectomy. *Ophthalmol Eye Dis.* 2016;8(Suppl 1):1–4.
7. Charles S. The history of vitrectomy: innovation and evolution. *Retina Today.* 2008:27–29.
8. Ascaso FJ, Grzybowski A. Hermenegildo Arruga (1886–1972): a versatile ophthalmologist who simplified cerclage to retinal surgery. *Acta Ophthalmol.* 2014;92(8):814–7.
9. Feibel RM, Blodi CF, Cibis Paul A., MD: a pioneer of modern vitreoretinal surgery. *JAMA Ophthalmol.* 2013;131(8):1077–82.
10. Nagpal M, Verma A, Goswami S. Micro-incision vitrectomy surgery past, present and future. *Eur Ophthal Rev.* 2015;9(1):64–8.
11. Patnaik B, Kalsi R. Retinal detachment (operative experience in hundred consecutive cases). *Indian J Ophthalmol.* 1974;22(1):25–9.
12. Khosla PK, Tewari HK, Garg SP. Aphakic retinal detachment. *Indian J Ophthalmol.* 1981;29(4):369–76.
13. Gangwar DN, Grewal SP, Jain IS. Retinal detachment surgery sine retinopexy. *Indian J Ophthalmol.* 1983;31(3):197–8.

How to cite this article Pal B.P. and Saurabh K. Evolution of retinal detachment surgery down the ages, *Sci J Med & Vis Res Foun* 2017;XXXV:3–6.

Evolution of retinal detachment surgery: The 'Firsts'

Albrecht von Graefe: first to notice and document a retinal tear

Herman von Helmholtz: first to introduce ophthalmoscope

James Ware: first attempt in treating retinal detachment in 1805

Jules Gonin: first to give retinal tear its due importance and attempts to treat the same

Giraud Teulon: first to introduce binocular indirect ophthalmoscope (hand-held) in nineteenth century

Charles Schepens: first to introduce head mounted indirect ophthalmoscope in 1947, first to introduce encircling silicone bands

Larsson, Weve and Safar: first to introduce diathermy

Ernst Custodis: first to use exoplant for scleral buckle in 1949

Deutschmann: first to introduce cryotherapy in 1933

Harvey Lincoff: first to introduce the modern cryounit for trans-scleral use

Moran Sales: first to use photocoagulation as a therapeutic modality in humans

Gerd Meyer Schwickerath: first to publish technique in use of therapeutic photocoagulation in 1949

L'Esperance: first to use argon laser as retinopexy in 1969

David Kashner: first to perform 'open sky vitrectomy'

Robert Machemer: first to perform pars plana vitrectomy on 20 April 1970 in a patient with vitreous haemorrhage

Anton Banko: first to develop vitrectomy probe having infusion and aspiration, although never commercialized it

Jean Marie Parel (along with Machemer): first to commercialize vitrectomy probe called as VISC (vitrectomy, infusion, suction and cutter), first to introduce operating microscope with X-Y movement

Jean Haut: first to use silicone oil in combination with pars plana vitrectomy in 1978

Conor O' Malley: first to introduce three-port 20-g pars plana vitrectomy

Gholam Peyman: first to introduce a separate endoillumination probe

Steve Charles: first to start internal drainage of subretinal fluid, fluid gas exchange, air-silicone oil exchange

OHM: first use of intravitreal gas (air) in 1911

Edward Norton: first to use iso-expansile gas (SF6) with retinal detachment surgery

Haidt: first to introduce perfluorocarbon liquids as vitreous substitute in 1982

Managing retinal detachment: tips for the beginners

Lingam Gopal

Consultant Emeritus,
Sri Bhagwan Mahavir
Vitreoretinal Services,
Sankara Nethralaya,
Chennai, India

Correspondence:

Lingam Gopal,
Consultant Emeritus,
Sri Bhagwan Mahavir
Vitreoretinal Services,
Medical Research Foundation,
Chennai, India

Introduction

In the portfolio of a vitreo-retinal surgical practice, management of retinal detachments occupies the premium position. The following serves as an introduction with a philosophical slant rather than as a detailed listing of the dos and don'ts.

Is it retinal detachment?

While most often the diagnosis of retinal detachment is straightforward, there could be confusion on occasions. Conditions that can be confused with retinal detachment are retinal oedema (as in Berlin's oedema), retinoschisis, choroidal detachment, thick vitreous membranes (as in Uveitis), altered blood, etc.¹ Evaluation should include careful slit lamp biomicroscopy, indirect ophthalmoscopy and where needed ultrasonography (even when there is view of some fundus details).

Is it rhegmatogenous retinal detachment?

In most cases, the rhegmatogenous nature of retinal detachment is obvious from the appearance of the retinal detachment as well as the presence of retinal break. There are, however, situations when this may not be that obvious. Chronic retinal detachments can, on occasion, have some tendency towards shifting fluid and can be confused with secondary retinal detachments. Retinal detachments in the milieu of uveitis can sometimes cause confusion since a retinal break can occur due to the traction caused by the vitreous membranes (due to uveitis) and can actually be rhegmatogenous in nature. If the break is not obvious, it may be wrongly treated with steroids and immunosuppression. Indicators as to the true nature of the problem are relatively quiet eye, undulations in retinal surface, extent of retinal detachment following Lincoff's rules, pigment in vitreous cavity, etc.

There are several instances of retinal detachments secondary to tumours such as melanoma having been subjected to scleral buckling. This error in judgment can occur especially, when the surgeon did not evaluate the eye in detail before surgery and relied upon the input from less experienced personnel. This is one instance where ultrasonography is valuable in the presence of clear media.

Discussion with patient/relatives

In the discussion with the patient, it is important one is able to indicate broadly the approach to surgery, the expected success in terms of reattachment of retina, the expected recovery of vision if

surgery is successful, any limitations in travel, risks of surgery including risk of loss of existing vision, need for multiple surgeries (if anticipated), etc. The patients often misinterpret expression of percentage of success as the expected visual improvement. This can become very important while operating on eyes with chronic retinal detachments.

Planning the approach

There is no confusion in case of obviously complicated cases where in vitreo retinal surgery would be the only approach possible such as in cases of gross proliferative vitreo retinopathy, giant retinal tears, posterior retinal tears, macular holes with retinal detachment, colobomas with retinal detachment, vitreous haemorrhage with retinal detachment, etc.

In case of simple retinal detachments, the options one faces are between pneumatic retinopexy, scleral buckling and pars plana surgical approach. A lot would depend on one's training and individual discretion. The following guidelines may be helpful if one has an open mind to choose between the three options:

- a If choosing pneumatic retinopexy, note that the entire retina can be evaluated well with binocular indirect ophthalmoscope and scleral indentation to exclude additional retinal breaks, especially inferiorly. Even minimal vitreous haemorrhage or peripheral cortical cataract can interfere with proper visualization all round. Just because there is an obvious horse-shoe tear superiorly, does not mean there are no other less obvious breaks elsewhere. Failure to identify the additional breaks is the most common cause for failure of pneumatic retinopexy, unfairly blamed on new breaks/proliferative vitreoretinopathy (PVR), etc.
- b Avoid pneumatic retinopexy in relatively large breaks. Chances of sub-retinal migration of the bubbles are high.
- c Retinal detachments due to retinal dialysis are mostly managed with scleral buckling. There are several advantages to managing them with scleral buckling instead of performing vitreo-retinal surgery.
- d Retinal detachments clearly related to lattice degeneration with atrophic holes are again best managed with scleral buckling. Even eyes with some amount of intra-retinal and sub-retinal gliosis can do well with scleral buckle in these circumstances.

- e Pseudophakic eyes with retinal detachment caused by retinal tears (not atrophic holes) are best managed by pars plana route. The addition of encirclage is optional but avoided if possible.
- f The addition of encirclage to pars plana surgery would be preferred in eyes where vitreous cannot be closely shaved (as in phakic eyes), and inferior retinal breaks that could potentially lift up because of contracture of residual vitreous.
- g Choice of gas tamponade after vitrectomy: simple rhegmatogenous retinal detachments with superior breaks distributed in not more than one quadrant can be managed with short acting gases such as SF₆. Eyes with wider distribution of breaks or relatively inferior breaks are best managed with longer acting gases such as C₂F₆ or C₃F₈.

Importance of preoperative detailed evaluation

One cannot over emphasize the need for detailed preoperative evaluation. A detailed retinal drawing is optional but valuable, especially when scleral buckling is performed. The conditions during the surgery may not be as good as in the clinic from the perspective of indirect ophthalmoscopic visualization. In addition to the physical impediments caused by the operation theatre set up, trolleys and sterile draping, the cornea can become oedematous and the pupil may constrict causing sub-optimal visualization. The presence of a detailed drawing can function as an excellent road map to help localize the lesions under these circumstances. In addition, the act of performing a detailed retinal drawing forces the novice surgeon to become familiar with the retinal condition so well that surgical time can actually be shortened.

Issues that could potentially compromise the final outcome

- 1 Decision to do scleral buckling when the visualization is inadequate.
- 2 Attracted by one obvious large tear and missing the other tiny tears along the vitreous base.
- 3 DACE technique (Drain-Air injection-Cryo-Exopant) that has gone awry: too many bubbles of air that interfere with proper localization of break as well as appropriateness of the buckle location.
- 4 Not evaluating the location of the break vs. buckle relationship at conclusion (after drainage) and performing corrective measures if needed. In some cases, the break may fall just

at the edge of buckle and may not be adequately supported. If identified during surgery, what is needed is a small additional step of shifting the buckle posteriorly to avoid recurrences.

- 5 Not placing an adequately wide buckle: there is a general tendency to choose the buckles with narrow width (#276/277) since it makes it easier to place the mattress sutures. However, this choice should not be at the expense of inadequate coverage of the break. One should not hesitate to place a broader buckle such as #279 if needed.
- 6 Sub-retinal bleed at conclusion of SRF drainage: this is not an often-predictable problem. Contrary to intuitive thinking, significant bleeds can occur at conclusion of drainage even in younger age groups and in non-myopic eyes. Cauterization of the knuckle of choroid does not always prevent the bleed. Most significant bleeds occur at conclusion of drainage when the pressure is released suddenly, even before the sutures can be tightened. One way out can be to do controlled drainage. Drainage some amount—inject BSS—drain more and then tighten the buckle sutures. If despite the precautions bleed occurs and has migrated into sub-retinal space, one can inject a bubble of C₃F₈ and place patient prone to permit the blood to shift away from macula.
- 7 Inadequate cryo-induced chorio-retinal adhesion around the retinal break: this situation can arise when the retina in the area of break is highly elevated and the ice ball formed by the cryoprobe is not reaching the retina. Theoretically freezing the choroid-RPE complex should be enough to cause adequate chorio-retinal adhesion once the retina is reattached; however, due to the high degree of parallax, the freezing may not be under the edge of break—as desired.

One can supplement with postoperative laser as long as there is no fluid around the break.
- 8 Fish mouthing: this is not an uncommon complication after placing circumferential buckles for large horseshoe tears. Injecting a bubble of gas and positioning the patient can easily remedy this complication.

The use and misuse of silicone oil

In addition to more common indications such as severe PVR, coloboma-related retinal detachments, large giant retinal tears (180° and more), etc., one may have to use silicone oil in patients who cannot posture themselves, patients who need to

fly immediately after surgery, one eyed patients (for early visual rehabilitation), etc.

One should not take usage of silicone oil lightly. Once injected, we have committed the patient for at least one more surgery. The worry of facing a recurrent total retinal detachment after gas tamponade should not push novice surgeons to over use silicone oil. With use of silicone oil, we postpone the issues but do not get rid of them. Long-term complications are well known.² Shallow inferior retinal detachments may go unnoticed.

There is a tendency to postpone removal of silicone oil even when retina is well attached—for fear of facing possible recurrence after removal of silicone oil. Some surgeons keep convincing themselves that it is OK to leave the oil in till it causes complications. Some surgeons place silicone oil for inferior breaks, where gas tamponade with additional encirclage would have sufficed—just to avoid converting so-called suture less vitrectomy to a sutured one.

Adopting new techniques

Change is a constant phenomenon and this applies to the field of vitreo-retinal surgery as

well. Adopting a new technique does not mean one should forget an old technique, especially one as robust as scleral buckling. It is accepted that scleral buckling is less forgiving but the tendency to manage all cases of retinal detachment with the pars plana approach should be abhorred.

The new technique of using a 25-G chandelier light along with the wide-angle visualization system (BIOM) and performing scleral buckling has certain advantages.³ Unlike with indirect ophthalmoscopy, the image of the retina can be magnified making it easier to localize smaller lesions. The use of this hybrid technique may be the best way of bringing some of the young surgeons back to scleral buckling.

References

1. Bhomaj S, Khare C. Retinal detachment – in postgraduate ophthalmology. In Chaudhari Z., Vanathi M. (Eds). Chapter 12.11. Jaypee Highlights, New Delhi. p. 1255.
2. Federman JL, Schubert HD. Complications associated with the use of silicone oil in 150 eyes after retina-vitreous surgery. *Ophthalmology* 1988;**95**(7):870–6.
3. Temkar S, Takkar B, Azad SV, *et al.* Endoillumination (chandelier) assisted scleral buckling for a complex case of retinal detachment. *Ind J Ophthalmol.* 2016;**64**:845–6.

How to cite this article Gopal L. Managing retinal detachment: tips for the beginners, *Sci J Med & Vis Res Foun* 2017;**XXXV**:7–9.

Scleral buckling versus vitrectomy for primary rhegmatogenous retinal detachment

Aditya Maitray¹, V Jaya Prakash² and Dhanashree Ratra³

¹Fellow,
Sri Bhagwan Mahavir
Vitreoretinal Services,
Sankara Nethralaya,
Chennai, India

²Associate consultant,
Consultant,
Sri Bhagwan Mahavir
Vitreoretinal Services,
Sankara Nethralaya,
Chennai, India

³Senior Consultant,
Sri Bhagwan Mahavir
Vitreoretinal Services,
Sankara Nethralaya,
Chennai, India

Correspondence:
Dhanashree Ratra,
Senior Consultant,
Shri Bhagwan Mahavir
Vitreoretinal Services,
Medical Research Foundation,
Sankara Nethralaya,
Chennai, India.
Email: drdad@snmail.org

Introduction

Retinal detachment (RD) surgery is the most common retinal surgery performed. RD can be repaired either by scleral buckling (SB) or pars plana vitrectomy (PPV). Pneumoretinopexy, laser delimitation or observation can be done in selected cases. The decision to perform SB or vitrectomy depends on various factors, including age of the patient, duration and extent of RD, presence of proliferative vitreoretinopathy (PVR) changes, the number, location and size of retinal breaks and the lens status. Other factors which influence the decision are availability of operating room equipment or staff, various patient factors (especially expected compliance with positioning after surgery) and surgeon preference.¹ Until about a decade ago, SB was the preferred procedure, but there is a general trend towards vitrectomy with the development of newer technology. There are several retrospective and prospective studies which compare SB and vitrectomy for primary RD. The anatomical and visual outcomes following retinal reattachment surgeries reported in the recent peer-reviewed literature will be discussed in this article.

Scleral buckling

SB provides target-oriented retinal attachment. It is ideally suited for detachments with anterior retinal breaks and dialysis. It is also a very rewarding surgery for suitable paediatric RDs wherein PVD induction during PPV is a challenge. It is efficacious for both superior and inferior breaks, does not cause cataract, does not require postoperative positioning, unless gas or air is injected, and has a high single-surgery success rate (SSSR). Success rate can be further improved by meticulous preoperative and intraoperative search for breaks. Chandelier-assisted SB has also been described that can allow direct intraoperative visualization of peripheral retina under magnification.² On the other hand, patients with giant retinal breaks (GRTs), posterior breaks, PVR worse than grade B, thin sclera, glaucoma drainage device, previous strabismus surgeries and media haze (e.g. vitreous haemorrhage) precluding visualization of peripheral retina are not ideally suited for scleral buckling procedures and respond more favourably to PPV. The main reasons for failed buckle surgery are missed breaks, fishmouthing, inadequate buckling effect, development of new retinal breaks and PVR. The drawbacks with SB

include increased postoperative morbidity like pain and periorbital oedema, drainage-related complications like vitreoretinal incarceration, subretinal haemorrhage and choroidal detachment, diplopia due to muscle restriction, chorioretinal circulatory disturbances, refractive changes (typically axial myopia), epiretinal membrane formation, buckle intrusion, extrusion and infection. Subretinal fluid may take time to absorb in case of non-drainage procedure delaying anatomical recovery and resulting in poorer final visual outcomes.

Pars plana vitrectomy

The major advantage of PPV over SB is the improved internal search for breaks with microscopic visualization of peripheral fundus by scleral indentation and internal illumination. Other major advantage usually cited is the direct elimination of vitreous traction and removal of the vitreous leading to elimination of PVR-stimulating environment.³

It can help to clear media opacity, can address very posterior breaks and giant retinal tears and allow use of PFCL, internal drainage of subretinal fluid and intraoperative retinal attachment. With the development of improved visualization systems and smaller gauge surgical techniques, the success rate of vitrectomy has improved considerably. The potential problems with vitrectomy are the increased rate of cataract formation, iatrogenic breaks, requirement for postoperative positioning and higher cost.

Table 1 summarizes the basic differences between the two techniques. Based on the above differences between SB and vitrectomy, it is obvious that a few cases like localized detachment with single or neighbouring breaks are ideal for SB and complicated cases like PVR grade C or D, giant retinal tears, very posterior breaks and macular holes are better treated with vitrectomy. However, for a vast majority of cases that lie in between these two extreme scenarios, there exists some confusion regarding which surgical modality would give the best outcome. This group comprised about 30% of all primary rhegmatogenous RDs in the SPR recruitment study.⁴ Certain ambiguous cases which include patients with multiple breaks in different quadrants, bullous rhegmatogenous RDs, breaks extending central to the equator, breaks with marked vitreous traction and rhegmatogenous RDs with unclear hole situations

Table 1: SB versus PPV: comparison

	Scleral buckle	PPV
Mechanism of vitreous traction relief	Indirect/passive	Direct
Internal tamponade	Nil	Silicone oil/gas
Efficacy for superior/inferior breaks	Equal	Better for superior breaks
Efficacy in the presence of PVR > grade B	Less	Better
Postoperative morbidity*	More	Less
Postoperative positioning	Not required	Required
SSSR	90–95%	85–90%
Other advantages	Can support missed breaks Allows air travel Effective for retinal dialysis No cataract formation	Clears media opacities Effective for giant retinal tears, posterior breaks
Potential complications	Refractive changes Ocular motility disturbance Vitreoretinal incarceration Subretinal/suprachoroidal haemorrhage Migration/exposure of buckle elements Macular pucker	Cataract progression Raised intraocular pressure Iatrogenic breaks
Miscellaneous disadvantages		Moisture condensation on silicone IOLs during fluid–air exchange Restricted air travel in immediate postoperative period if gas tamponade used Expensive

*Pain and periorbital oedema in immediate postoperative period.

(no break or not all breaks could be identified on examination before surgery) require a lot of debate.

We searched PUBMED for the following terms: ‘retinal detachment’, ‘scleral buckle’ & ‘vitrectomy’ and finally analyzed recent relevant studies (published after year 2000) comparing SB and vitrectomy with minimum of 6 months mean follow-up and a minimum sample size of 30 eyes.

Outcomes

The most commonly reported anatomical outcomes in these comparative trials between SB and PPV for primary rhegmatogenous RDs include single-surgery success rate (SSSR: defined by most studies as an attached retina at final follow-up after a single surgery) and final anatomical success rate (defined as an attached retina at final follow-up after ≥ 1 surgical interventions). The functional outcomes studied include change in best-corrected visual acuity (BCVA, in terms of logarithm of the minimum angle of resolution [LogMAR] or Snellen’s acuity expressed as the proportion of study eyes achieving final vision better than 6/60 –6/18, depending on the study criteria). Apart from the surgical technique used, the visual acuity results may also be affected by several other factors like the presence or absence

of macular detachment, height and duration of macular detachment (DMD) and amount of pre-existing cataract. The other reported outcomes were the number of retinal procedures/reoperations, the redetachment rate and complications like postoperative PVR rate, raised intraocular pressure, epiretinal membrane and cataract development (in phakic patients).

Retrospective studies

Table 2 summarizes the recent retrospective comparative studies between SB and PPV for rhegmatogenous RD.

Most of the retrospective studies showed no difference in anatomical and functional outcomes between SB and PPV groups (table 2).^{5–13} However, Park *et al.* have reported that PPV might show better visual outcomes compared with SB in older phakic patients, the final anatomical outcomes still remaining comparable. This may be due to the presence of PVD and performing combined cataract surgery along with PPV whenever required.¹²

In pseudophakic eyes with uncomplicated RDs, initial and final anatomical outcomes have been reported to be better with PPV alone/PPV combined with SB compared with SB as per a meta-analysis of comparative retrospective studies

Table 2: SB versus PPV: retrospective studies

Study	Type of surgery	No. of eyes (follow-up)	SSSR (<i>p</i> *)	Visual outcome (<i>p</i> *)	Complications (<i>p</i> *)	Comments
Oshima <i>et al.</i> (2000) ⁸ , Primary uncomplicated macula off RD	SB	55 (24 months)	91% (final reattachment rate 100%)	0.42 LogMAR	iatrogenic breaks 4% Subretinal/vitreous bleeding 5% Cataract progression 12% ERM formation 7% PVR 3.8% Ocular hypertension 0	Preoperative VA, IOP and DMD best predictors of postoperative visual recovery in both groups PPV group had better visual recovery in patients with preoperative visual acuity <0.1, DMD >7 days and preoperative IOP <7 mmHg
	PPV	47 (24 months)	91% (final reattachment rate 100%)	0.45 LogMAR at 24 months (<i>p</i> =0.85)	iatrogenic breaks 4% (<i>p</i> =0.24) Subretinal/vitreous bleeding 2% (<i>p</i> =0.62) Cataract progression 64% (<i>p</i> <0.001) ERM formation 2% (<i>p</i> =0.37) PVR 4% (<i>p</i> >0.99) Ocular hypertension 2% (<i>p</i> >0.99)	
Miki <i>et al.</i> (2001) ⁹ , Uncomplicated RD from flap tears in superior quadrant	SB	138 (6 months)	92% (final 100%)		Initial failure in 11 eyes due to malpositioned buckle (seven eyes multiple tears and four posterior large flap tears) Subretinal haemorrhage 4.3% Penetrating suture 2.6% Ocular motility defect 5.1% ERM 2.2% PVR 0 Postoperative cataract 0	Eyes undergoing PPV+encircling band achieved 100% SSSR compared with eyes treated with PPV alone (86.3%). Vitrectomy appeared to have a better success rate 96.6% in case of multiple superior breaks compared with SB (69.9%) but not statistically significant
	PPV	87 (6 months)	92% (final 100%)	-	Initial anatomical failure in seven eyes (new tears five eyes, reopening of old tears in two) Subretinal haemorrhage 0 Penetrating suture 0 ERM 2.3% PVR 3.4% Lens trauma (6.9%) Iatrogenic breaks (9.2%) Postoperative cataract 20.7% (<i>p</i> <0.05)	
Huang <i>et al.</i> (2013) ¹⁰ , Macula off RDs	SB	32 (8 weeks)		Mean change in LogMAR 0.4± 0.8	ERM on SDOCT in 15.6%	Residual SRF at macula on SDOCT in 81.3% in SB group versus 19.2% in the PPV group at 8 weeks (<i>p</i> <0.05)
	PPV	26 (8 weeks)		Mean change in LogMAR 0.7± 0.8 (<i>p</i> <0.05)	ERM on SDOCT in 19.2% (1.0)	PPV faster for macular recovery in macula off RDs No difference in structural changes at macula on SDOCT between two groups
	SB			0.29–0.13 (<i>p</i> =0.001)		

Kobashi <i>et al.</i> (2014) ¹¹ , Uncomplicated RD		271 (6 months) 260 phakic, 11 pseudophakic	93.7% (final success rate 100%)		Needle perforation 0.4% Reopening of original break 3% New break causing redetachment 3.8% PVR 0.4% Macular pucker 0.4% CME 0.7% Choroidal detachment 0.7% Transient diplopia 0.7%	In the SB group, eyes with macula-off status associated with a lower success rate ($p=0.002$). Although break location and lens status had no significant effect on success rates in either group.
	PPV	271 (6 months) 228 phakic and 42 pseudophakic	96.3% (final success rate 100%)	0.68–0.14 ($p<0.001$)	iatrogenic breaks 7.7% Reopening of original break 2.2% New break causing redetachment 1.1% PVR 0.4% Macular pucker 0.7% CME 0.4% Pupillary block 1.1%	All phakic eyes in the PPV group underwent combined cataract surgery
Erakgun <i>et al.</i> (2014) ¹² , Uncomplicated RD with mild vitreous haemorrhage	SB	38 (6 months)	79%	0.55	Subretinal haemorrhage (5.2%) Macular pucker (7.8%) Cataract progression (13%) PVR grade B or worse (10.5%) Subsequent cataract sx (5.2%) Ocular hypertension 0	Phakic eyes with mild rhegma- related vitreous haemorrhage with visible peripheral fundus selected. SSSR better in the PPV group, final anatomical success 100% in both groups
	PPV	40 (6 months)	95% ($p=0.03$)	0.6 ($p=0.9$)	iatrogenic breaks (10%) Macular pucker 5% (0.6) Cataract progression 35% (0.02) Lens damage (5%) PVR grade B or worse 5% (0.4) Cataract sx 20% Ocular hypertension 2.5%	BCVA at 3 months better in the PPV group but similar in two groups at 6 months
Rush <i>et al.</i> (2014) ¹³ , Medium complexity RD	SB	121 eyes (6 months)	87.6%	65.12% $\geq 20/40$		No difference in overall outcomes between different techniques.
	PPV	444 eyes C3F8/SF6 tamponade (6 months)	81% for PPV ($p=0.2$) 89.7% for PPV +SB combined	54.4% in PPV and 48.2% in PPV/SB $\geq 20/40$ 40 ($p 0.21$)		No difference in anatomical ($p 0.11, 0.78$) or visual outcomes (0.63, 0.55) with the three techniques between phakic and pseudophakic lens status
Stamenković <i>et al.</i> (2014) ¹⁴ , Uncomplicated RD	SB	68 eyes (6 months)	76.5%	From 1.89 \pm 1.04 to 0.98 \pm 0.70 LogMAR ($p 0.04$)		Better anatomical outcomes in the PPV group.
	PPV	30 eyes (6 months)	100% (<0.05)	From 2.56 \pm 0.67 to 1.31 \pm 0.74 LogMAR ($p 0.001$)		Both groups showed significant visual improvement

Table 2: Continued

Study	Type of surgery	No. of eyes (follow-up)	SSSR (<i>p</i> *)	Visual outcome (<i>p</i> *)	Complications (<i>p</i> *)	Comments
Park <i>et al.</i> (2015) ¹⁵ , Phakic uncomplicated RD, age >35 years	SB	72 eyes (6.9 months)	77.8%	1.38±0.87 to 0.51 ±0.48	Sustained submacular fluid in 38.6%	Final BCVA worse in the SB group (<i>p</i> 0.01) Primary success rate better in PPV. Final success rate 100% in both groups
	PPV	57 eyes (6 months)	94.7% (<i>p</i> =0.01)	1.84±0.97 preoperatively to 0.30 ±0.23 postoperatively	Sustained submacular fluid in 2.8% eyes (<i>p</i> <0.001)	
Cankurtaran <i>et al.</i> (2017) ¹⁶ , Pseudophakic RDs	SB	30 eyes (34 months)	73.3%	63.3% ≥ 2 line increase in BCVA		No difference between groups in primary or final anatomical or visual outcomes
	PPV	39 PPV+silicone pseudophakic RDs (32.6 months)	77%	69.2% ≥ 2 line increase in BCVA		
		32 PPV+C3F8 pseudophakic (33.7 months) RDs	81.2% (<i>p</i> 0.76)	87.5% ≥ 2 line increase in BCVA (<i>p</i> 0.4)		

**p*-value for difference in parameter in the PPV versus SB group.

Abbreviations: SSSR: single-surgery success rate; SB: scleral buckle; PPV: pars plana vitrectomy; RD: retinal detachment; PVR: proliferative vitreoretinopathy; ERM: epiretinal membrane; BCVA: best-corrected visual acuity; IOP: intraocular pressure.

Table 3: SB versus PPV: prospective studies

Study	Type of surgery	No. of eyes (follow-up)	SSSR (<i>p</i> *)	Visual outcome (<i>p</i> *)	Complications (<i>p</i> *)	Comments
Ahmadih et al. (2005) ¹⁷ , (pseudophakic and aphakic RDs)	SB	126 (6 months)	68.2%	0.96±0.68 Mean LogMar at 6 months	Macular pucker (22%) CME (6.3%) IOP rise early postoperative period (24.6%) EOM dysfunction 4%	Baseline features matched. 20G PPV, 20% SF6 tamponade in the PPV group
	PPV	99 (6 months)	62.6%	0.96±0.62 Mean LogMar at 6 months	Macular pucker (22.2%) CME (6.1%) IOP rise early postoperative period (26.3%)	Trauma, glaucoma, uveitis, AMD, DR, macular hole, GRT, PVR worse than grade B excluded No significant difference in anatomical and visual outcomes and complication rates Final attachment rate 85% in the SB group and 92% in the PPV group
Sharma et al. (2005) ¹⁸ , Pseudophakic primary rhegmatogenous RDs	SB	25 eyes (6 months)	76%	0.19±0.15 decimal acuity	<u>Intraoperative</u> Needle perforation 4% Retinal haemorrhage 8% <u>Early</u> Raised IOP 4% Choroidal detachment 8% <u>Late</u> ERM 16% CME 4% Buckle infection 4% Diplopia 4% PVR causing failure 20%	Final anatomical reattachment 100% in both groups. Better long-term visual and anatomical outcomes in PPV in pseudophakic RDs
	PPV	25 eyes (6 months)	84% (<i>p</i> 0.48)	0.28±0.12 (<i>p</i> 0.03) Decimal acuity	<u>Intraoperative</u> iatrogenic breaks 24% Retinal haemorrhage 4% <u>Early</u> Raised IOP 32% <u>Late</u> ERM 12% CME 4% PVR causing failure 4%	
Brazitikos et al. (2005) ¹⁹ , RCT	SB	75 eyes (1 year)	83%	0.4 LogMAR	Mean change in axial length at 1 year 0.95 mm Mean operating time 65.8 min (<i>p</i> =0.004)	PPV has less operative time, more accurate diagnosis of breaks and higher single-surgery reattachment rate with less postoperative axial length changes.

Continued

Table 3: Continued

Study	Type of surgery	No. of eyes (follow-up)	SSSR (<i>p</i> *)	Visual outcome (<i>p</i> *)	Complications (<i>p</i> *)	Comments	
Primary pseudophakic RRD, PVR ≤grade B	PPV	75 eyes primary pseudophakic RRD, PVR ≤grade B 20% SF6 for endotamponade (1 year)	94% (<i>p</i> =0.03)	0.33 LogMAR (<i>p</i> =0.26)	Undiagnosed breaks after surgery 7 New intraoperatively diagnosed breaks 8 Mean change in axial length at 1 year 0.33 mm (<i>p</i> =0.0001) Lower mean operating time 54.6 min (<i>p</i> =0.004) Undiagnosed breaks after surgery 0 (<i>p</i> =0.01) New intraoperatively diagnosed breaks 22 (<i>p</i> =0.004)	But similar final attachment rate with multiple surgeries: 96% in the SB group and 98.6% in the PPV group (<i>p</i> =0.37)	
	SB	31 eyes (6 months)	80.6%	From 1.48 (median) to 0.6 LogMAR		SB and PPV comparable in outcomes	
Azad et al. (2007) ²⁰ , Phakic eyes uncomplicated RD	PPV	30 eyes (6 months)	80%	From 1.78 (median) to 0.6 LogMAR	Cataract in 5 (17%)		
	SB	31 eyes (6 months)	80.6%	From 1.48 (median) to 0.6 LogMAR		SB and PPV comparable in outcomes	
Heimann et al. (2007) ²¹ , 'SPR study', RCT	Phakic eyes	SB	209 eyes (12 months)	63.6%	0.33	Cataract progression 45.8% PVR grade B or C 12.4%	Final anatomical success 96.7% and 96.6% in SB and PPV groups, respectively.
		PPV	207 eyes SF6 in primary Sx (12 months)	63.8% (0.97)	0.48 (0.005)	Cataract progression 77.3% (<0.0005) PVR B or C 16.4% (0.08)	Silicone oil used in revision surgeries in 9.1% in the SB group and 17.9% in the PPV group Benefit of SB with respect to BCVA improvement in phakic eyes
	Pseudophakic eyes	SB	133 eyes (12 months)	53.4%	0.46	PVR 22.6%	Final anatomical success 93.2% and 95.5% in SB and PPV groups, respectively (comparable).
		PPV	132 eyes SF6 in primary Sx (12 months)	72% (0.002)	0.38 (0.1)	PVR 15.2% (0.1)	Silicone oil used in revision surgeries in 21.8% in the SB group and 11.3% in the PPV group Better anatomical outcomes of PPV group in pseudophakic/aphakic groups

**P*-value for difference in parameter in the PPV versus SB group.

Abbreviations: SSSR: single-surgery success rate; SB: scleral buckle; PPV: pars plana vitrectomy; RD: retinal detachment; PVR: proliferative vitreoretinopathy; ERM: epiretinal membrane; RCT: randomized control trial; IOP: intraocular pressure.

Table 4: SB versus PPV: meta-analysis studies

Study	Type of surgery	No. of eyes (follow-up)	SSSR (<i>p</i> *)	Visual outcome (<i>p</i> *)	Complications (<i>p</i> *)	Comments
Arya et al. (2006) ¹⁴ , Uncomplicated pseudophakic RDs 'Meta-analysis'	SB	1579	Lower initial reattachment rates	Lower probability of final visual improvement compared with PPV/PPV+SB		Initial and final anatomical outcomes better with PPV/PPV+SB compared with SB. Final visual success highest with PPV+SB, followed by PPV alone, compared with SB. Undetected breaks, loss of capsular support and macular detachment found to be significant negative predictors of primary success rate.
	PPV	457	OR 1.69 [95% CI 1.07–2.68]	Higher probability of visual improvement than SB [OR 2.34; 95% CI, 1.58–3.46]		
Sun et al. (2012) ²² , Meta-analysis of RCTs	Phakic	SB	76%	88.6% final visual success	PVR 10.3% Postoperative cataract 40%	Final anatomical success 97.3% both groups. SB is superior in terms of final VA and occurrence of postoperative cataract in uncomplicated phakic RRDs.
		PPV	76.9% (0.8)	79.6% final visual success (0.005)	PVR 15% (0.1) Postoperative cataract 69.6% (0.00001)	
	Pseudophakic	SB	68.8%	86.7% final visual success	PVR 21.2%	Final anatomical success 91.1% in the SB group versus 95.5% in the PPV group (<i>p</i> 0.04)
		PPV	78.2% (0.16)	90.5% final visual success (0.19)	PVR 17.8% (0.4)	PPV is more likely to achieve a favourable final reattachment in pseudophakic/aphakic RRDs.

**P*-value for difference in parameter in the PPV versus SB group.

Abbreviations: SSSR: single-surgery success rate; SB: scleral buckle; PPV: pars plana vitrectomy; RD: retinal detachment; PVR: proliferative vitreoretinopathy; ERM: epiretinal membrane; RRD: rhegmatogenous retinal detachment.

by Arya *et al.*⁵ (table 4). Final visual success was highest when PPV was combined with SB, followed by PPV alone, compared with SB. Undetected breaks, loss of capsular support and macular detachment found to be significant negative predictors of primary success rate in these pseudophakic RDs.

Even in eyes with mild vitreous haemorrhage (where peripheral fundus can be adequately visualized), Erakgun *et al.* found that though the initial visual outcome was better in the PPV group, the final visual and anatomical outcomes (at 6 months) were comparable in both groups.

Various retrospective studies have also compared PPV alone and PPV with additional SB. Anatomical and functional success rates were better with the use of a scleral explant during PPV for uncomplicated forms of phakic rhegmatogenous RDs with inferior breaks.⁶ However, they seem to have similar efficacy in the repair of a matched group of patients with primary non-complex pseudophakic RD.⁷

Common complications in SB according to most studies were subretinal haemorrhage due to perforation, epiretinal membrane formation and delayed absorption of submacular fluid (in non-drainage procedures). In the PPV group, the incidence of cataract progression and lens damage, occurrence of iatrogenic breaks was significantly more common when compared with the SB procedure.

Retrospective studies suffer from the fact there may be severe selection bias as the decision to opt for a particular surgery is influenced by various other factors like preoperative findings, patient characteristics, available tools for surgery, and experience, ability and preference of the operating surgeon.

Prospective studies

There are relatively limited number of prospective studies that compare outcomes of SB and PPV (Table 3).

In phakic eyes, most prospective studies have found better visual outcomes with SB when compared with PPV for uncomplicated RDs, although the final anatomical outcomes may be similar in both groups.^{20,21} This can be explained by the higher incidence of cataract progression and difficulty in adequate vitreous base excision during vitrectomy.

In pseudophakic eyes on the other hand, PPV is more likely to achieve a favourable anatomical outcome, though there was not much difference in final visual outcomes.^{17-19,21} The main issue in pseudophakic/aphakic eyes is the difficulty in preoperative visualization as the breaks are usually small and multiple, anterior and posterior capsular haze, cortical remnants, suboptimal dilatation and optical aberrations due to the IOL. Most studies

have attributed the lower anatomical success in the SB group to missed small breaks possibly due to poor visualization of periphery. SB has also been shown to be associated with a significant increase in axial length postoperatively compared with PPV.¹⁶

The SPR study

The Scleral Buckling versus Primary Vitrectomy in Rhegmatogenous Retinal Detachment Study (SPR Study)²¹ was the first large-scale, open-label prospective randomized multicentre clinical trial which compared SB surgery and primary PPV in rhegmatogenous retinal detachments of medium complexity with 1-year follow-up. It separated phakic and pseudophakic patients (parallel group design). Forty-five surgeons (who had to have performed at least 100 SB procedures and 100 PPVs as primary surgeons) from 25 centres in five European countries recruited 416 phakic and 265 pseudophakic patients. In the phakic arm, the mean BCVA change was significantly ($p=0.0005$) greater in the SB group (SB, -0.71 logMAR, standard deviation [SD] 0.68; PPV, -0.56 logMAR, SD 0.76). In the pseudophakic arm, changes in BCVA showed a non-significant difference of 0.09 logMAR. In phakic patients, cataract progression was greater in the PPV group ($p<0.00005$). In the pseudophakic group, the primary anatomical success rate (SB, 71/133 [53.4%]; PPV, 95/132 [72.0%]) was significantly better ($p=0.0020$), and the mean number of retina-affecting secondary surgeries (SB, 0.77, SD 1.08; PPV, 0.43, SD 0.85) was lower ($p=0.0032$) in the PPV group. Re-detachment rates were 26.3% (SB, 55/209) and 25.1% (PPV, 52/207) in the phakic trial and 39.8% (SB, 53/133) and 20.4% (PPV, 27/132) in the pseudophakic trial. The study showed a benefit of SB in phakic eyes with respect to BCVA improvement. No difference in BCVA was demonstrated in the pseudophakic trial; based on a better anatomical outcome, PPV was recommended in these patients.

Meta-analysis

Table 4 summarizes the results of two large meta-analyses of studies comparing SB with PPV.

The results of different studies cannot be compared together as the surgical techniques may be different, for example combining cataract surgery with vitrectomy in phakic patients might improve the visual acuity results, use of additional SB/encirclage, use of 360° endolaser and the use of gas or oil for tamponade in vitrectomy may change the rate of re-detachment and anatomical prognosis. The decision to drain or not in SB may also affect the complication rates and final outcomes.

It is also important to note that most prospective and retrospective studies comparing PPV with SB have employed gas as primary tamponade

(SF6/C3F8) for PPV. Silicone oil was used only in cases of recurrent detachments. In clinical practice, it is not uncommon to use silicone oil as the primary tamponading agent during PPV for rhegmatogenous RDs. Silicone oil and its associated complications can also have an impact on final visual and anatomical outcomes of PPV.

Furthermore, most of these studies have used traditional 20G systems for PPV. In the current scenario, small gauge vitrectomy and microincision vitrectomy systems (MIVS) have become the norm, with improved outcomes and reduced complication profiles which should be taken into consideration during these comparisons.

Conclusions

The controversy still continues and debate can go on regarding the efficacy of both these surgical procedures as a primary form of repair for RD. Many retrospective and prospective studies have shown nearly equal SSRs, anatomical success rates and functional outcomes in SB as well as PPV. In general, SB remains the method of choice in uncomplicated retinal situations, i.e., single breaks and/or a limited RD. In contrast, PPV is indicated in complicated situations. However, the decision to choose one particular type of surgery has to be individualized to that particular case scenario. It would also depend on the surgeon's preference and comfort with a particular technique. SB, although an old technique still holds good and can give excellent results if performed well. It would be advisable for the young retina surgeons to acquire this skill set.

References

- Schwartz SG, Mieler WF. Management of primary rhegmatogenous retinal detachment. *Comp Ophthalmol Update* 2004; 5:285–94.
- Nam KY, Kim WJ, Jo YJ, et al. Scleral buckling technique using a 25-gauge chandelier endoilluminator. *Retina* 2013;33(4):880–2.
- SPR Study Group. View 2: the case for primary vitrectomy. *Br J Ophthalmol*. 2003;87:784–7; McLeod D. Is it time to call time on the scleral buckle? *Br J Ophthalmol*. 2004;88:1357–9.
- Feltgen N, Weiss C, Wolf S, et al. Scleral buckling versus primary vitrectomy in rhegmatogenous retinal detachment study (SPR Study): recruitment list evaluation. Study report no. 2. *Graefes Arch Clin Exp Ophthalmol*. 2007;245:803–9.
- Arya AV, Emerson JW, Engelbert M, et al. Surgical management of pseudophakic retinal detachments: a meta-analysis. *Ophthalmology* 2006;113(10):1724–33.
- Chanana B, Azad R. Pars plana vitrectomy versus combined scleral buckling–pars plana vitrectomy for phakic rhegmatogenous retinal detachment with inferior breaks. *Open J Ophthalmol*. 2016;6:129–35.
- Weichel ED, Martidis A, Fineman MS, et al. Pars plana vitrectomy versus combined pars plana vitrectomy–scleral buckle for primary repair of pseudophakic retinal detachment. *Ophthalmology* 2006;113:2033–40.
- Oshima Y, Yamanishi S, Sawa M, et al. Two-year follow-up study comparing primary vitrectomy with scleral buckling for macula-off rhegmatogenous retinal detachment. *Jpn J Ophthalmol*. 2000;44(5):538–49.
- Miki D, Hida T, Hotta K, et al. Comparison of scleral buckling and vitrectomy for retinal detachment resulting from flap tears in superior quadrants. *Jpn J Ophthalmol*. 2001;45(2):187–91.
- Huang C, Fu T, Zhang T, et al. Scleral buckling versus vitrectomy for macula-off rhegmatogenous retinal detachment as assessed with spectral-domain optical coherence tomography: a retrospective observational case series. *BMC Ophthalmol*. 2013;13:12 doi: .
- Kobashi H, Takano M, Yanagita T, et al. Scleral buckling and pars plana vitrectomy for rhegmatogenous retinal detachment: an analysis of 542 eyes. *Curr Eye Res*. 2014; 39(2):204–11.
- Erakgun Tansu, et al. Scleral buckling versus primary vitrectomy in the management of retinal detachment associated with mild vitreous hemorrhage. *Turk Oftalmoloji Dergisi*. 2014;44(2):92–7. 6p
- Rush R, Simunovic MP, Sheth S, et al. 23-Gauge pars plana vitrectomy versus scleral buckling versus combined pars plana vitrectomy–scleral buckling for medium-complexity retinal detachment repair. *Asia Pac J Ophthalmol*. 2014;3(4):215–9.
- Stamenković M, Stefanović I, Senčanić I, et al. Morphological and functional outcome of scleral buckling surgery compared to primary vitrectomy in patients with retinal detachment. *Vojnosanit Pregl*. 2014;71(10):920–4.
- Park SW, Kwon HJ, Kim HY, et al. Comparison of scleral buckling and vitrectomy using wide angle viewing system for rhegmatogenous retinal detachment in patients older than 35 years. *BMC Ophthalmol*. 2015;15:121.
- Cankurtaran V, Citirik M, Simsek M, et al. Anatomical and functional outcomes of scleral buckling versus primary vitrectomy in pseudophakic retinal detachment. *Bosn J Basic Med Sci*. 2017;17(1):74–80.
- Ahmadieh H, Moradian S, Faghihi H, et al. Anatomic and visual outcomes of scleral buckling versus primary vitrectomy in pseudophakic and aphakic retinal detachment: six-month follow-up results of a single operation—report no. 1. *Ophthalmology* 2005;112(8):1421–9.
- Sharma YR, Karunanithi S, Azad RV, et al. Functional and anatomic outcome of scleral buckling versus primary vitrectomy in pseudophakic retinal detachment. *Acta Ophthalmol Scand*. 2005;83(3):293–7.
- Brazitikos PD, Androudi S, Christen WG, et al. Primary pars plana vitrectomy versus scleral buckle surgery for the treatment of pseudophakic retinal detachment: a randomized clinical trial. *Retina* 2005;25(8):957–64.
- Azad RV, Chanana B, Sharma YR, et al. Primary vitrectomy versus conventional retinal detachment surgery in phakic rhegmatogenous retinal detachment. *Acta Ophthalmol Scand*. 2007;85(5):540–5.
- Heimann H, Bartz-Schmidt KU, Bornfeld N, et al. Scleral buckling versus primary vitrectomy in rhegmatogenous retinal detachment: a prospective randomized multicenter clinical study. *Ophthalmology* 2007;114:2142–54.
- Sun Q, Sun T, Xu Y, et al. Primary vitrectomy versus scleral buckling for the treatment of rhegmatogenous retinal detachment: a meta-analysis of randomized controlled clinical trials. *Curr Eye Res*. 2012;37(6):492–9.

How to cite this article Maitray A., Jaya Prakash V. and Ratra D. Scleral buckling versus vitrectomy for primary rhegmatogenous retinal detachment, *Sci J Med & Vis Res Foun* 2017;XXXV:10–19.

Rhegmatogenous retinal detachment: contribution of Sankara Nethralaya to literature

Rupak Roy¹ and Rajiv Raman²

¹Consultant,
Vitreoretinal Services,
Sankara Nethralaya,
Kolkata, India

²Senior Consultant,
Vitreoretinal Services,
Sankara Nethralaya,
Chennai, India

Correspondence:
Rajiv Raman, MS, DNB,
Senior Consultant,
Vitreoretinal Services,
Sankara Nethralaya,
Chennai, India

The management of acute retinal detachment has improved over the past two decades with patients experiencing better outcomes from surgical intervention for this potentially blinding ophthalmic emergency. The vitreoretinal (VR) team at Sankara Nethralaya, for last nearly four decades, has been involved in managing these challenging clinical situations. Owing to the large patient dataset, over the years, the group has published many peer-reviewed articles in scientific journals.

- This India-centric research could highlight patient-clinical characteristics related to simple and complex rhegmatogenous retinal detachment in Indian subcontinent.
- The evidences generated from these studies are now the preferred practice pattern in the management of these cases.
- The success and failure rates have helped us to counsel the patient, preoperatively.
- The understanding of reasons for success and failure of procedures have helped in choosing appropriate management for different clinical situation.

This article compiles these evidences and the take home messages from these studies which would help the clinicians in managing the patients in the best way 'Evidence-based medicine'.

Evidences regarding scleral buckle

A. Drainage of SRF during scleral buckle

We reported the complications of SRF drainage in 506 eyes which underwent scleral buckle and compared the complications in 49 eyes which had non-drainage.

Take home messages:

- Major and minor complications occurred in 31% of the wherein the subretinal fluid was drained and 4.0% in eyes wherein the fluid was not drained.
- The incidence of complications between the diathermy and cryotherapy groups was similar.
- The location of drainage site close to or away from the retinal break did not make a significant difference in the incidence of complication. Similarly, the drainage in the bed or outside the bed did not have any significance. Drainage was attempted in almost all

meridians though more often closer to horizontal meridian. There was no statistically significant difference in the incidence of complication in the upper half clock meridians compared with the lower half clock meridians.

- The aphakic patients were more vulnerable to complications during the release of subretinal fluid. There was no significant higher incidence of complications in myopes.
- When perforation was done, the complications occurred in 22% of eyes. The incidence increased with an increasing number of attempts at drainage of subretinal fluid reaching 90% in cases with more than four perforations, most of them were major complications.
- The retina was successfully reattached in 81% of the eyes operated. In spite of the development of drainage site complications, the retina was successfully reattached in 79% cases. The vision improved in 68%, maintained in 3% and deteriorated in 29% eyes.
- The failure to reattach retina occurred in 24.5% of the cases in which drainage site complications occurred compared with 18.5% in the uncomplicated cases.
- If buckle is placed properly even in cases where subretinal fluid is present at the conclusion of surgery, it tends to get absorbed and results in a higher success rate of anatomical reattachment. Whereas, even if the fluid is drained till dry if the surgical procedure is faulty, it does lead to failure of surgery.

B. Scleral buckle for RD: predictors for anatomical failure

We reported the anatomical results and predictors of anatomical failure in consecutive 601 eyes which underwent scleral buckle by a single surgeon.

Take home messages:

- Retinal reattachment rates after single surgery was 86% which increased to 90% after second surgery (revision buckle and pneumatic retinopexy).
- Preoperative factors which were significantly associated with anatomical failure included the presence of choroidal detachment, the presence

of significant vitreous opacification (due to vitreous haze and haemorrhage) and the presence of multiple lattices at varying distances from ora.

- Intraoperative risk factors for anatomical failure included buckle extent of >2 quadrants, and intravitreal injection of air or fluid.
- Postoperative factors associated with anatomical failure included the presence of sterile vitritis.
- There was no correlation between intraoperative complications and anatomical failure.
- Proliferative vitreoretinopathy was the most common reason for anatomical failure.

C. Scleral buckle: explant vs. implant

We report the comparison of patients undergoing primary scleral buckling who were randomized to the explant or implant technique.

Take home messages:

- No significant difference was found between the two groups for total duration of the surgery, complications, anatomical results, visual outcome and buckle height.
- For the one- to two-quadrant buckles, duration of the surgery up to the initiation of subretinal fluid drainage was found to be significantly shorter for the explant group.
- Serial ultrasonography showed significant reduction in buckle height over 6 months in both groups to an equal degree.

D. Locating the breaks

Take home messages

- Identification of the retinal breaks in a case of rhegmatogenous retinal detachment is perhaps the single most important step that dictates the success of the surgery.
- One must understand that more than one break is present in as many as 50% of eyes.
- One must realize that all retinal breaks are not obvious. In addition to the visualization difficulties caused by lens opacities, capsular remnants, intraocular lens deposits, non-dilating pupil, etc., one has to contend with the fact that some breaks may not be obvious despite good visualization of retina. The important causes include very tiny breaks, breaks located within areas of chorioretinal atrophy, breaks within a staphyloma, breaks covered by flimsy membranes or vitreous condensation and breaks in pars plana epithelium, seen especially in cases of post-traumatic retinal detachments.

- In the evaluation, one needs to stress the importance of good binocular indirect ophthalmoscopy with scleral depression. Slit-lamp biomicroscopy can help clear the doubt in case of suspicious lesions.

- Vitrectomy can be indicated in certain cases of failure to detect retinal breaks. If the retinal detachment is restricted posterior to the buckle and if even scleral depression fails to show any fluid on the buckle, it is most likely that there is a break posterior to the buckle only. Such a 'difficult-to-see break' is best identified during vitrectomy. A prospective examination can direct our suspicion to some areas, but definitive identification may not be possible. The high magnification of the operating microscope coupled with improved visualization caused by removal of opacities and membrane helps locate the break with ease and the phenomenon of 'Schleiren' can confirm the same.

- If primary vitreous surgery is being planned, there could be complacency in identifying preoperatively all retinal breaks in the belief that the breaks can be identified during vitrectomy. It is important to realize that treatment of all the retinal breaks is a must for the success of the surgery irrespective of whether it is a primary buckling or primary vitreous surgery is performed. Additional breaks can form due to traction on the vitreous base and ora serrata. Locating the breaks in the periphery can still be difficult intraoperatively. Very often, intraoperatively indirect ophthalmoscopy helps identify peripheral breaks, better even than a wide-angle viewing system, especially in the presence of crystalline lens. It is obvious that a diligent preoperative examination and identification of these breaks will make the job easier during surgery.

- It is of course a different matter if extensive proliferative VR is present. In these circumstances, the surgery would involve thorough cleaning of the entire retina. Peripheral iatrogenic breaks (accidental and deliberate) are fairly common during vitreous base excision.

- Hence, it may not be vital to identify all the breaks preoperatively. Having said that, one should still eschew cursory preoperative evaluation, which is akin to a 'General going to a war without adequate knowledge of the enemy'.

E. Massive submacular haemorrhage during scleral buckle

We reported a case who underwent scleral buckle for partial rhegmatogenous retinal detachment with a small dialysis at 3.30 meridian. While

passing the mattress suture, accidental globe perforation occurred. Fundus evaluation revealed a large amount of subretinal haemorrhage in the macular area. Pars plana three-port vitrectomy was done, a retinotomy was done to remove the subretinal blood and retina was attached using tamponade. At 6 months after oil removal, patient had a good functional recovery and attached retina.

Take home messages:

- Massive submacular haemorrhage as a complication of simple scleral buckling can be an indication of immediate vitrectomy and internal drainage of subretinal blood at the same sitting.
- This procedure greatly improves the post-operative visual recovery.

E. Clinical profile of patients undergoing scleral buckle removal surgery

We reported the clinical and microbiological profile of 101 patients undergoing scleral buckle removal(SBR) surgery.

Take home messages:

- Buckle exposure with clinical infection (79.41%) was the most common indication.
- Of the eyes which underwent surgery, 88.2% eyes were positive culture, 83.3% revealed single and 16.6% revealed multiple microorganisms.
- *Staphylococcus epidermidis* (41.2%) was the most common isolate. Fungus was isolated in 2.94% eyes.
- Globe perforation (13.7%) and recurrent retinal detachment (6.9%) were the commonest complications. Time gap between SBR and recurrent retinal detachment ranged from 15 days to 50 months (mean 12.2 ± 18.3 months).
- Most of the exposed scleral buckles developed clinical infection few months to years after surgery, ultimately requiring SBR. Recurrent retinal detachment after SBR may appear from few days to years later warranting a long-term follow-up.

Evidences regarding pneumatic retinopathy

A. Recurrent retinal detachment treated with pneumatic retinopathy

We reported 36 eyes with recurrent retinal detachment after failed scleral buckle who underwent pneumatic retinopathy.

Take home messages:

- Retinal reattachment was obtained in 69.4% after pneumatic retinopathy

- We identified two factors for failure: location of retinal break on the posterior slope or posterior to buckle and the extent of retinal detachment—more than two quadrants.
- Pneumatic retinopathy is an effective alternative to revision buckle or vitreous surgery, especially if the leaking breaks are located on the buckle.

B. Reporting a posterior extension of retinal break after pneumatic retinopathy

Take home messages:

- A patient underwent pneumatic retinopathy for partial rhegmatogenous retinal detachment sparing the macula.
- After reattachment of the retina, a radial, posterior extension of the retinal break developed, causing recurrent retinal detachment.
- Later, the patient underwent pars plana vitrectomy twice and attained reattachment of the retina. At the last follow-up, his visual acuity was 20/30.
- This report highlights the importance of pre-operative assessment of the VR relationship in eyes undergoing pneumatic retinopathy.

Evidences regarding vitrectomy in managing rhegmatogenous retinal detachment

A. Pars plana vitrectomy and buckling in management of complex rhegmatogenous retinal detachment.

We reported the importance of vitreous surgery in 65 cases of complex rhegmatogenous retinal detachment.

Take home messages:

- In cases with massive peri-retinal retraction, successful retinal reattachment was achieved in a third of cases. The location and type of the breaks and subsequent problems that occur are directly related to the type of perforation. About 60% of them had prior surgery for RD.
- Cases with vitreous haemorrhage and RD had better visual prognosis.

B. Histopathological study in silicone filled eyes

We reported the histopathological review of eight silicone oil filled enucleated eyes using light microscopy.

Take home messages:

- In all cases, silicone oil vacuoles, both free and incorporated within macrophages, were seen in all the retinal layers.
- Silicone oil vacuoles were seen in the optic nerve, choroid, retinal pigment epithelium, corneal stroma, iris and ciliary body stroma,

preretinal and subretinal membranes and retrocorneal membranes.

- Silicone oil migration could be seen in intraocular tissues as early as 2 months post-surgery.
- There was no definite histopathological correlation between the duration of tamponade and the distribution of silicone oil vacuoles.
- Silicone oil vacuoles were seen in the optic nerve in eyes with neovascular glaucoma. Chronic inflammatory reaction was observed in the retinal tissue in the vicinity of silicone oil vacuoles.

C. Reporting a rare occurrence of suprachoroidal collection of internal tamponade agents through a choroidal hole

- We reported two cases of significantly large choroidal holes following penetrating trauma that led to suprachoroidal migration of internal tamponading agents during repair of retinal detachments with proliferative vitreoretinopathy secondary to penetrating trauma.
- In the first case, choroidal hole was a direct result of the injury and was identified immediately after VR surgery which was done for traumatic retinal detachment with haemorrhagic choroidal detachment.
- In the second case, the hole occurred over a period of several months after the repair of traumatic retinal detachment with silicone oil tamponade. This was attributed to progressive fibrosis exerting traction on the bare choroid/retinal pigment epithelium.
- Choroidal hole significant enough to cause suprachoroidal migration of internal tamponading agents is a very rare complication seen in eyes with post-traumatic retinal detachment with proliferative vitreoretinopathy.

D. Retinal detachment secondary to ocular perforation during retrobulbar anaesthesia

We reported clinical characteristics and retinal breaks associated with rhegmatogenous retinal detachment secondary to accidental globe perforation during local infiltration anaesthesia in five highly myopic eyes.

Take home messages

- The location and type of the breaks and subsequent problems that occur are directly related to the type of perforation and whether or not the intraocular injection was given.
- In most cases, the accidental perforation would have occurred in large myopic eyes with or without equatorial staphyloma.

- Although the general direction of the path of the needle was considered correct. In such cases, the needle is likely to be parallel to the globe wall and cause multiple sewing machine type of breaks that are close to each other.
- These breaks are relatively large and oblong in shape. In contrast, a needle that has been introduced in a wrong direction is likely to strike at a more acute angle and exit posteriorly causing two widely separated breaks of oval shape.
- Depending on the direction, the posterior break can be present anywhere around the posterior pole or upper nasal quadrant.
- In accidental perforation during local anaesthesia, the scleral perforation is likely to be of a larger size compared with accidental perforations caused during subconjunctival or subtenon injection wherein 26-gauge or smaller needles are used.
- Hence, most of these cases are recognized immediately because of the sudden softening of the eye. If recognized, the surgeon should abort the intended surgery and seek the help of a VR surgeon for management.
- With rest, the vitreous haemorrhage may settle down permitting laser photocoagulation of the breaks. In the event of non-resolution of vitreous haemorrhage within 7–10 days, vitrectomy combined with intraoperative treatment of breaks is advocated. This approach is quite effective in the prevention of retinal detachment.

E. Anterior chamber collapse after VR surgery with gas tamponade in aphakic eyes

We reported the risk factors associated with the occurrence of anterior chamber collapse in aphakic eyes that underwent vitrectomy with gas tamponade. A total of 314 eyes of 314 patients who underwent vitrectomy with gas tamponade and who were aphakic or were made aphakic intraoperatively were studied prospectively.

Take home messages

- Anterior chamber collapse occurred in 3.14% eyes.
- The presence of preoperative shallow anterior chamber, removal of intraocular lens as a part of the procedure, occurrence of intraoperative anterior chamber collapse and use of sulfur hexafluoride (SF6) were associated with a higher risk of anterior chamber collapse postoperatively.
- The identification of potential risk factors in a given eye can alert the surgeon to the

possibility of the development of anterior chamber collapse postoperatively.

F. Primary vitrectomy for rhegmatogenous retinal detachment associated with choroidal detachment

We reported the success rate of primary vitrectomy, scleral buckling and oral steroids in eyes with combined rhegmatogenous retinal detachment (RRD) and choroidal detachment (CD) and compared these results with those reported in the literature for similar cases managed by scleral buckling alone.

Take home messages

- At mean follow-up of 11.4 months, retinal reattachment was attained in 90.5% eyes compared with less than 53% reported in the literature for scleral buckling alone.
- With preoperative oral steroids, choroidal detachment regressed completely in 61.9% eyes. In the remaining eyes with persistent choroidal detachment, suprachoroidal fluid was drained during vitrectomy.
- Aggressive treatment with oral steroids followed by pars plana vitrectomy and scleral buckling or encircling is recommended instead of scleral buckling alone in the management of combined primary rhegmatogenous retinal detachment and choroidal detachment.

G. Primary vitrectomy for combined rhegmatogenous retinal detachment with choroidal detachment with or without oral corticosteroids

The occurrence of CD in eyes with primary RRD is relatively uncommon (2–4.5%). Reports suggest that primary vitrectomy yields better anatomical success than scleral buckling. However, for these inflamed eyes with low intraocular pressure, the influence of preoperative oral steroids on reattachment rates had not been elucidated. We did a prospective study was undertaken to elucidate the exact role of preoperative oral steroids in anatomical and functional outcomes for eyes with combined CD and RRD

Take home messages

- Preoperative clinical data such as mean age, lens status, Snellen visual acuity, duration of macular detachment, CD (size and extent) and retinal detachment characteristics (e.g., extent, number of retinal breaks, atrophic or tractional retinal break, size of retinal break and location of retinal break) were similarly distributed in both groups.
- Single-operation anatomical success rate was 81.8% among those patients who received preoperative oral steroids and was 66.7% among those who did not receive preoperative oral steroids.

- After reoperation, anatomical success rate was 100% in both groups. The mean follow-up was 20.1 months.

H. Sympathetic ophthalmitis following vitrectomy

We reported the differences in the presentation and outcomes of sympathetic ophthalmitis (SO) in eyes with or without a history of antecedent penetrating trauma; SO being diagnosed after VR surgery. All Group I patients had received systemic steroids prior to presentation.

Take home messages

- Differences were observed between Group I and Group II mainly with regard to time interval between VR surgery and diagnosis of SO (1.5 vs. 8 months), the presence of neurosensory detachments (100 vs. 30%) and the inciting eye vision at presentation (nil light perception in 28.5 vs. 80%).
- Other differences observed though not statistically significant were optic disc and retinal vessel involvement (42 vs. 70%), Dalen–Fuchs nodules (localized vs. diffuse) and leaks on fundus fluorescein angiography (pin–head vs. pin–point leak).
- SO in patients with antecedent penetrating ocular trauma present early with the central serous chorioretinopathy-like picture. Prior use of systemic steroids might have a bearing on the differences in presentation and the visual acuities between the two groups.

Evidences regarding managing complex RRD

A. Clinical characteristics of retinal detachments in patients with Marfan syndrome and the surgical outcome of VR surgery

We described the clinical characteristics of retinal detachments in patients with Marfan syndrome and reported the surgical outcome of VR surgery.

Take home messages

- Characteristic findings included total retinal detachment in 75.5% eyes, atrophic holes in 45.3% eyes, more than four retinal breaks in 39.6%, pre-equatorial and post-equatorial breaks in 37.7% eyes, giant retinal tears in 11.3% eyes and proliferative vitreoretinopathy (posterior, anterior or both) in 17% eyes.
- In 56.6% eyes, retinal breaks were located only in the temporal half of the retina. Of the eyes with myopia, 54.2% had a myopic correction greater than 7 diopters.
- At the median follow-up of 10.7 months, complete retinal reattachment was obtained in 87.6% and 86.2% of patients undergoing scleral buckling (including additional procedures

such as vitrectomy) and vitrectomy surgery, respectively.

- In eyes with reattached retinas, a final visual acuity of 20/200 or better was obtained in 81% of the patients after scleral buckling and in 56% of the patients after vitrectomy surgery.
- Retinal detachment in Marfan syndrome is complete in 75% of the eyes. More than half (56%) the eyes had a retinal break only in the temporal half of the retina, and 83% had at least a break in the temporal half of the retina. Currently available VR surgical techniques result in successful reattachment of the retina in approximately 86% of the eyes.

B. Use of silicone oil in the management of complex retinal detachment—an Indian experience

This study reported the results and complications of temporary silicone oil tamponade that was used to treat complicated RD in 4488 eyes associated with multiple aetiologies. An eye was considered an anatomical success if there was a complete retinal reattachment or macular attachment. Functional success was defined as attainment of visual acuity of 5/200 or better.

Take home messages

- Overall, anatomical success was achieved in 73% of the eyes, and functional success, in 47%. After removal of silicone oil, recurrence of retinal detachment was observed in 9% of the eyes; a high percentage (70%) of eyes attained functional success. Postoperative cataract was observed in 65.3%, abnormal corneas in 21.3%, hypotony in 16.9% and glaucoma in 16.4% of the eyes.
- The overall anatomical success rate in eyes with primary or recurrent retinal detachment with PVR was 72 and 70%, respectively.
- In traumatic RD with or without PVR, anatomical success rate was achieved in 73–75% of eyes and functional success, in 43–50%.
- In GRT with or without PVR, after silicone oil tamponade, the retina was reattached in 75–79% of eyes and functional success was attained in 65–69% of eyes.
- In choroidal coloboma with RD, the overall, anatomical success rate was 82% and functional success, 66%.
- Despite the onset of complications related to silicone oil usage, a high rate of reattachment of the retina was observed following vitrectomy and silicone oil tamponade in the management of complex RD associated with multiple aetiologies.

C. Management options and outcomes after reoperations for recurrent retinal detachment in silicone oil-filled eyes

One hundred eighteen silicone oil-filled eyes with recurrent retinal detachment were managed with revision of vitrectomy with membrane surgery with or without silicone oil removal, just scleral buckling or both. Anatomical success rate was defined as complete reattachment of the retina, and functional success was defined as recovery of ambulatory visual acuity of 5/200 at the last follow-up (mean follow-up, 29.7 months).

Take home messages

- In 82.2% of the cases, proliferative vitreoretinopathy was responsible for recurrent retinal detachment in silicone oil-filled eyes.
- Reoperations without removal of the silicone oil were performed in 65.3% of the cases. Anatomical success occurred in 62.7% of the eyes, and functional success occurred in 52.5%.
- Silicone oil was removed in 59.5% of the eyes with retinal reattachment; the retina remained attached in 90.9% of the eyes.
- Predictors of poor anatomical success were the presence of posterior diffuse proliferative vitreoretinopathy and combined posterior and anterior proliferative vitreoretinopathy.
- Reoperations for recurrent retinal detachment in silicone oil-filled eyes were successful in nearly two-thirds of the cases, and over one half of the eyes recovered an ambulatory vision.

D. Surgical outcomes of patients of HIV on HAART who underwent surgery for CMV retinitis-related retinal detachment

We reported surgical outcomes in 40 eyes of 35 consecutive HIV-positive patients who underwent surgical repair for CMV retinitis-associated rhegmatogenous retinal detachment.

Retinal detachment surgery was performed once active retinitis subsided (average of 4–6 weeks). Total retinal detachment was observed in 45%, while 55% had subtotal retinal detachment. Macular detachment was seen in 87.5% eyes. Proliferative vitreoretinopathy was present in 37.5% eyes and epiretinal membrane was seen in 2.5% eyes. None of the eyes had received preoperative laser prophylaxis. All 40 eyes underwent vitrectomy with silicone oil injection (1500 mL).

Take home messages

- Redetachments on follow-up were seen in 30% eyes that were surgically managed, with 10% eyes having a persistent retinal detachment at final follow-up.

- Favourable anatomical outcome was achieved in 80% eyes with attached retina, clear media and controlled intraocular pressure.
- Of these, 37.5% eyes had silicone oil removal with no detachments on follow-up. The rest of the 42.5% eyes had silicone oil in situ.
- Favourable functional outcome (vision >3/60) was achieved in 57.5% eyes. The causes for poor vision in the rest were pale disc in 22.5% eyes, phthisis in 12.5% eyes and persisting retinal detachments in 10% eyes.
- Though anatomical outcomes have not changed from the pre-HAART era, but there has been an increase in favourable functional outcomes possibly due to effects of antiretroviral therapy.

E. Patterns of breaks and detachments in eyes with choroidal coloboma

We described the type of breaks in the diaphanous tissue that can lead to coloboma-related retinal detachments.

Take home messages

- In an eye with coloboma with RD, the coloboma may or may not be causative of detachment. On examination of fundus, with special attention to the margin of the coloboma, one can definitely segregate a group of eyes wherein the detachment does not extend at all inside the margin. The management does not differ from RDs in eyes without coloboma.
- Retinal detachments that extend into the colobomatous area always are associated with breaks in the diaphanous tissue.
- Three distinct types of breaks were identified within the coloboma. A. Breaks at the edge of the detachment inside the coloboma. B. Oval atrophic breaks and C. breaks in anatomical macula that was involved in the coloboma.
- Multiple breaks were common.

F. Management of retinal detachment with choroidal coloboma

Study 1: 17 eyes with retinal detachment secondary to retinal breaks in the colobomatous area were managed by vitrectomy procedures. Endodrainage was done through the break in the colobomatous area, with simultaneous fluid-air exchange. Endolaser photocoagulation was performed along the colobomatous margin posteriorly, while the anterior portion was treated by transscleral cryopexy. Silicone oil was then exchanged with air.

Take home messages

- In nine cases, the silicone oil had to be removed for complications such as emulsification, glaucoma and keratopathy; in three of these eyes, oil removal resulted in recurrent retinal detachment.
- At the 2-month follow-up visit, there was 100% anatomical success, and 12 eyes (70.6%) recovered visual acuity of 10/200 or better.
- Of the 11 eyes with follow-up of more than 6 months, in 9 (81.8%), the retina remained reattached at last-follow up, and in 6 eyes (54.5%), a visual acuity of 10/200 or better was obtained.

Study 2: 85 eyes of 81 patients with retinal detachments related to coloboma of the choroid underwent pars plana vitrectomy with internal tamponade using silicone oil (80 eyes) or perfluoropropane gas (5 eyes). Behaviour of the retina on fluid-air exchange was used to guide the further steps of surgery. Endolaser was performed along the coloboma border. Silicone oil was removed in 80% of eyes.

Take home messages

- When there was no identifiable break in the intercalary membrane, fluid-air exchange was used as a guide to further management.
- If a communication existed between the subretinal space and the subintercalary membrane space and onward into the vitreous cavity (by way of breaks in the intercalary membrane), then injection of air into the vitreous cavity, aided by mere suction of fluid from the ectatic colobomatous area, flattened the retina.
- If no such communication existed, the retina was seen to balloon around the coloboma. If the ballooned retina stopped short of the colobomatous border, it was inferred that the retinal detachment was not related to the coloboma and its management was directed accordingly to the peripheral break alone.
- If, however, the ballooned retina extended into the coloboma, then the coloboma could be contributing to the occurrence of the retinal detachment in addition to the peripheral break.
- Recurrent retinal detachment occurred in 16.3% of silicone oil-filled eyes and 60% of gas-filled eyes.
- After silicone oil removal, 15.6% of eyes had recurrent retinal detachment. After a mean follow-up of 13.4 months, 81.2% of eyes had attached retina and 69.4% recovered equal to or better than 10/200 visual acuity.

- Retinal detachment secondary to coloboma of choroid is treated best by pars plana vitrectomy along with silicone oil tamponade. Gas tamponade has limited indications. Clinical evaluation of the extent of retinal detachment within the colobomatous area and the behaviour of the retina on fluid-air exchange helps to understand the pathogenesis of the retinal detachment and plan a rational therapy.

G. A clinical and optical coherence tomography study of the margins of choroidal colobomas

Take home messages

We described the features at the margin of the choroidal colobomas as evaluated clinically and by optical coherence tomography (OCT).

- Histologically, there is no normal choroid, retinal pigment epithelium or retina overlying choroidal colobomas; rather, the overlying tissue is an extension of the retina called the intercalary membrane (ICM).
- In these patients, OCT showed that transition from normal retina to the ICM could be categorized as abrupt or gradual and also showed that the inner neurosensory retinal layers continued as the ICM, whereas the outer layers could not be traced beyond a point.
- In some cases with apparently attached retina, subclinical retinal detachments were identified along the margin of the coloboma.
- In cases with retinal detachment, OCT allowed for identification of the precise site of communication between the sub-ICM space and sub-retinal space at the locus minoris resistentiae.
- The margin of the choroidal coloboma, in some cases, showed the appearance of a hump owing to inward turning of the retinochoroidal layers with thickening of the layers at the margin.
- In small colobomas, OCT revealed the ICM thickness comparable to normal retina but showed structural alterations.
- Fundus lesions that were clinically labelled forme fruste of choroidal coloboma seemed to have normal retinal thickness and layering on OCT. In one patient, a temporal optic pit was associated with the forme fruste choroidal coloboma in one eye; the fellow eye had a typical choroidal coloboma.
- Optical coherence tomographic evaluation of the margins of choroidal colobomas helps in understanding the transition from retina to ICM, detects subclinical retinal detachments and aids in identifying the site of communication between the sub-ICM space and the sub-retinal space in eyes with retinal detachment.

H. Pneumatic retinopexy in a case of shallow detachment with choroidal coloboma

We reported the surgical outcome of pneumatic retinopexy in a patient with retinal detachment from a single break in the intercalary membrane of an eye with macula-sparing retinochoroidal coloboma. Pneumatic retinopexy with laser barrage to coloboma margin can achieve and maintain retinal reattachment in eyes with macula-sparing retinochoroidal coloboma with shallow SRF.

I. Rhegmatogenous retinal detachment following treatment for retinoblastoma

We reported the characteristics of rhegmatogenous retinal detachment that developed in nine children who underwent treatment for retinoblastoma and analyzed the outcome following VR surgery in such clinical settings.

Take home messages

- At the time of diagnosis of rhegmatogenous retinal detachment, retinoblastoma was regressed in 67% eyes. The retinal detachment involved less than two quadrants in 78% eyes and was caused by an atrophic break in seven eyes.
- Seven eyes underwent a non-drainage scleral buckling procedure. Three eyes underwent vitreous surgery; in two of these eyes, tumour excision along with retinectomy using melphalan infusion was performed and eventually silicone oil tamponade was used.
- Retinal reattachment was achieved in all eyes with eventual tumour control in seven eyes.
- Rhegmatogenous retinal detachment in treated eyes with retinoblastoma is usually caused by an atrophic retinal break. Retinal detachment can be repaired successfully in most eyes.

Conclusion

Vitreoretina is a unique specialty in which a mixture of both medical and surgical interventions are routinely performed. It is well known that randomized controlled trials (RCTs) are generally harder to conduct for surgical treatments and previous studies have shown that the proportion of evidence from RCTs was lower in surgical studies compared with studies in internal medicine. The India-centric evidences from the large dataset from South-India has provided evidence for managing rhegmatogenous retinal detachment.

References

1. Shah SJ, Badrinath SS. Release of subretinal fluid in retinal detachment surgery. *Indian J Ophthalmol.* 1979;27(4):79.

2. Sharma T, Challa JK, Ravishankar KV, Murugesan R. Scleral buckling for retinal detachment: predictors for anatomic failure. *Retina* 1994;14(4):338–43.
3. Gopal L, D'souza CM, Bhende M, Fogla S, Ratra D, Shetty NS, Sharma T, Shanmugam MP, Bhende P, Bhattu RR, Badrinath SS. Scleral buckling: implant versus explant. *Retina* 2003;23(5):636–40.
4. Gopal L. Locating the retinal break(s) in rhegmatogenous retinal detachment: the first step in successful management. *Indian J Ophthalmol.* 2001;49(3):149.
5. Gopal L, Badrinath SS. Massive submacular haemorrhage during scleral buckling—an indication for vitrectomy. *Asia-Pacific J. Ophthalmol.* 1994;6:18–20.
6. Kazi MS, Sharma VR, Kumar S, Bhende P. Indications and outcomes of scleral buckle removal in a tertiary eye care center in South India. *Oman J. Ophthalmol.* 2015;8(3):171.
7. Sharma T, Badrinath SS, Mukesh BN, Gopal L, Shanmugam MP, Bhende P, Bhende M, Shetty NS, Agrawal R. A multivariate analysis of anatomic success of recurrent retinal detachment treated with pneumatic retinopexy. *Ophthalmology* 1997;104(12):2014–7.
8. Sharma T. Posterior extension of retinal break following pneumatic retinopexy. *Ann Ophthalmol.* 2002;34(1):47–8.
9. Doshi H, Badhinath SS. Pars plana vitrectomy and buckling in management of complex rhegmatogenous retinal detachment. *Indian J Ophthalmol.* 1983;31(7):872.
10. Biswas J, Verma A, Davda MD, Ahuja S, Pushparaj V. Intraocular tissue migration of silicone oil after silicone oil tamponade: a histopathological study of enucleated silicone oil-filled eyes. *Indian J Ophthalmol.* 2008;56(5):425.
11. Gopal L, Mittal N, Verma A. Suprachoroidal collection of internal tamponading agents through a choroidal hole. *Indian J Ophthalmol.* 2008;56(2):149.
12. Gopal L, Badrinath SS, Parikh S, Chawla G. Retinal detachment secondary to ocular perforation during retrobulbar anaesthesia. *Indian J Ophthalmol.* 1995;43(1):13.
13. Gopal L, Nagpal A, Kabra S, Roy J. Anterior chamber collapse following vitreoretinal surgery with gas tamponade in aphakic eyes: incidence and risk factors. *Retina* 2006;26(9):1014–20.
14. Sharma T, Gopal L, Badrinath SS. Primary vitrectomy for rhegmatogenous retinal detachment associated with choroidal detachment. *Ophthalmology* 1998; 105(12):2282–5.
15. Sharma T, Gopal L, Reddy RK, Kasinathan N, Shah NA, Sulochana KN, Miriam KC, Arvind K, Ramakrishnan S, Sukumar B. Primary vitrectomy for combined rhegmatogenous retinal detachment and choroidal detachment with or without oral corticosteroids: a pilot study. *Retina* 2005;25(2):152–7.
16. Rishi E, Rishi P, Appukkuttan B, Walinjkar J, Biswas J, Sharma T. Sympathetic ophthalmitis following vitreoretinal surgery: does antecedent trauma make a difference? *Indian J Ophthalmol.* 2015;63(9):692.
17. Sharma T, Gopal L, Shanmugam MP, Bhende PS, Agrawal R, Shetty NS, Gopalakrishna M, Rao MK, Balusamy SU. Retinal detachment in Marfan syndrome: clinical characteristics and surgical outcome. *Retina* 2002;22(4):423–8.
18. Silicone Oil Study Group of Sankara Nethralaya. Use of silicone oil in the management of complex retinal detachment—an Indian experience. *Int Ophthalmol.* 2004;25(3):129–42.
19. Sharma T, Gopal L, Shanmugam MP, Bhende PS, Agrawal R, Badrinath SS, Samanta TK. Management of recurrent retinal detachment in silicone oil-filled eyes. *Retina* 2002;22(2):153–7.
20. Mathur G, Ratra D, Bhuibhar SS, Roy R. Clinical outcomes of retinal detachment surgery following cytomegalovirus retinitis in patients on highly active anti-retroviral therapy for acquired immune deficiency syndrome. *Ocular Immunol Inflamm.* 2015;23(5):400–4.
21. Gopal L, Badrinath SS, Sharma T, Parikh SN, Biswas J. Pattern of retinal breaks and retinal detachments in eyes with choroidal coloboma. *Ophthalmology* 1995;102(8):1212–7.
22. Gopal L, Kini MM, Badrinath SS, Sharma T. Management of retinal detachment with choroidal coloboma. *Ophthalmology* 1991;98(11):1622–7.
23. Gopal L, Badrinath SS, Sharma T, Parikh SN, Shanmugam MS, Bhende PS, Agrawal R, Deshpande DA. Surgical management of retinal detachments related to coloboma of the choroid. *Ophthalmology* 1998;105(5):804–9.
24. Gopal L, Khan B, Jain S, Prakash VS. A clinical and optical coherence tomography study of the margins of choroidal colobomas. *Ophthalmology* 2007;114(3):571–80.
25. Rishi E, Rishi P, Govindarajan MV. Pneumatic retinopexy for the treatment of shallow retinal detachment caused by a retinal break in the intercalary membrane of macula sparing retinoblastoma. *Retinal Cases Brief Rep.* 2016; 10(2):187–90.
26. Pal SS, Gopal L, Khetan V, Nagpal A, Sharma T. Rhegmatogenous retinal detachment following treatment for retinoblastoma. *J Pediatr Ophthalmol Strabismus.* 2010; 47(6):349–55.

How to cite this article Roy R. and Raman R. Rhegmatogenous retinal detachment: contribution of Sankara Nethralaya to literature, *Sci J Med & Vis Res Foun* 2017;XXXV:20–28.

Surgical implications in exudative retinal detachment

Suganeswari Ganesan¹ and Ekta Rishi²

¹Consultant, Sri Bhagwan Mahavir Vitreoretinal Services, Sankara Nethralaya, Chennai, India

²Senior Consultant, Sri Bhagwan Mahavir Vitreoretinal Services, Sankara Nethralaya, Chennai, India

Correspondence:

Suganeswari Ganesan, Consultant, Sri Bhagwan Mahavir Vitreoretinal Services, Sankara Nethralaya, Chennai, India. Email: drgsi@snmail.org

Background

Surgeries for retinal reattachment form the main stay of treatment for rhegmatogenous, tractional and combined retinal detachment. However, they do not form the first line of management in exudative retinal detachment. Massive exudative retinal detachment not responding to the conventional line of treatment or not permitting the performance of conventional line of treatment is chosen for surgical intervention. It is a mandatory prerequisite to identify the pre-existing factor that has been instrumental in the initiation of exudative retinal detachment (ERD).

Table 1: Causes of exudative retinal detachment

Choroidal causes:

- Idiopathic choroidal vascular hyperpermeability
CSCR
- Localized choroidal vascular hyperpermeability
Choroidal haemangioma
- Tumours of choroid
Choroidal melanoma
- Impaired outflow through sclera
Uveal effusion syndrome
- Inflammatory conditions of choroid and sclera
VKH syndrome
Sympathetic ophthalmitis
Posterior scleritis
- Ischaemia and altered choroidal hyperpermeability
Preeclampsia, malignant hypertension, disseminated intravascular coagulation, idiopathic polypoidal choroidal vasculopathy

Retinal causes:

- Retinal angiomatosis
- Coats' disease
- Retinal venous occlusive disease
- Retinal artery macroaneurysm
- Idiopathic frosted branch angiitis

Miscellaneous causes:

- Post-retinal reattachment surgery
- Post-laser therapy
- Post-cryotherapy

ERD occurs due to breakdown of the complex interactions of forces that maintain the normal apposition of the retina, RPE, Bruch's membrane and choroid (Table 1). Failure of these forces, due to various causes enlisted below, potentially could lead to formation of fluid under the neurosensory retina. Central serous chorioretinopathy (CSCR) known to be a very common cause for localized ERD either in stressed males or patients who are on steroid medication for various ailments are potentially at risk for CSCR. This variety of CSCR is described as typical and is treated with lifestyle modification, avoiding steroids in all forms; focal laser photocoagulation is done to leak identified on fundus fluorescein angiogram for extrafoveal leaks and photodynamic therapy (PDT)/micropulse diode laser for subfoveal leak.

When the fluid is non-resolving and retinal detachment is chronic and bullous, permanent damage to retinal pigment epithelium as well as outer retinal structures occurs and persistence of subretinal fibrin may lead to subretinal fibrotic scar formation. To avoid these complications, surgical intervention is planned after failure of conventional treatment. However, surgical treatment is never the first line of management in these conditions.

Surgical options

Drainage of subretinal fluid (SRF)

- External approach
- Internal approach

External approach

Methods of external drainage of SRF

- Scleral cut down and choroidotomy
Needle opening of choroid
Laser opening of choroid
- Needle aspiration
- 26-G trocar and cannula drainage by retraction

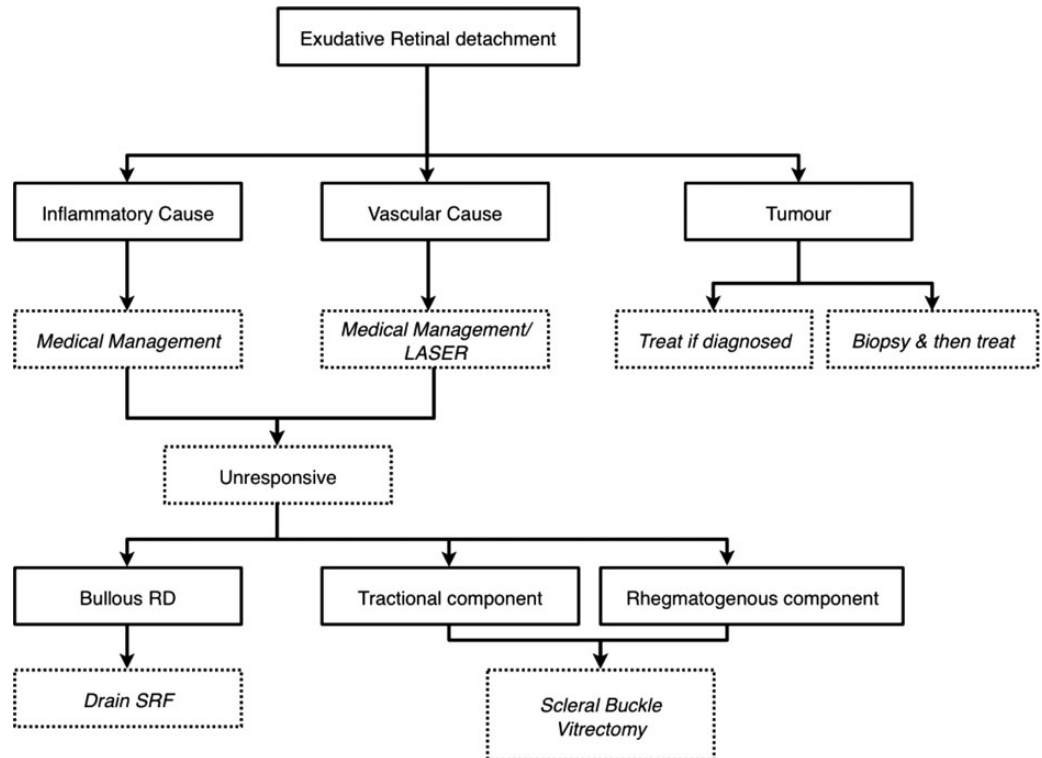
Steve Charles technique¹ of needle drainage is a relatively safer procedure can be combined with Chandelier illumination offers the comfort of using BIOM with the hands free for drainage of SRF under direct visualization and also allows surgeon to withdraw needle as the retina flattens avoiding complications like retinal incarceration, subretinal haemorrhage and vitreous loss. Continuous monitoring² with indirect ophthalmoscopy during the

drainage has also been reported to be free from complications.

Subretinal aspiration and injection device (SA-AID) introduced by Kang et al.³ to facilitate controlled external drainage of SRF. This device provides a safe approach to the subretinal space because it penetrates the eye wall obliquely and allows a changeable, predetermined length of the needle tip. The surgeon can also directly observe the retina with an indirect ophthalmoscope during the drainage.

Internal approach

- Pars plana vitrectomy with endodrainage through a drainage retinotomy, endolaser/cryopexy and tamponade with gas /silicon oil.
- Pars plana vitrectomy with liquid perfluorocarbon assisted external drainage.
- Pars plana approach endolaser without vitrectomy.



Pearls for external drainage

- External drainage done for bullous RD in periphery
- If using needle, bevel down will avoid retinal aspiration.
- Choroidotomy opening and needle can get occluded by sub retinal fibrin/cholesterol.
- AC maintainer may help for near complete drainage in selected situations.

Central serous chorioretinopathy

Longstanding CSCR can cause severe vision loss due to significant photoreceptor damage and later on may lead to subretinal fibrotic scar formation and foveal scarring (Figure 1).

Various authors have claimed to have good results via both external and internal drainage approaches of SRF in non-responding chronic CSCR.

Bondalapati et al.⁴ had reported external drainage of SRF in six male patients with ERD following chronic CSCR with no recurrences. External drainage was performed with 26-G needle (Steve Charles technique). Chandelier-assisted external drainage gives the advantage of keeping the surgeon's hands free to perform drainage. An external approach has been modified by various authors. Figueroa et al.⁵ performed sutureless sclerotomies beyond equator one in each inferior quadrant without SRF drainage followed by erect positioning. Retinal reattachment occurred within 24 h of surgery allowing focal laser photocoagulation to the leaking lesions on FFA. Good visual gain was recorded noted by the authors postoperatively with the interesting fact of nil surgical complications that were recorded.

Reasonable success rates were also claimed by authors⁶ who had done an internal approach by parsplana vitrectomy (PPV) with scleral buckle. Chen et al.⁷ suggested the use of liquid perfluorocarbon in a procedure which combined both PPV

and external drainage when SRF was present posteriorly. Liquid perfluorocarbon was used to attach the posterior retina while the SRF was drained via the external drainage and then applied diode laser to the area of leak. However, the visual outcome was poor which they attributed to long duration of macular detachment and subsequent subretinal fibrosis adjacent to the central retina. A similar observation was also made by Kang et al.⁸ who concluded that surgical treatment would be beneficial if performed early to prevent subretinal proliferation, which usually tends to have a negative influence on the final visual prognosis.

CSCR

- *CSCR usually is treated well with photodynamic therapy/laser/ micro pulse diode laser.*
- *Exudative detachment usually occurs due to a RPE rip which may heal in few months.*
- *All precipitating factors should be treated before resorting to surgical treatment*

Diffuse choroidal haemangioma

Diffuse choroidal haemangioma is a benign vascular tumour associated with cutaneous, ocular or central nervous system findings and may also be associated with Sturge-Weber syndrome. Diffuse red-orange thickening of the posterior choroid that has poorly defined borders and extends over a broad area.

Ultrasonography shows a diffusely thickened choroid on B scan, while A scan shows moderate to high internal reflectivity with an overlying SRF. Magnetic resonance imaging in T_1 -weighted images are hyperintense while it is isointense to the vitreous in T_2 -weighted images. Conventional therapy includes photodynamic therapy, external beam radiation therapy and oral propranolol. Shanmugam et al.⁹ in their unpublished data have treated a patient with diffuse choroidal haemangioma with bullous RD, resistant to conventional therapy with external drainage of SRF along with intraoperative transpupillary thermotherapy with good control of tumour and resolution of SRF.

Uveal effusion syndrome

Uveal effusion syndrome (UES) may be idiopathic or associated with abnormalities of choroid or sclera. It is basically a diagnosis of exclusion when all other causes are ruled out. Histological studies have demonstrated disruption of collagen fibers and filling of the interfibrillary spaces with amorphous glycosaminoglycan-like material obtained from the excised scleral tissue.

Gass¹⁰ hypothesized that abnormal thickness of the sclera could possibly compromise the choroidal vascularization, favouring the accumulation of extravascular proteins in the choroid and the

ciliary body and thereby increasing fluid migration into the suprachoroidal space producing a ciliochoroidal detachment with secondary movement of water and proteins into the subretinal space. Eye being devoid of lymphatics intraocular extravascular proteins are removed via Schlemm's canal and aqueous veins anteriorly while posteriorly by trans-scleral diffusion and through the emissary canals into the orbital tissues. Since increased thickness of the sclera was preventing the trans-scleral diffusion, partial thickness sclerectomies would help in successful reabsorption of subretinal fluid.

Posterior microphthalmos (PM) is an entity that has been very newly introduced to differentiate from nanophthalmos. Both have short axial length, except the fact that PM has normal corneal diameter while nanophthalmos has reduced corneal diameter. Clinical features reported in PM are reduced axial length with a normal-sized cornea and normal anterior segment and a disproportionately small size of the posterior segment. Other features reported are high hyperopia, uveal effusion, elevated papillomacular retinal fold, fine retinal striae, tapetoretinal degenerations similar to fundus flavimaculatus and fundus albipunctatus, retinoschisis, reduced foveal avascular zone, pseudopapilledema and macular holes.¹¹⁻¹⁵

Drainage of SRF is never successful as an independent procedure as it leads to higher chances of recurrences. The most common treatment performed is full-thickness sclerectomies to provide an exit for choroidal fluid, and this has been well supported in the literature by a large case series¹¹ which showed anatomical improvement in single procedure amounting to 83% and visual recovery of two or more lines in 56% of eyes.

Faulborn et al.¹⁶ described regression of SRF and resolution of choroidal detachment following pars plana full-thickness unsutured sclerectomies without sclerectomy in their series of five eyes of four patients with UES due to nanophthalmos.

Coats' disease

The most popular and widely used classification for Coats' disease is by Shields et al.¹⁷

Stage 1: Telangiectasia

Stage 2: Telangiectasia and exudation (2A extrafoveal exudation, 2B foveal exudation)

Stage 3: ERD (3A subtotal and 3B total)

Stage 4: Total retinal detachment and secondary glaucoma

Stage 5: Advanced end-stage disease

Multiple modalities have been employed to treat including diathermy, laser photocoagulation, cryotherapy, SRF drainage, scleral buckling surgery, pars plana vitrectomy and intravitreal anti-vascular endothelial growth factor (VEGF) therapy. Treatment is aimed at destroying abnormal vasculature and aneurysmal dilations.

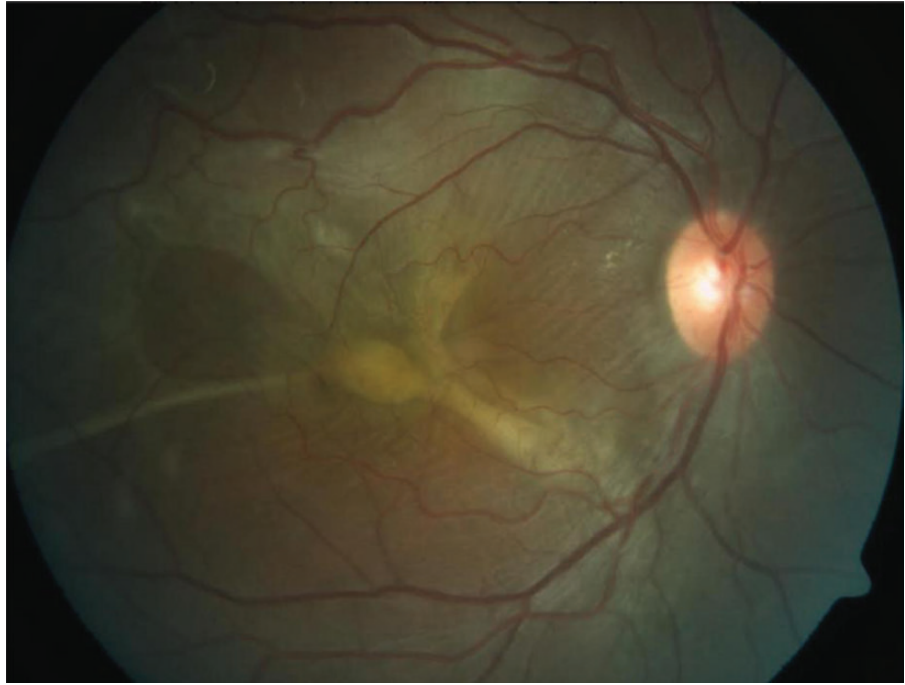


Figure 1: CSCR with subretinal fibrosis.

The surgical approach is contemplated at stages 3 and 4 as serous bullous retinal detachment that does not permit regular laser ablation or transconjunctival cryopexy of retinal vessel telangiectasias (Figure 2).

Interventional case series of 13 patients by Daniela et al.¹⁸ presented a modified surgical

technique in the treatment of retinal detachment secondary to advanced Coats' disease in children and reported on long-term anatomical and functional outcome. Their patients underwent PPV including exocryotherapy applied after fluid-air exchange in order to achieve complete treatment of the vascular changes, to reduce associated side-

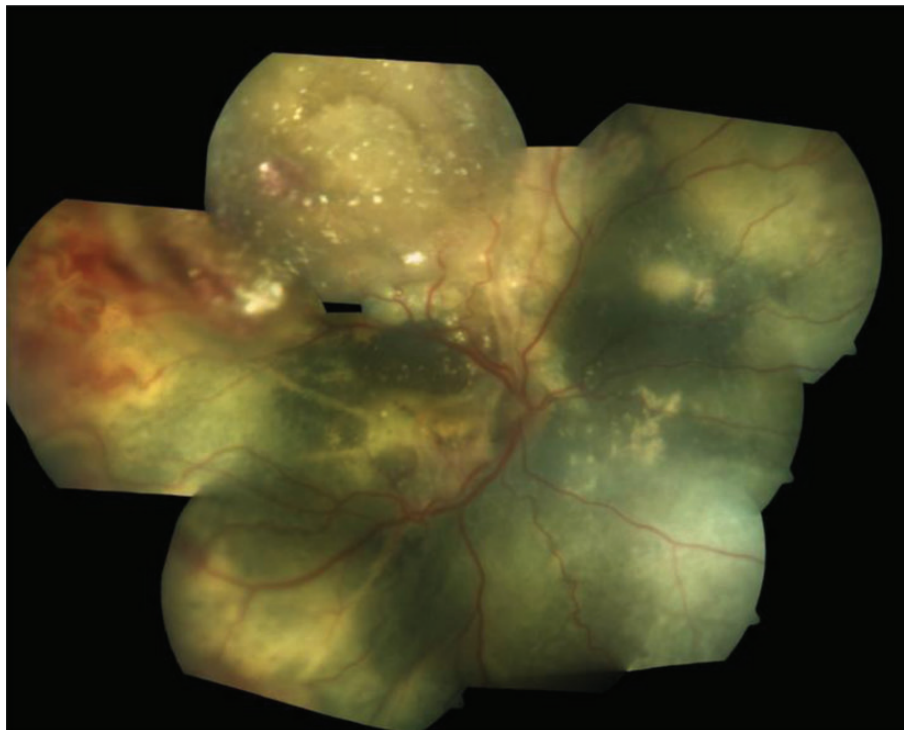


Figure 2: Colour fundus montage of successfully drained ERD following Coats' disease.

effects and to avoid retinectomy and silicone oil tamponade. They described nil further therapy in 31%, additional therapy in 69% and revisional surgery with silicone oil tamponade in 46% of patients as well as visual improvement (27%), visual stability (36%) and visual deterioration (36%).

Cai et al.¹⁹ have described the effectiveness of endolaser photocoagulation by a two-port pars plana nonvitrectomy approach for treating Coats' disease with shallow ERD treatment. In their study of 25 eyes with treatment sessions varying from one to five, the retina reattachment rate was 96% and retinal redetachment rate was 4%. The proposed technique involves laser application directly to telangiectasia within the retina without targeting the RPE to create thermal injury in a non-vitrectomized eye with good peripheral retinal examination. Injection of viscoelastic was performed to minimize vitreous traction at the side ports.

Risk of vitreoretinal traction²⁰ on usage of bevacizumab for Coats' disease with ERD was alerted by Ramasubramanian et al. in their analysis of eight patients with Coats' disease manifesting total or partial ERD where the retinal telangiectasia was treated with standard laser photocoagulation and/or cryotherapy plus additional intravitreal bevacizumab (1.25 mg/0.05 ml). Authors reported resolution of retinopathy (100%), SRF (100%), retinal exudation (75%) and vitreous fibrosis developed (50%).

Use of intravitreal bevacizumab is controversial. Victor et al.²¹ in their study of 24 patients used intravitreal bevacizumab followed by laser

vascular ablation in the management of advanced Coats' disease presenting with ERD. None of the patients in their series developed vitreous fibrosis.

Rishi et al.²² have described treatment and outcome patterns in 307 Indian eyes with Coats' disease. Subretinal drainage was done in 21 (6.8%) cases and an attached retina was found in 12 and detached retina in 9 cases. Vitrectomy was done in 8(4.2%) cases and an attached retina was found in 7 and detached retina in a single case.

Coats disease

- *Laser is the main stay of treatment in Coats disease*
- *SRF drainage attempted in combination with cryotherapy for bullous peripheral detachments.*
- *The aim of SRF drainage is to prevent phthisis or painful blind eye and not visual gain.*
- *Retinotomy should be avoided and endodrainage should be performed in cases of combined retinal detachment with signs of chronicity.*
- *Retinoblastoma should be excluded in all children with bullous detachment and leukocoria.*

Vogt–Koyanagi–Harada syndrome

The Vogt–Koyanagi–Harada syndrome (VKH) is an autoimmune-mediated genetically influenced bilateral, diffuse granulomatous uveitis associated

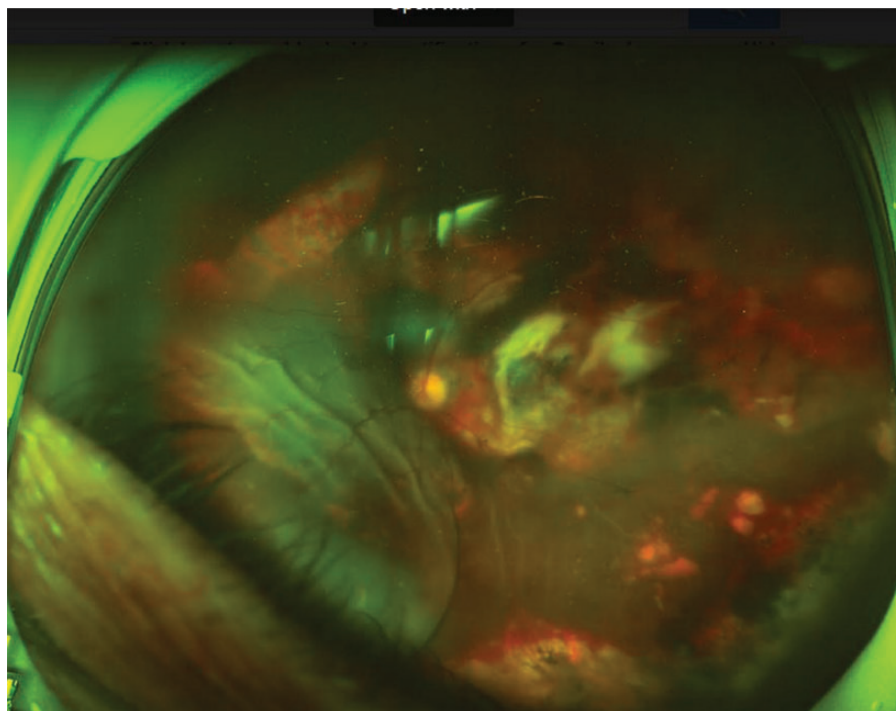


Figure 3: Polypoidal choroidal vasculopathy with ERD.

with poliosis, vitiligo, alopecia and central nervous system and auditory signs.

Tyrosinase or tyrosinase-related proteins have been proposed to be possible target antigens.²³ Till date, there is no single diagnostic test which can pinpoint the diagnosis of VKH. We do not have any evidence in the literature regarding the occurrence of sensitization to melanocytic antigens. VKH disease diagnosis is purely based on exclusion of other diseases. Ultrasonography is mandatory to demonstrate diffuse choroidal thickening, without a positive 'T' sign. FFA should show the presence of pinpoint areas of choroidal leakage.

The conventional treatment includes control of inflammation by regional, oral and intravenous corticosteroids, cyclosporine, antimetabolites and alkylating agents.

A successful surgical treatment (vitrectomy) for bilateral bullous retinal detachment in a patient with VKH disease is reported. Gaun et al.²⁴ has described parsplana lensectomy and vitrectomy being done on a 78-year-old female with severe reduction of visual acuity in both eyes because of an extremely bullous non-rhegmatogenous retinal detachment accompanied by VKH disease. They had also supplemented with systemic and topical corticosteroid therapy. They reported no recurrence of retinal detachment even after tapering the dose of corticosteroid. They had concluded that vitrectomy may be an effective therapeutic option in the treatment for severe bullous retinal detachment associated with VKH disease.

Vogt-Koyanagi-Harada syndrome

- *Chronic VKH can be differentiated from CSCR by a course of steroids and improvement with no worsening.*
- *Control of inflammation is the mainstay of treatment.*
- *SRF drainage is attempted in chronic, non responsive bullous retinal detachments like in Coats disease.*
- *Recurrences are common.*

Von Hippel–Lindau disease

Von Hippel–Lindau disease (VHL) is a multisystem familial tumour syndrome with autosomal dominant inheritance with high penetrance. Ocular lesions are characterized by retinal capillary haemangioma which is the most common presentation of VHL disease. Extraocular lesions include central nervous system haemangioma, endolymphatic sac tumour of the inner ear, pancreatic cysts, pancreatic adenoma, pancreatic islet cell tumours, pheochromocytoma, renal cyst, renal carcinoma, cystadenoma of the epididymis and

the broad ligament. VHL gene is a tumour suppressor gene and is mapped to the short arm of chromosome 3p25. Genetic testing can be done with greater precision. Use of surveillance protocols is recommended for improving survival rate through early detection.

Conventional therapy to retinal capillary haemangioma is based on size of lesion, amount of exudation and the coexisting clinical condition. Treatment modalities are observation, laser photocoagulation, transpupillary thermotherapy, cryotherapy, photodynamic therapy, plaque radiotherapy and proton therapy. ERD in VHL can occur due to retinal capillary haemangioma itself or secondary to treatment of retinal capillary haemangioma.

Fang-Yi et al.²⁵ have reported a rare case of VHL disease with multiple peripheral retinal capillary haemangioma (RCHs) treated by PDT combined with intravitreal bevacizumab injection, which showed significant tumour regression but with persistent exudative RD that required surgical intervention. The massive exudation which developed during the second day was probably due to the summation reaction of three large RCHs to PDT. The authors further recommended that fractionated PDT may be used in cases with multiple RCHs where one tumour is treated at a time to reduce the post-treatment reaction.

Kim et al.²⁶ indicated that treatments for large RCHs in patients with VHL disease must be based on careful selection. Although PDT is considered one of the useful treatment options for RCH, PDT combined with an intravitreal injection of bevacizumab can lead to permanent and severe deterioration of vision because of massive ERD.^{27–30} Therefore, frequent fundus examinations should be performed after PDT. They could successfully reattach the retina with PPV, internal SRF drainage retinotomy, endodiathermy, cryotherapy and endolaser therapy on the RCH, and injection of silicone oil and bevacizumab.

The two theories explain the increased exudation from retinal haemangioma following PDT. First, it could be increased leakage from the vascular lesion, a response known to occur with laser photocoagulation and cryotherapy. Alternatively, PDT can affect the choroidal vasculature, causing ischaemia and even shutdown of the choriocapillaris or retinal capillaries with breakdown of the vascular barrier and significant SRF exudation, a response seen in PDT treatment of choroidal neovascularization.³¹

Von Hippel-Lindau disease

- *Peripheral tractional detachment can occur following laser/ cryotherapy and can be treated with scleral buckling.*

- Occurrence of iatrogenic retinal breaks should be prevented while performing vitrectomy in bullous retinal detachments.
- Absence of posterior vitreous detachments and presence of thick fibrous sheets is challenging.
- Bleeding can be uncontrollable.
- Endocryotherapy can be used to treat vascular lesions

ERD in retinopathy of prematurity

Ittiara et al.³² had reported the rare complication of bilateral ERDs in a preterm infant (25 weeks of gestational age) treated with only intravitreal bevacizumab for ROP. The bilateral ERDs developed after 1 year. The right eye was treated with intravitreal bevacizumab, laser ablation and scleral buckling, resulting in resolution of the exudation and detachment. The left eye was treated with vitrectomy and lensectomy, but persistent exudation and detachment remained. This case study demonstrates the need for frequent and longer follow-up after bevacizumab injection for retinopathy of prematurity until the completion of retinal vascularization or until the completion of peripheral ablation with laser photocoagulation.

Other conditions with ERD

- Exudative detachments can occur with posterior scleritis which can be managed with anti-inflammatory agents or anti-infective therapy based on proper diagnosis.
- Exudative detachments can occur after endophthalmitis or choroidal abscess and control of infection is the mainstay of treatment. Therapeutic and diagnostic vitrectomies may be required for proper medical management.
- Exudative detachments can occur following idiopathic polypoidal choroidovasculopathy (Figure 3) and anti-VEGFs are the mainstay of treatment. Vitrectomy may be required to treat breakthrough vitreous haemorrhage in conjunction with anti-VEGF to settle the exudative element. Gas tamponade helps in displacement of subretinal bleeds in these patients with or without the use of tissue plasminogen activator.
- Exudative detachments can present with choroidal detachments following sudden decompression of globe in glaucoma filtration surgeries and can be managed medically similar to exudative RD following laser or cryotherapy.
- Masquerade syndrome can present with exudative detachments of retina, and choroid and malignancy (primary or secondary) should be excluded before resorting to any surgery.

Conclusion

Exudative detachments may show typical shifting fluid and the etiology should be ascertained. The primary cause should be treated and exudative detachments may resolve. Surgery is reserved for limited patients which do not respond to conventional therapy. Recurrences are common even after surgery and visual results may not be encouraging. Patients may require long-term follow-up to achieve a complete remission.

References

1. Charles ST. Controlled drainage of subretinal and choroidal fluid. *Retina* 1985;5:233–4.
2. David F, Patterson BS, Ryan EH Jr. Controlled drainage of subretinal fluid using continuous monitoring with indirect ophthalmoscopy. *JAMA Ophthalmol.* 2013;131(2):228–313.
3. Kang JE, Kim HJ, Boo HD, et al. Surgical management of bilateral exudative retinal detachment associated with central serous chorioretinopathy. *Korean J Ophthalmol.* 2006;20:131–8.
4. Pathengay A S, Chhablani J. External drainage for exudative retinal detachment secondary to central serous chorioretinopathy. *Eye Sci.* 2015;30(4):204–8.
5. Figueroa MS, Arruabarrena C, Sales-Sanz M, et al. Inferior sclerotomies without subretinal fluid drainage for exudative retinal detachment in diffuse retinal pigment epitheliopathy. *Eur J Ophthalmol.* 2008;18(6):965–71
6. John VJ, Mandelcorn ED, Albini TA. Internal drainage for chronic macula-involving serous retinal detachment in idiopathic central serous chorioretinopathy. *Int Ophthalmol.* 2014;34(1):91–5.
7. Chen HC, Ho JD, Chen SN. Perfluorocarbon liquid-assisted external drainage in the management of central serous chorioretinopathy with bullous serous retinal detachment. *Chang Gung Med J.* 2003;26:777–81.
8. Kang JE, Kim HJ, Boo HD, et al. Surgical management of bilateral exudative retinal detachment associated with central serous chorioretinopathy. *Korean J Ophthalmol.* 2006;20(2):131–8.
9. Shanmugam PM, Ramanjulu R. Vascular tumors of the choroid and retina. *Indian J Ophthalmol.* 2015;63(2):133–140.
10. Gass JD. Uveal effusion syndrome: a new hypothesis concerning pathogenesis and technique of surgical treatment. *Trans Am Ophthalmol Soc.* 1983;81:246–60.
11. Elagouz M, Stanescu-Segall D, Jackson TL. Uveal effusion syndrome. *Surv Ophthalmol.* 2010;55(2):134–45.
12. Boynton JR, Purnell EW. Bilateral microphthalmos without microcornea associated with unusual papillomacular retinal folds and high hyperopia. *Am J Ophthalmol.* 1975;79(5):820–6.
13. Lee S, Ai E, Lowe M, et al. Bilateral macular holes in sporadic posterior microphthalmos. *Retina* 1990;10(3):185–8.
14. Spitznas M, Gerke E, Bateman JB. Hereditary posterior microphthalmos with papillomacular fold and high hyperopia. *Arch Ophthalmol.* 1983;101(3):413–7.
15. Ryckewaert M, Zanlonghi X, Bertrand-Cuignet H, et al. High hyperopia with papillomacular fold. *Ophthalmologica* 1992;204(1):49–53.
16. Faulborn J, Kölli H. Sclerotomy in uveal effusion syndrome. *Retina* 1999;19(6):504–7.
17. Shields JA, Shields CL, Honavar SG, et al. Classification and management of Coats' disease: the 2000 Proctor Lecture. *Am J Ophthalmol.* 2001;131(5):572–83. doi:
18. Cai X, Zhao P, Zhang Q, Jin H. Treatment of stage 3 Coats' disease by endolaser photocoagulation via a two-port pars plana nonvitrectomy approach. *Graefes Arch Clin Exp Ophthalmol.* 2015;253(7):999–1004.

19. Ramasubramanian A, Shields CL. Bevacizumab for Coats' disease with exudative retinal detachment and risk of vitreoretinal traction. *Br J Ophthalmol*. 2012;96(3):356–9.
20. Villegas VM, Gold AS, Berrocal AM, et al. Advanced Coats' disease treated with intravitreal bevacizumab combined with laser vascular ablation. *Clin Ophthalmol*. 2014;8:973–6.
21. Suesskind D, Altpeter E, Schrader M, et al. Pars plana vitrectomy for treatment of advanced Coats' disease—presentation of a modified surgical technique and long-term follow-up. *Graefes Arch Clin Exp Ophthalmol* 2014;252(6):873–9.
22. Rishi P, Rishi E, Uparkar M, et al. Coats' disease: an Indian perspective. *Indian J Ophthalmol*. 2010;58(2):119–24.
23. Kondo I, Yamagata K, Yamaki K, et al. Analysis of the candidate antigen for Harada's disease. *Nippon Ganka Gakkai Zasshi*. 1994;98(6):596–603.
24. Gaun S, Kurimoto Y, Komurasaki Y, et al. Vitreous surgery for bilateral bullous retinal detachment in Vogt-Koyanagi-Harada syndrome. *Ophthalmic Surg Lasers* 2002;33(6):508–10.
25. Gaudric A, Krivosic V, Duguid G, et al. Vitreoretinal surgery for severe retinal capillary hemangiomas in Von Hippel-Lindau disease. *Ophthalmology* 2011;118(1):142–9.
26. Tsai FY, Lau LI, Chen SJ, et al. Persistent exudative retinal detachment after photodynamic therapy and intravitreal bevacizumab injection for multiple retinal capillary hemangiomas in a patient with Von Hippel-Lindau disease. *J Chin Med Assoc*. 77(1):52–6.
27. Kim HM, Park KH, Woo SJ. Massive exudative retinal detachment following photodynamic therapy and intravitreal bevacizumab injection in retinal capillary hemangioma. *Korean J Ophthalmol*. 2015;29(2):143–5.
28. YM, Jalil A, Mathews J, et al. Exudative retinal detachment following photodynamic therapy for retinal capillary hemangioma. *Can J Ophthalmol*. 2010;45:299–300.
29. Goto S, Oshima Y, Tsujikawa M, et al. Massive exudative retinal detachment after photodynamic therapy for peripheral retinal capillary hemangioma. *Retin Cases Brief Rep*. 2013;7:86–8.
30. Chen Y, Liu H, Zhang K, et al. Massive exudative retinal detachment following photodynamic therapy for retinal hemangioma in Von Hippel-Lindau Syndrome. *Photodiagn Photodyn Ther*. 2014;11:250–3.
31. Arnold JJ, Blinder KJ, Bressler NM, et al. Acute severe visual acuity decrease after photodynamic therapy with verteporfin: case reports from randomized clinical trials – TAP and VIP report no. 3. *Am J Ophthalmol*. 2004;137:683–96.
32. Ittiara S, Blair MP, Shapiro MJ, et al. Exudative retinopathy and detachment: a late reactivation of retinopathy of prematurity after intravitreal bevacizumab. *J AAPOS* 2013; 17(3):323–5.

How to cite this article Ganesan S. and Rishi E. Surgical implications in exudative retinal detachment, *Sci J Med & Vis Res Foun* 2017;XXXV:29–36.

Managing a case of buckle intrusion with recurrent vitreous haemorrhage: a case report

Sharan Shetty¹ and Muna Bhende²

¹Fellow,
Sri Bhagwan Mahavir
Vitreoretinal Services,
Sankara Nethralaya,
Chennai, India

²Senior Consultant & Deputy
Director,
Sri Bhagwan Mahavir
Vitreoretinal Services,
Sankara Nethralaya,
Chennai, India

Correspondence:
Muna Bhende,
Deputy Director and Senior
Consultant,
Sri Bhagwan Mahavir
Vitreoretinal Services,
Sankara Nethralaya,
Chennai, India.
Email: drmuna@snmail.org

Introduction

Scleral buckling (SB) with silicone implants is an effective method to reattach the retina. Silicone implants used for SB in retinal detachment surgery have been associated with various complications which include buckle infection, granuloma formation, extrusion of the implant through the conjunctiva, double vision and restriction of ocular motility. Intrusion of the implant through the sclera may develop due to progressive scleral thinning.¹

Intrusion is defined as erosion, followed by protrusion of the scleral implant into the vitreous cavity. The intruding material may either be the material implanted on the sclera or the sutures. Intrusion of the buckle through the sclera into the subretinal space is particularly difficult to manage and can result in severe vision loss, recurrent retinal detachment and subretinal or vitreous hemorrhage.² We report a case of a patient suffering from recurrent vitreous haemorrhages following scleral buckle intrusion 14 years after surgery, managed by buckle removal without removing the encirclage band.

Case report

A 31-year-old male presented to us with history of recurrent floaters in the left eye since 3 months. He had undergone SB 14 years back for rhegmatogenous retinal detachment following a blunt trauma. Patient had good vision following the surgery and was on regular follow-up. He developed recurrent retinal detachment for which he underwent pars plana vitrectomy, 3 months ago. On examination, his best-corrected visual acuity (BCVA) was 20/40 with intraocular pressure of 30 mmHg. Slit-lamp examination was within normal limits. Fundus examination revealed an attached retina with high buckle indentation and buckle intrusion in the inferior half (Figure 1) along with neovascularization and haemorrhage over the area of intrusion (Figure 2). Patient was started on topical 0.5% timolol maleate twice a day. On follow-up visit after a month, he gave a history of one more episode of vitreous haemorrhage. On examination, subconjunctival haemorrhage was noted over the superior bulbar conjunctiva with anterior migration of the buckle element. Patient was put on a full course of oral antibiotic along with topical antibiotics and was advised removal of the segmental buckle. General anaesthesia was

preferred in view of high chance of intraoperative globe rupture. However, patient did not undergo the surgery and reported back to us after 3 months. Anterior migration of the scleral buckle was noted this visit. Patient was taken up for scleral buckle removal along with trimming the encirclage over the segmental buckle element.

An external approach was planned for buckle removal. A standby scleral graft was made available to patch any visible scleral defect. The conjunctiva and the tenons were dissected of the scleral buckle in the supero-temporal quadrant. The two anchor sutures were cut and removed. The buckle element was cut at the centre and gently expressed out. The encirclage over the buckle was trimmed and edges were repositioned into the sub-tenons space. The tenons and the conjunctiva were sutured in layers (Figure 3).

Postoperatively, the retina remained attached with a BCVA of 20/30. Two months later, patient had maintained a vision of 20/30 with reduction in the buckle indent with no further episodes of vitreous haemorrhage with persisting NVE at the area of buckle intrusion (Figure 4).

Discussion

SB with exogenous material is an effective method to reattach the retina. Retrospective series have reported complications of SB, most commonly extrusion and infection, in 1.3–24.4% of eyes. Intrusion and erosion are rarely reported complications of SB, noted to occur in approximately 4 of 4400 cases.³ It has been associated with myopia because of the related scleral thinning and altered scleral strength.⁴ SB erosion and intrusion may cause visual symptoms and result in retinal detachment, vitreous haemorrhage and endophthalmitis. An intruding or eroding SB may be left untouched unless there is any complications, or is a significant danger to the integrity of the ocular structures.⁵

The decision to remove an SB can be puzzling, as each case is unique. SB removal can be considered necessary if signs and symptoms are progressive or additional complications occur (e.g., endophthalmitis and scleral necrosis). If signs and symptoms are chronic and stable (e.g., extrusion), SB removal is elective. The most dreaded consequence of SB removal is recurrent detachment.⁶ The cause of retinal detachment after buckle removal can be proliferative vitreoretinopathy or a

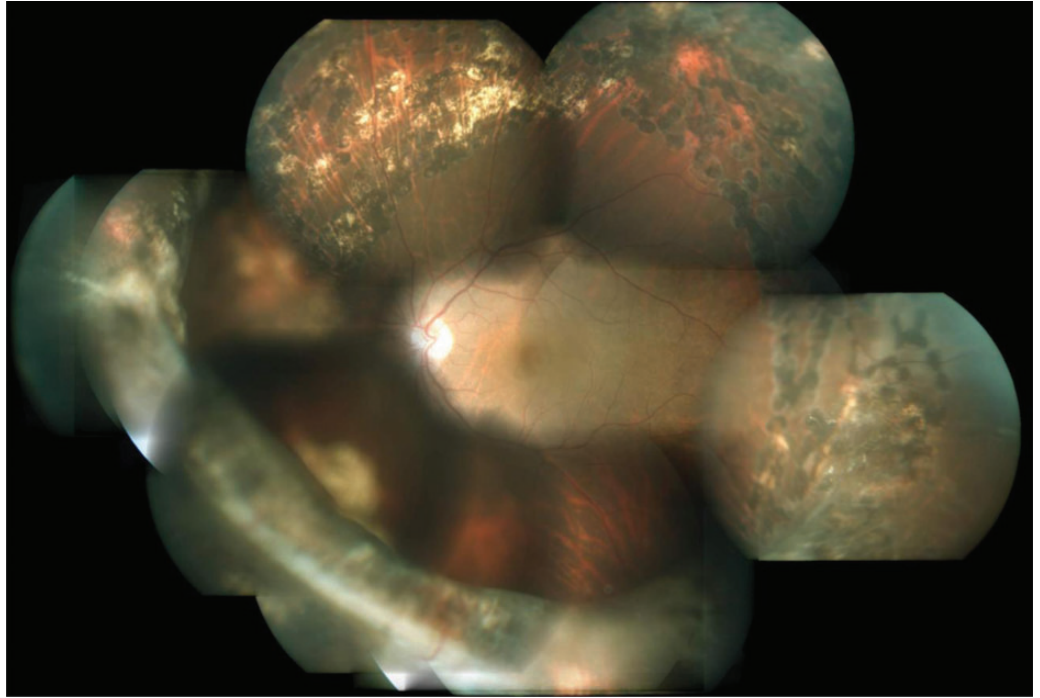


Figure 1: Fundus photo montage of the left eye showing attached retina with buckle intrusion in the infero-nasal quadrant.

new retinal break.⁷ Patients with areas of traction or high-risk lesions should have laser prophylaxis before SB removal.

SB removal is performed in the operating room with topical, local or general anaesthesia. A local anaesthetic injection should be performed with

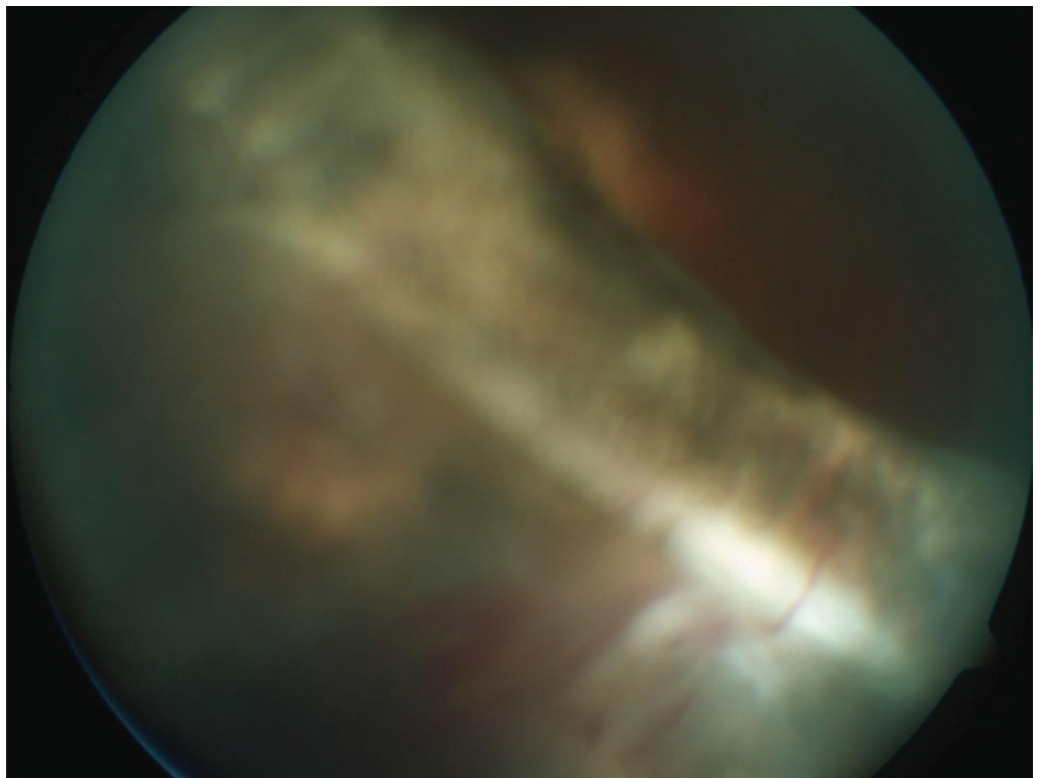


Figure 2: Neovascularization and haemorrhage over the area of buckle intrusion.

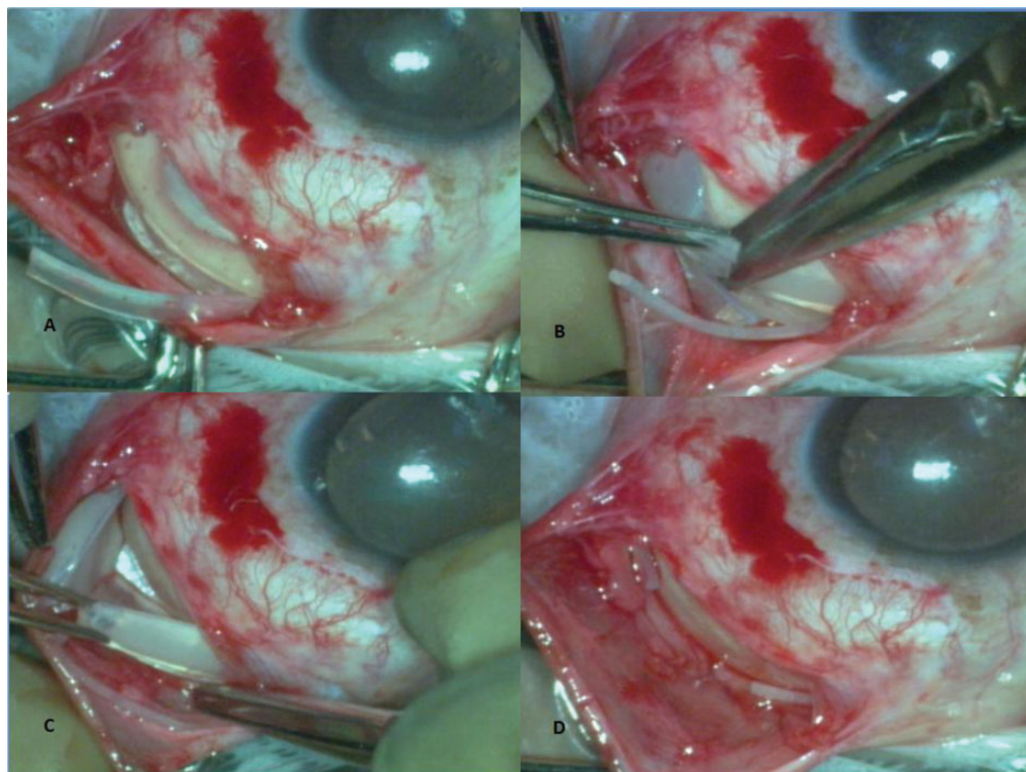


Figure 3: (A) Intraoperative photo showing buckle element *in situ* with the encircling band cut over it. (B) The buckle element is cut at the centre. (C) The buckle element is expressed out. (D) The encircling band is trimmed and repositioned in the sub-tenons space.

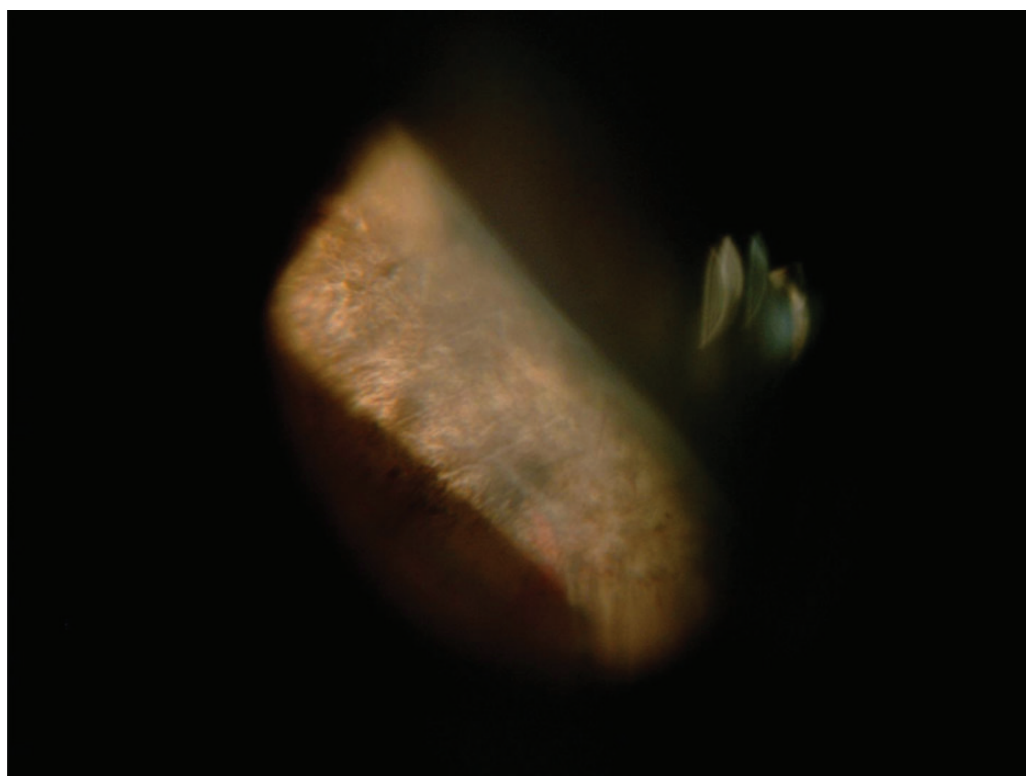


Figure 4: Postoperative fundus photo showing reduction in buckle indent height with resolution of haemorrhage.

caution as many eyes are myopic with a distorted globe after buckle surgery. General anaesthesia should be opted for in cases where scleral necrosis, erosion and intrusion are suspected as chances of globe perforation are high.

Often the SB can be removed with opening one quadrant of conjunctiva or using a pre-existing exposure site. Information of which elements were used and where their ends lie is vital, as dissecting without a clear plan is difficult. When this information is unavailable, SB details can sometimes be gathered by examining the conjunctiva and looking at the buckle indentation on fundus examination. The route of removal of buckle element depends on the degree of intrusion. For example, if the segment is intravitreal then it can be removed via the pars plana.

Depending on the indication, SB-related complications can be managed by 1) cutting the encircling band, 2) removing the exposed segmental buckle element with the other elements left in place and 3) most often, all elements removed along with sutures.⁸ Sutures can be removed or left in place, depending on if they are causing problems and their accessibility. Irrigation with antibiotics should be considered after the procedure, particularly with an infected SB. If scleral necrosis or erosion and intrusion are suspected, patch materials and sutures should be kept available.

Removed SB and sutures should be sent for microbiological examination.

In this case, a conservative approach of removal of the just the buckle element without removal of the encirclage was followed as there was anterior migration of the scleral buckle element along with the intrusion of the encirclage in the opposite quadrant.

References

1. Kokame GT, Germar GG. Successful management of intruded hydrogel buckle with buckle removal, scleral patch graft, and vitrectomy. *Retina* 2003;23(4):536–8.
2. Shami MJ, Abdul-Rahim AS. Intrusion of a scleral buckle: a late complication of retinal reattachment surgery. *Retina* 2001;21(2):195–7.
3. Deutsch J, Aggarwal RK, Eagling EM. Removal of scleral explant elements: a 10-year retrospective study. *Eye* 1992;6(6):570–3.
4. Nguyen QD, Lashkari K, Hirose T, et al. Erosion and intrusion of silicone rubber scleral buckle: presentation and management. *Retina* 2001;21(3):214–20.
5. Kitagaki T, Morishita S, Kohmoto R, et al. A case of intraocular erosion and intrusion by an arruga suture. *Case Rep Ophthalmol*. 2016;7(1):174–8.
6. Deokule S, Reginald A, Callear A. Scleral explant removal: the last decade. *Eye* 2003;17(6):697–700.
7. Goezinne F, La Heij EC, Berendschot TT, et al. Incidence of redetachment 6 months after scleral buckling surgery. *Actaophthalmologica* 2010;88(2):199–206.
8. Tsui I. Scleral buckle removal: indications and outcomes. *Survey Ophthalmol*. 2012;57(3):253–63.

How to cite this article Shetty S. and Bhende M. Managing a case of buckle intrusion with recurrent vitreous haemorrhage: a case report, *Sci J Med & Vis Res Foun* 2017;XXXV:37–40.

Sclearal buckle infection presenting as subretinal inflammatory mass lesion

Kalpita Das¹, Gaurav Mathur² and Muna Bhende³

^{1,2}Fellow, Sri Bhagwan Mahavir Vitreoretinal Services, Sankara Nethralaya, Chennai, India

³Senior Consultant & Deputy Director, Sri Bhagwan Mahavir Vitreoretinal Services, Sankara Nethralaya, Chennai, India

Correspondence:

Muna Bhende,
Deputy Director and Senior Consultant,
Sri Bhagwan Mahavir Vitreoretinal Services,
Sankara Nethralaya,
Chennai, India.
Email: drmuna@snmail.org

Introduction

Sclearal buckling (SB) is an important and effective surgical technique for the management of rhegmatogenous retinal detachment.^{1,2} Sclearal buckle exposure with or without infection remains most common complication of the surgery requiring removal of the explant or implant.³⁻⁵ Intraocular infection following SB surgery is extremely rare,⁶ the procedure being mostly extraocular. We report a case of subretinal inflammatory mass lesion following sclearal buckle infection and its successful management.

Case report

A 40-year-old female underwent uncomplicated retinal detachment surgery in the form of inferior sclearal buckle (276 segmental silicone sleeve from 3-8'o clock hours with 240 circumferential band), cryopexy with no subretinal fluid drainage for a post-traumatic subtotal macula involving retinal detachment of the left eye. She recovered good vision postoperatively and was lost to follow-up. She came to us again after 10 years with complaints of mild pain and discharge. Her vision in the right eye was 6/6, N6 and left eye 6/45, N36. The anterior segment in the right eye was within normal limits. The left eye showed an exposed sclearal buckle in the inferior fornix. There was no conjunctival congestion or associated sclearal thinning. Intraocular pressure in both eyes was 16 mmHg. Fundus examination of the right eye was normal and left eye showed an attached retina with good buckle effect inferiorly. Patient was advised buckle removal but did not report for the same. She was also diagnosed as a case of microcytic hypochromic anaemia for which she was started on medical therapy.

Patient came again after 4 years of last presentation with complaints of sudden diminution of vision, pain, redness in the left eye of 1 month duration. Her vision dropped to counting finger one meter, <N36 in the left eye and anterior segment showed hyperemic conjunctiva, exposed buckle inferiorly with surrounding discharge. Cornea was clear and anterior segment showed grade 1 cells. Dilated fundus examination showed vitreous haze with a diffuse elevated subretinal lesion and surrounding subretinal fluid in the temporal quadrant (around 3'o clock) suggestive of a subretinal inflammatory lesion. Rest of the retina was flat with good buckle effect seen inferiorly. Ultrasound of the left eye showed a retinochoroidal elevation with high surface reflectivity and heterogenous internal reflectivity over the buckle. CT scan of the orbit showed ill-defined soft tissue thickening of the temporal periocular area continuous with the lateral rectus insertion. Sclearal buckle was removed under general anaesthesia, and the buckle and sutures were sent for microbiological investigations. Surgery was uneventful, and the buckle was noted to have blackish deposits on the surface. There was no sclearal perforation, abscess or granuloma noted intraoperatively. Microbiological studies from the buckle revealed methicillin-sensitive *Staphylococcus aureus* and *Aspergillus terreus*. Patient was treated postoperatively with oral Ciprofloxacin 500 mg twice daily for 5 days and oral Fluconazole 200 mg twice daily for 3 weeks, fortified Gentamicin eye drops every 1 hourly with weekly tapering schedule for 1 month. Postoperatively on the third day, fundus examination showed clearer media with a decrease in size of the retinochoroidal lesion. On

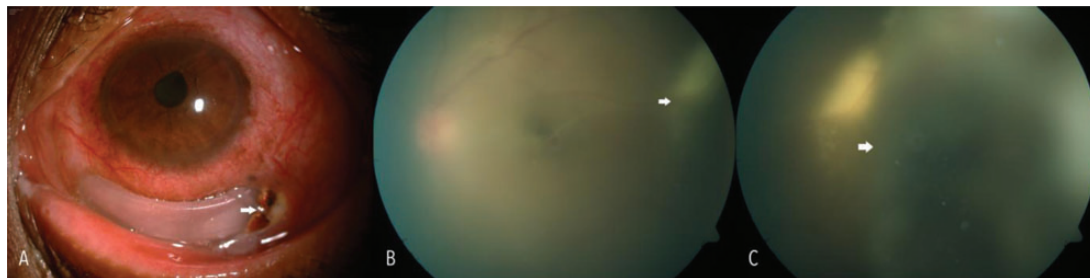


Figure (A-C) External photograph and fundus pictures of a patient with exposed scleral buckle and painful drop in vision 14 years after surgery. Note the blackish material at the junction of the exposed and unexposed buckle (arrow). (B and C) The vitreous haze with exudation temporally (arrow) and a mass-like lesion anterior to it (arrow in C).

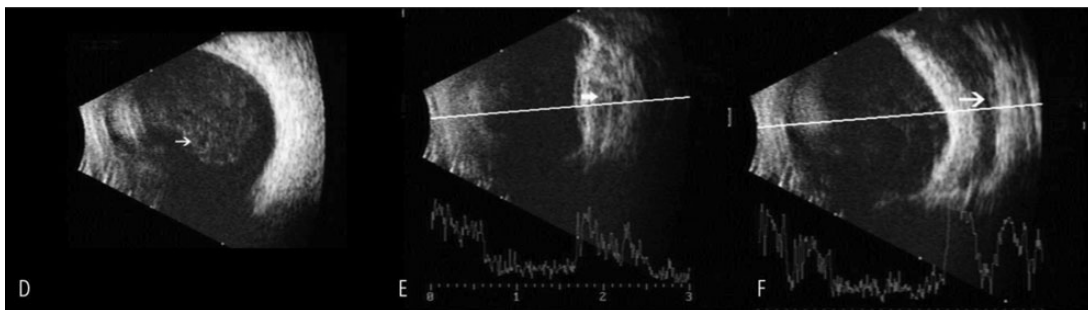


Figure (D–F) B scan images of the same eye showing vitreous echoes suggestive of inflammation (arrow in D). (E) A temporal mass-like lesion of variable reflectivity and an area of echolucency suggestive of the solid silicone buckle element (arrow). (F) The appearance of the exposed buckle—seen as an echolucent structure with no evidence of inflammation or damage to the surrounding areas.

follow-up at 3 months, vision improved to 6/36, N36 and fundus examination showed clear media, attached retina with good buckle effect with a flat plaque of subretinal hard exudates. There was no subretinal fluid or mass visible though residual buckle effect was noted. Ocular movements were full range and painless. Patient was advised a regular follow-up after 6 months henceforth.

Discussion

SB is an extraocular procedure with an associated risk of intraocular infection being only 0.19%.⁷ Intraocular infection is mainly associated with procedures like subretinal fluid drainage, gas injections or accidental needle perforation during suturing.⁶ The most common causative organism in buckle infections includes *Staphylococcus aureus*, *Staphylococcus epidermidis*, *Proteus* and

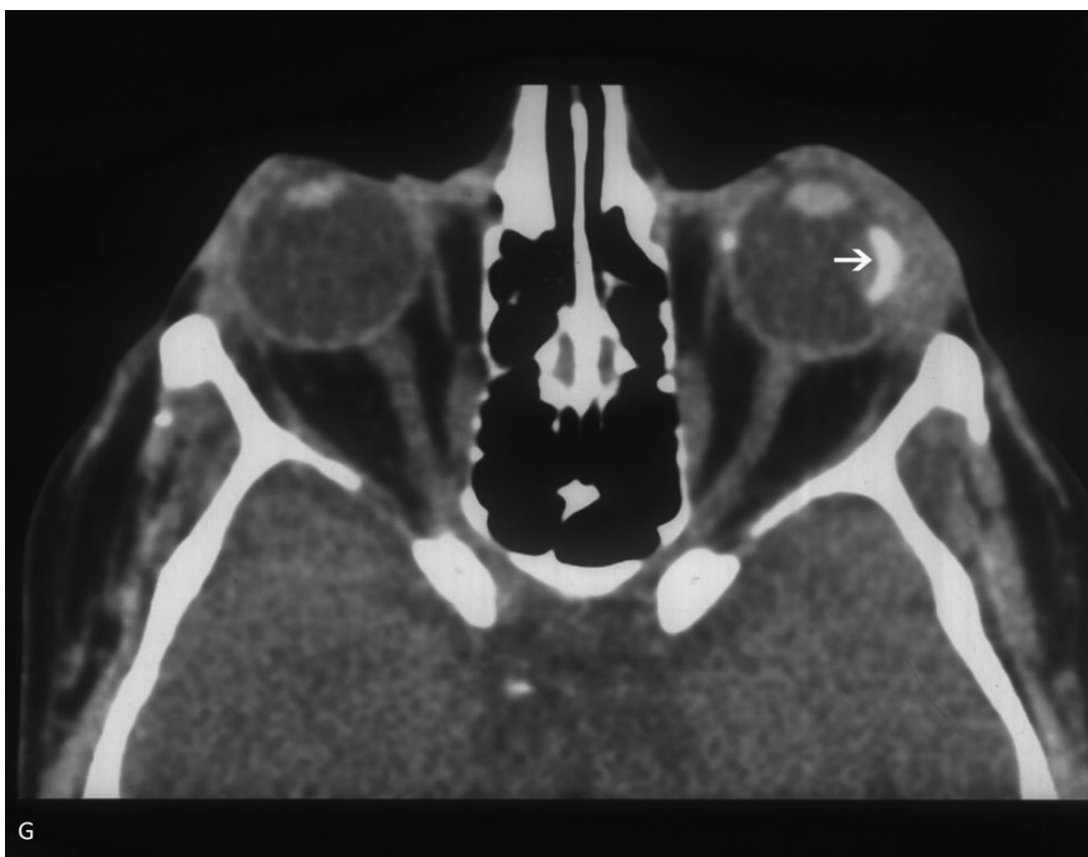


Figure (G) CT scan shows a soft tissue mass around the scleral buckle continuous with the lateral rectus insertion.

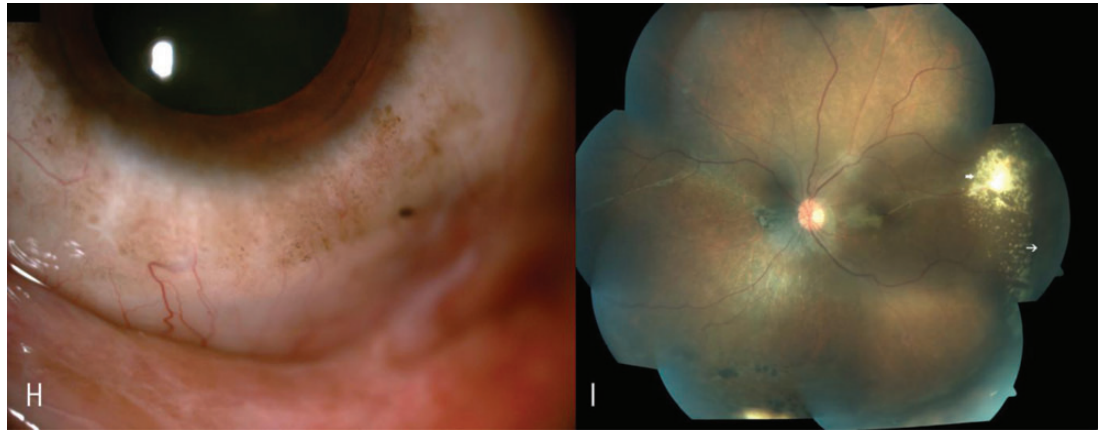


Figure (H and I) The same patient after removal of the buckle and treatment with topical and systemic antifungals (the culture of the buckle element and discharge showed *Aspergillus*). The eye is quiet. The fundus montage shows that the media is clear, retina attached with few residual hard exudates (arrow). The persistence of buckle effect is seen anterior to the exudates (thin arrow)

Pseudomonas.^{5,8-10} Fungal infections causing buckle infections are rare as the severity of infection is related to host immune defences and environmental conditions.¹¹ Severe anaemia could probably be one of the risk factors for infection with *Aspergillus* in our patient. A case report of scleral buckle infection with subretinal abscess has been reported; however, the infection site was likely to be the drainage retinotomy in it.¹⁰ Without any scleral perforation, intrusion of the buckle or a drainage retinotomy, it is unlikely for an organism to invade and cause endophthalmitis. Some of the highly virulent organisms have been found to invade the intact sclera,¹¹ but in our case on removal of the buckle the sclera was found intact with no evidence of scleral abscess or thinning or perforation.

In this patient, we did not consider the subretinal inflammatory lesion as a sign of intraocular infection and did not treat it with intravitreal antibiotics because of the following reasons. It is rare for any bacteria or fungus to penetrate through intact sclera when there has been no drainage done, it is the toxin-mediated severe inflammatory response leading to sterile vitritis and the subretinal lesion. The patient improved significantly after removal of the buckle without the use of steroids or intravitreal antibiotics, indicating that the changes were secondary to the exposed, infected buckle. It is interesting to note that the area of the exposed buckle did not show any abscess, but it was the segment that was covered by conjunctiva that had the subretinal lesion beneath it.

This is a unique case where an inflammatory retinal lesion simulated an endophthalmitis-like picture but resolved after scleral buckle removal and conservative management with systemic and topical antibiotics.

References

- Schwartz SG, Flynn HW. Primary retinal detachment: scleral buckle or pars plana vitrectomy. *Curr Opin Ophthalmol.* 2006;17:245-50.
- Falkner-Radler CI, Myung JS, Moussa S, et al Trends in primary retinal detachment surgery: results of a Bicenter study. *Retina* 2011;31:928-36.
- Tsui I. Scleral buckle removal: indications and outcomes. *Surv Ophthalmol.* 2012;57:253-63.
- Han DP, Covert DJ, Wirosko WJ, et al. Scleral buckle removal in the vitrectomy era: a 20-year clinical experience. *Retina* 2013;33:387-91.
- Kazi MS, Sharma VR, Kumar S, et al. Indications and outcomes of scleral buckle removal in a tertiary eye care center in South India. *Oman J Ophthalmol.* 2015;8:171-4.
- Ho PC, McMeel JW. Bacterial endophthalmitis after retinal surgery. *Retina* 1983;3:99-102.
- Oz O, Lee DH, Smetana SM, et al. A case of infected sclera buckle with *Mycobacterium chelonae* associated with chronic intraocular inflammation. *Ocul Immunol Inflamm.* 2004;12:65-7.
- Pathengay A, Karosekar S, Raju B, et al. Microbiologic spectrum and susceptibility of isolates in scleral buckle infection in India. *Am J Ophthalmol.* 2004;138:663-4.
- Smiddy WE, Miller D, Flynn HW Jr. Scleral buckle removal following retinal reattachment surgery: clinical and microbiological aspects. *Ophthalmic Surg.* 1993;24:440-5.
- Tay E, Bainbridge J, da Cruz L. Subretinal abscess after scleral buckling surgery: a rare risk of retinal surgery. *Can J Ophthalmol.* 2007;42:141-2.
- Chhablani J, Nayak S, Jindal A, et al. SB infections: microbiological spectrum and antimicrobial susceptibility. *J Ophthalmic Inflamm Infect.* 2013;3:67.

How to cite this article Das K., Mathur G. and Bhende M. Scleral buckle infection presenting as subretinal inflammatory mass lesion, *Sci J Med & Vis Res Foun* 2017;XXXV:41-43.

Macular buckle for myopic retinal detachment

Anmol Naik¹ and Pradeep Susvar²

¹Fellow, Sri Bhagwan Mahavir Vitreoretinal Services, Sankara Nethralaya, Chennai, India

²Senior Consultant, Sri Bhagwan Mahavir Vitreoretinal Services, Sankara Nethralaya, Chennai, India

Correspondence to:
Pradeep Susvar,
Senior Consultant,
Sri Bhagwan Mahavir
Vitreoretinal Services,
Sankara Nethralaya,
Chennai, India
Email: drpds@snmail.org

Macular holes are more frequently accompanied by retinal detachment in highly myopic eyes than in those with lesser or no myopia, and the incidence of retinal detachment increases with the presence and the degree of posterior staphyloma.¹ The main cause of visual impairment in pathological myopia is myopic traction maculopathy (MTM). It comprises of myopic foveoschisis (MS), lamellar or full thickness macular hole and posterior pole retinal detachment (with or without macular hole). Posterior staphyloma, being a component of progressive myopia, predisposes to formation of these tractional maculopathies. In some cases, macular retinal detachment developing at the posterior pole exhibits a shortening of the retina in relation to the steep bowing of the sclera at the staphyloma area. This mismatch usually tends to be the cause of failure of retinal re-attachment in conventional vitrectomies with an internal limiting membrane (ILM) peeling procedure. It is in this scenario where macular buckling helps to support the posterior globe to counteract the sclero-retinal mismatch present at the staphyloma. We present a case of high myopia-related posterior pole detachment and macular hole treated successfully with a macular buckling procedure combined with conventional vitrectomy.

Case report

A 56-year-old high myopic lady presented to us with complaint of painless progressively decreasing vision in her right eye since 15 days. On

examination, her best-corrected visual acuity (BCVA) was counting fingers at 1 meter, <N36 in the right eye (OD) with -20 DS and that in the left eye (OS) was 6/18, N6 with -16 DS, -3DC at 150°. The anterior segment examination, pupillary reaction, intraocular pressure and extraocular movements were within normal limits. The fundus images of both eyes are shown in Figure 1. Both eyes revealed a myopic tessellated fundus. OD showed a circumscribed area of myopic macular degeneration with localized retinal detachment (denoted by black arrow) along with a pocket of sub-retinal fluid inferior to the degenerated area. OS showed extensive myopic chorio-retinal atrophy at the macula with pigmentary changes.

A swept source optical coherence tomography (SSOCT) of OD (Figure 2) revealed a full thickness macular hole (thick arrow) and a lamellar hole eccentric to the fovea (thin arrow) with a chronic schitic retina. SSOCT in these cases also helps to look at the severity of the staphyloma at its edges in relation to the retinal layer. Based on the history, clinical findings and investigations, a combined vitrectomy, ILM peeling and macular buckling procedure was planned.

Technique

Morin-Devin wedge, also called as T-shaped macular buckle (France Chirurgie Instrumentation -FCI, France), was used for buckling the macula. The solid silicone [Morin wedge (Figure 3a)] macular plate was threaded onto the 4-mm solid silicone band [Devin band (Figure 3b)]. After a

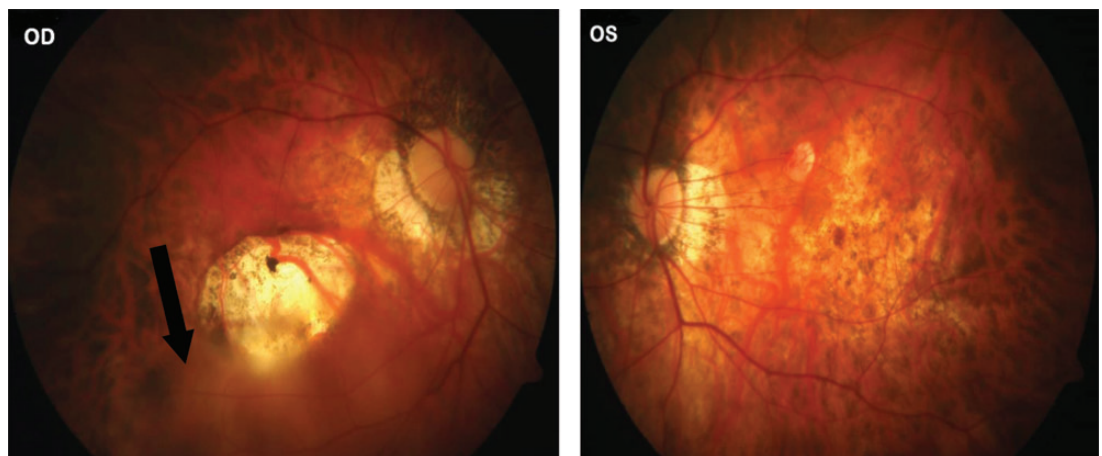


Figure 1: Colour fundus images of the right and left eye (black arrow denotes the area of localized RD).

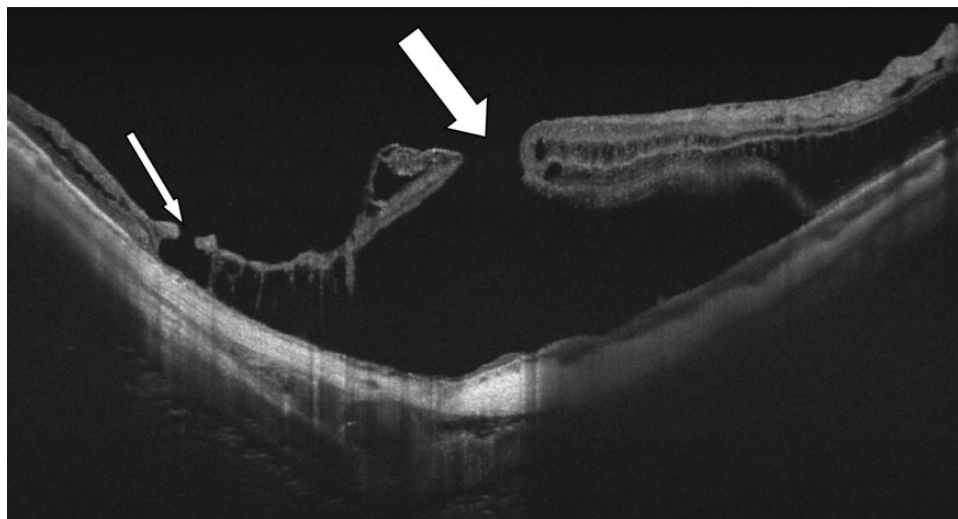


Figure 2: Preoperative SSOCT of the right eye demonstrating schitic retina (thicker arrow denotes full thickness macular hole and thinner arrow denotes lamellar hole eccentric to fovea).

360° limbal peritomy and tagging of four recti muscles, one end of this 4-mm band was first passed under the lateral rectus muscle, then posteriorly under the inferior oblique muscle and brought to nasal side of the inferior rectus. Other free end was passed superiorly under superior rectus and oblique to be brought to the nasal side of superior rectus insertion. Both the ends of the Devin band were then temporarily sutured to the sclera at their respective locations between the vertical and medial rectii. Macular plate was slowly manoeuvred posteriorly under the lateral rectus towards the posterior globe. The anterior end of the macular plate was temporarily secured to the sclera by a 5-0 Mersilene suture. A 23-gauge, three-port complete pars plana vitrectomy (PPV) was carried out. The posterior indentation of the macular plate was titrated and optimized by pulling the nasal side band ends. Conventional staining and ILM peeling were performed followed by fluid-gas exchange and

silicone oil tamponade. Buckle securing sutures were finalized followed by complete conjunctival closure.

Follow-up changes

Clinical findings and SSOCT showed a closed macular hole with good apposition of the retina indented by the convex buckle contour as early as third postoperative day (Figure 4). Six-week follow-up had retinal attachment maintained with closed macular hole appreciated both on slit-lamp biomicroscopic examination and on SSOCT (Figure 5).

BCVA improved to 3/60, N36 at 7 weeks post-operatively and the myopic refractive error reduced to -10 DS from -20 DS due to the indentation at the staphyloma. The anatomical retinal attachment (Figure 6) and vision were maintained months post-silicone oil removal (at 19 months) with moderate cataract changes at the last follow-up 2 years post primary surgery.




Figure 3: (a) Morin macular wedge. (b) Devin band threaded into the plate of the wedge.

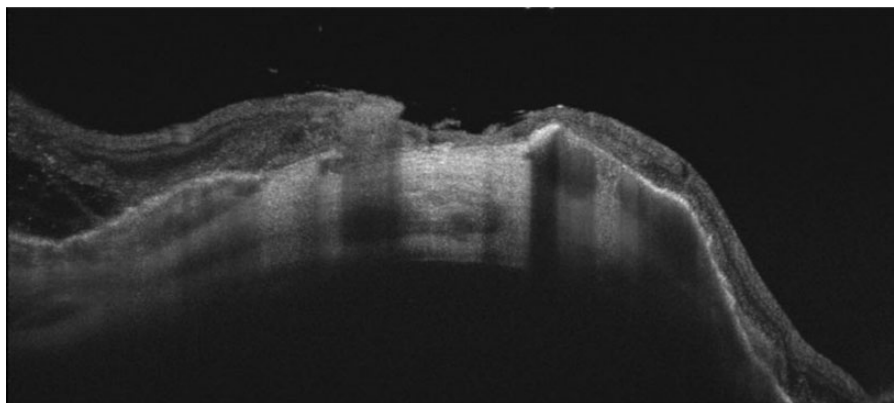


Figure 4: SSOCT right eye—third postoperative day. Note the closure of macular hole with retinal apposition due to the macular buckle effect.

Discussion

RD in pathological myopia typically develops at the posterior pole in cases of MTM. The underlying patho-mechanisms that interplay at the posterior pole are rigidity of ILM relative to the retina, stretching of the retinal layers and progression of staphyloma. The entire process leads to the development of schisis followed by lamellar or full thickness hole at the macula leading to posterior pole detachments. RD due to traction

maculopathies can be surgically treated by conventional vitrectomy with ILM peeling in most cases, thereby taking care of both anteroposterior and tangential traction at the surface of the inner retina. Macular buckle procedure is effective in cases of maculopathy where there is a gross mismatch between the retinal layers and depth of the scleral out-pouch at the staphyloma. Macular buckle can be performed either as a primary procedure or combined with vitrectomy.

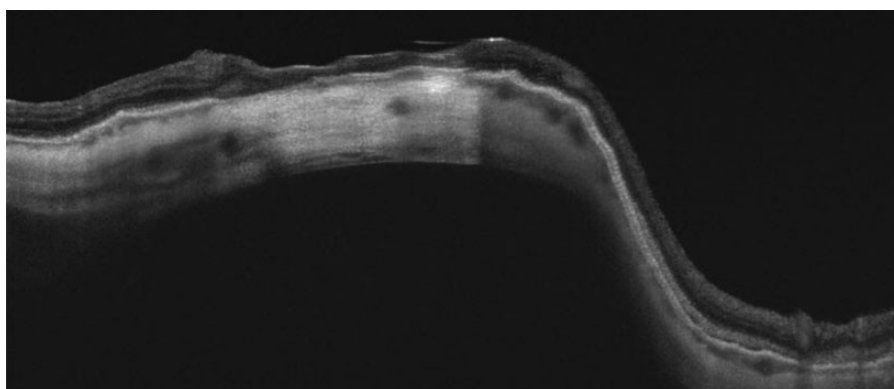


Figure 5: SSOCT right eye—sixth postoperative week.

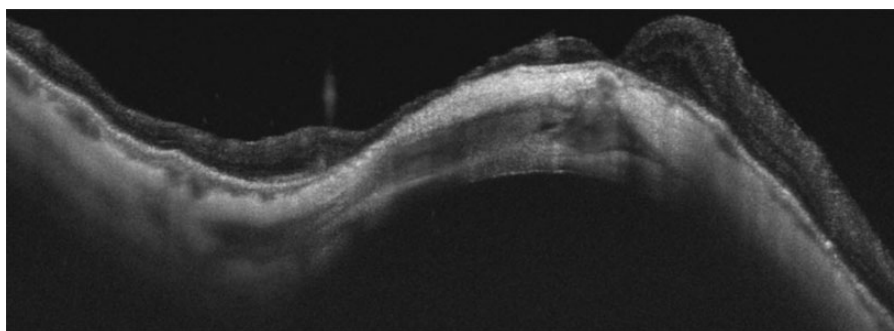


Figure 6: SSOCT right eye—19 months postoperatively. The closure of macular hole and retinal attachment is well maintained.

Various types of macular buckle are available, namely Ando plombe, T-shaped buckle, AJL macular buckle, L-shaped macular buckle, adjustable macular buckle and the traditional wire-strengthened sponge explant,² each with their own merits and demerits. The success rates of retinal attachment after macular buckle with/without vitrectomy have been quite promising. Ando et al.³ reported permanent retinal reattachment in 93.3% of the eyes after the macular buckling procedure with no remarkable intraocular complications, compared with 50% attachment rate with PPV alone. Theodossiadis and Theodossiadis⁴ in their 15-year follow-up found the rate of reattachment to be 88% after macular buckle surgery. Ma et al.⁵ recently published the results of a randomized study with 24-month follow-up, comparing 23G PPV with ILM peeling to 23G PPV, ILM peeling with macular buckle under direct vision. The initial retinal reattachment rate was significantly higher in the second group (93.48%) compared with the first group (76.92%). Xiong et al.⁶ reported resolution of MS in all their patients following the combined procedure of macular buckling, vitrectomy and ILM peeling.

Thus, macular buckling with vitrectomy and ILM peeling seems to more effective than PPV and

ILM peeling alone in myopic retinal detachment with macular hole with posterior staphyloma and failed or recurrent cases of retinal detachment with/without macular hole.²

References

1. Akiba J, Konno S, Yoshida A. Retinal detachment associated with a macular hole in severely myopic eyes. *Am J Ophthalmol.* 1999;128(5):654-5.
2. Pradeep S, Vinay Kumar S. Macular buckle in myopia. *Sci J Med Vis Res Foun.* 2015;XXXIII:71-4.
3. Ando F, Ohba F, Touura K, et al Anatomical and visual outcomes after episcleral macular buckling compared with those after pars plana vitrectomy for retinal detachment caused by macularhole in highly myopic eyes. *Retina* 2003;27(1):37-44.
4. Theodossiadis GP, Theodossiadis PG. The macular buckling procedure in the treatment of retinal detachment in highly myopic eyes with macular hole and posterior staphyloma. *Mean follow-up of 15 years. Retina* 2005;25(3):285-9.
5. Ma J, Li H, Ding X, et al Effectiveness of combined macular buckle under direct vision and vitrectomy with ILM peeling in refractory macular hole retinal detachment with extreme high axial myopia: a 24-month comparative study. *Br J Ophthalmol.* 2017;1-9. doi:.
6. Xiong SQ, Jiang HB, Li FL, et al. Treatment of myopic foveoschisis via macular buckling and vitrectomy. *Int J Ophthalmol.* 2017;10(5):815-8.

How to cite this article Naik A. and Susvar P. Macular buckle for myopic retinal detachment, *Sci J Med & Vis Res Foun* 2017;XXXV:44-47.

Retinal vein occlusion following vitrectomy for rhegmatogenous retinal detachment: a case report

Eesh Nigam¹ and Debmalya Das²

^{1,2}Associate consultant,
Vitreoretinal Services,
Sankara Nethralaya,
Kolkata, India

Correspondence:
Eesh Nigam,
Vitreoretinal Services,
Sankara Nethralaya,
Kolkata, India.
Email: drenm@snmail.org

Introduction

Ocular vascular occlusions after intraocular surgery are rare complications. The causative factors are difficult to identify specially after vitreoretinal procedures. Vascular occlusions are more frequent when a cardiovascular disease coexists. We present a case where a person presented with branch retinal vein occlusion (BRVO) and cystoid macular oedema (CME) after vitrectomy for rhegmatogenous retinal detachment (RRD) without any systemic predisposing factors.

Case report

A 26-year-old male presented with blurred vision in his left eye for 1 month. Distant best-corrected visual acuity (BCVA) of the left eye was counting fingers at 3 m. Fundus examination revealed total RRD in his left eye with horse shoe tears at the periphery. The patient underwent routine work-up

before surgery excluding all possible coexisting cardiovascular risk factors. Patient underwent routine 23G vitrectomy with belt buckling and silicone oil tamponade under peribulbar anaesthesia. SRF was drained through a retinotomy. The postoperative period was uneventful except that on the fifth postoperative day, few retinal haemorrhages were noted around superotemporal vessels. In his follow-up visit, after 6 weeks, BCVA in his left eye was 6/24 with an intraocular pressure of 12 mmHg. Fundus examination of the left eye showed an attached retina with sclerosed vessels in superotemporal quadrant along with retinal haemorrhages and cystic changes at macula suggestive of a superotemporal BRVO with CME. No signs of inflammation were seen in either of the eye.

Fundus fluorescein angiography (FFA) revealed a wide area of non-perfused retina (red arrow)

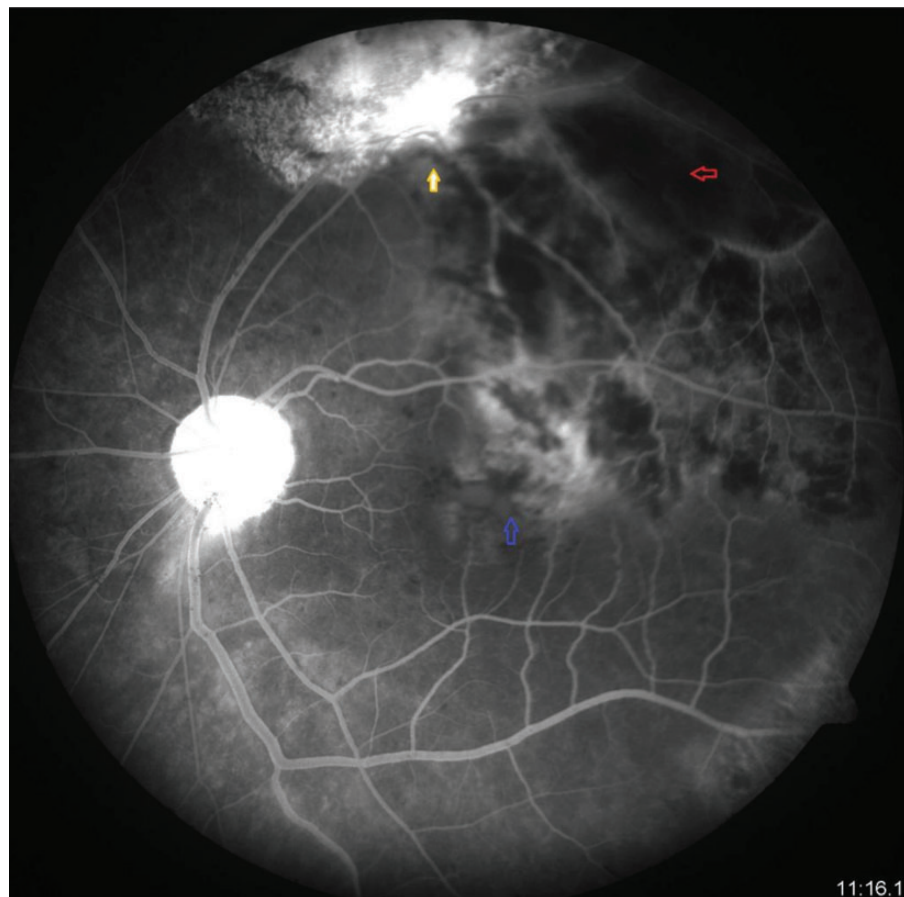


Figure 1 FFA showing nonperfused retina (red arrow), retinotomy site (yellow arrow), patelloid leakage at macula (blue arrow).

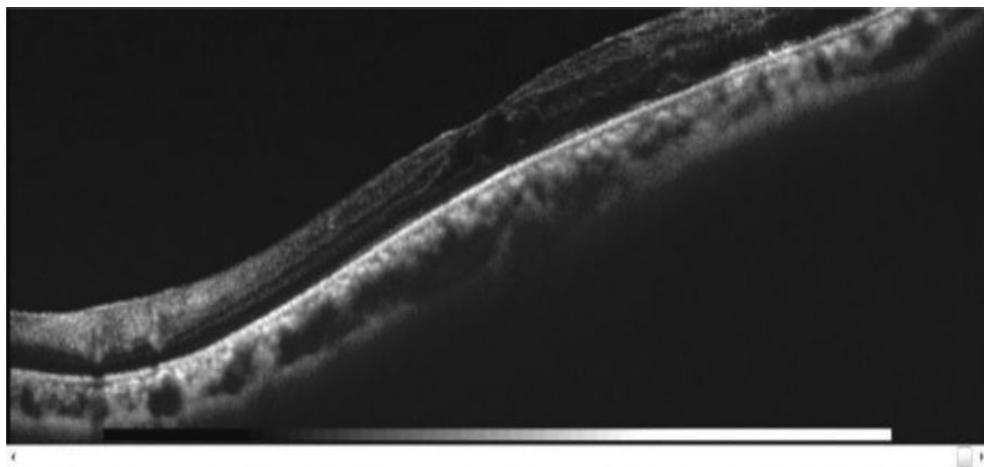


Figure 2 OCT at 6 weeks.

near the retinotomy site (yellow arrow) along with sclerosed vessels with a petaloid pattern dye leak present at fovea (blue arrow) suggestive of CME, which was confirmed by the optical coherence tomography (OCT) (Figures 1 and 2). Further systemic investigations failed to find a systemic cause. The patient was advised topical non-steroidal anti-inflammatory eye drop and was asked to review after 1 month. The OCT after 2 months showed non-resolution of macular oedema (Figure 3). He subsequently underwent silicone oil removal with an intravitreal injection of triamcinolone acetonide (2 mg) for non-resolving cystoid macular oedema.

Discussion

The primary mechanisms for BRVO are mechanical compression of vein at arterio-venous crossing by anterior rigid artery, degenerative changes

of vessel wall and/or abnormal haematological factors.¹

The main cause of impaired vision in BRVO is due to CME. CME occurs in 30% of eyes with BRVO.¹ CME can be differentiated by FFA by typical petaloid leakage pattern from cystoid degeneration which does not show leakage in FFA.

There are reported incidents of vascular occlusion after retrobulbar anaesthesia. The cause of such an episode attributed to reduction of retrobulbar blood flow velocities after retrobulbar anaesthesia.⁴ Drug-induced vasoconstriction plays a role in the decrease in ocular blood flow after peribulbar anaesthesia as does increase IOP which is probably caused by the mechanical effect of the injected volume in the orbit.⁴ Although the retinal vessels has a wide range of autoregulation under change in perfusion pressure, the autoregulation

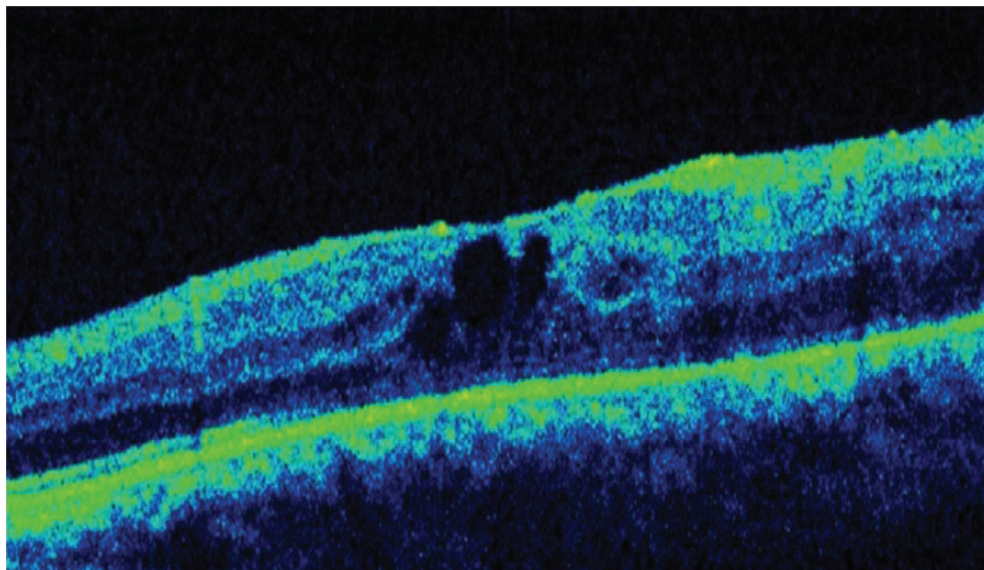


Figure 3 OCT at 2 months.

gets compromised in diseased states like diabetic retinopathy and glaucoma. And, in these situations, even a small reduction in ocular perfusion pressure, as induced by an increase in intraocular pressure, may reduce ocular blood flow. Similarly, high fluctuation of intraocular pressure is seen during vitrectomies. An increase in intraocular pressure occurs during fluid gas exchange due to a forward displacement of the lens-iris diaphragm resulting in anterior chamber flattening and secondary angle-closure glaucoma.² Anterior chamber flattening can also occur due to ciliary body oedema and choroidal swelling caused by extensive laser or cryocoagulation.

A direct vascular trauma with endolaser burn or mechanical trauma could also be a possible reason for the BRVO in our case as is evident the location of vein occlusion close to endolaser burns and the retinotomy site.

Conclusion

Surgical manipulations causing decreased retinal and choroidal blood flow as well as pressure changes and mechanical damage may act as

triggering mechanisms for retinal vein occlusions in such cases.

Vascular occlusion after intraocular surgery may occur without any associated cardiovascular disease. Affected patients should undergo systemic evaluation to rule out possible underlying systemic diseases and should be treated conventionally.

References

1. Li j, Paulus YM, Shuai Y, *et al.* New developments in the classification, pathogenesis, risk factors, natural history, and treatment of branch retinal vein occlusion. *J Ophthalmol.* 2017;2017:4936924.
2. Costarides AP, Alabata P, Bergstrom C. Elevated intraocular pressure following vitreoretinal surgery. *Ophthalmol Clin North Am.* 2004;17(4):507–12.
3. Cugati S, Wang JJ, Rochtchina E, *et al.* Ten-year incidence of retinal vein occlusion in an older population: the blue mountains eye study. *Arch Ophthalmol.* 2006;124(5):726–32.
4. Huber KK, Remky A. Effect of retrobulbar versus subconjunctival anaesthesia on retrobulbar haemodynamics. *Br J Ophthalmol.* 2005;89:719–23.
5. Findl O, Dallingner S, Menapace R, *et al.* Effects of peribulbar anesthesia on ocular blood flow in patients undergoing cataract surgery. *Am J Ophthalmol.* 1999;127:645–9.

How to cite this article Nigam E. and Das D. Retinal vein occlusion following vitrectomy for rhegmatogenous retinal detachment: a case report, *Sci J Med & Vis Res Foun* 2017;XXXV:48–50.

Some holes need no peeling: a case report of spontaneous closure of macular hole in a case of treated rhegmatogenous retinal detachment

Debmalya Das¹ and Eesh Nigam²

^{1,2}Associate Consultant,
Vitreoretinal Services,
Sankara Nethralaya,
Kolkata, India

Correspondence:
Debmalya Das,
Associate Consultant,
Vitreoretinal Services,
Sankara Nethralaya,
Kolkata, India.
Email: drdmd@snmail.org

Introduction

Full thickness macular hole (FTMH) formation is caused by tangential vitreous tractions¹ and anteroposterior tractional components.^{2,3} Surgical intervention includes vitrectomy with or without peeling of the inner limiting membrane (ILM) to relieve these tractional forces.⁴ Several small case series have described FTMH formation after vitrectomy for rhegmatogenous retinal detachment (RRD).^{5,6} In these vitrectomized eyes, the mechanism actually responsible for the formation of FTMHs remains unclear. We present a case of FTMH that developed in an eye after vitrectomy for RRD and its spontaneous closure.

Case Report

A 56-year-old man presented with RRD in his left eye with a best-corrected visual acuity (BCVA) of 20/800. On examination, total RRD with multiple horseshoe tears were seen in the temporal and inferior quadrants. He was advised and subsequently underwent vitrectomy with encircage and silicone oil tamponade for the same. Four weeks post-operation, he had an attached retina with a BCVA of 20/100. He was scheduled for a second operation for silicone oil removal (SOR), when he reported with a sudden drop in vision in his left eye with a BCVA of 20/200. Examination revealed an attached retina with an FTMH.

Optical coherence tomography (OCT) of the left eye showed a small (<200 μ m) FTMH (Figure 1).

SOR and ILM peeling with C3F8 tamponade was planned for the same. However, the patient presented with an improved BCVA of 20/40 in his left eye after a month. OCT (Figure 2) revealed a spontaneous closure of FTMH with outer retinal defect at fovea.

Discussion

Based on clinical, histopathological and OCT studies,^{2,3} it has been argued that FTMH formation is a result of tractional forces between the vitreous and retina. There are several small case series describing the development of FTMH after vitrectomy for RRD in the literature with a prevalence rate between 0.9 and 1.1%.^{7,8} In such cases, a possible mechanism of action could be direct traction on the macula during the vitrectomy for RRD.⁸ Further aetiologies include vitreoschisis and traction caused by epiretinal membrane (ERM). In the absence of cortical vitreous, another factor that may cause tangential traction leading to MH formation is the ILM.⁹ Our case had ILM striae as was demonstrated in the OCT (Figure 2).

ILM peeling, in these cases, has become the mainstay treatment for the repair of FTMHs, with better visual and anatomical success compared without ILM peeling. Spontaneous closure of FTMH was described previously in the presence of ERM; however, this phenomenon is considered to be rare.^{10,11} We believe that a small FTMH in a vitrectomized eye, such as ours, can be observed for some time before an intervention.

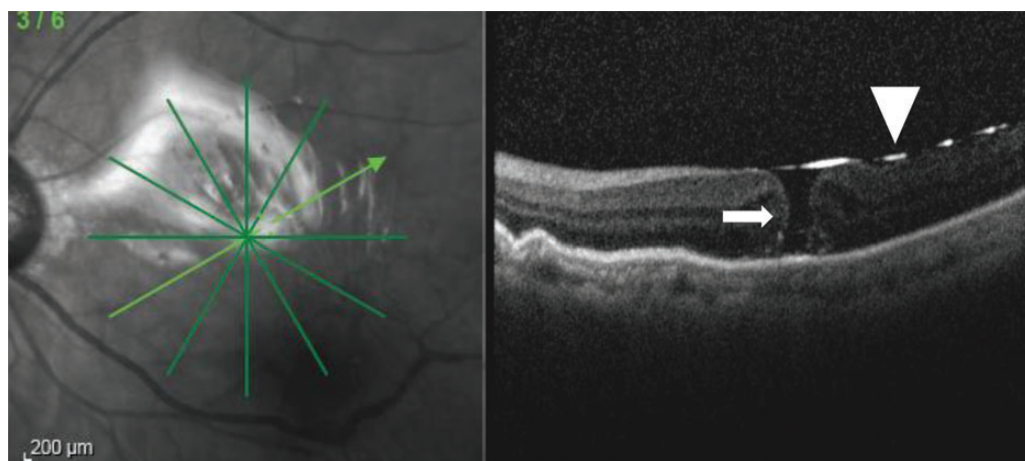


Figure 1: A small FTMH (<200 μ m) (white arrow). Oil meniscus (white arrow head) can be seen.

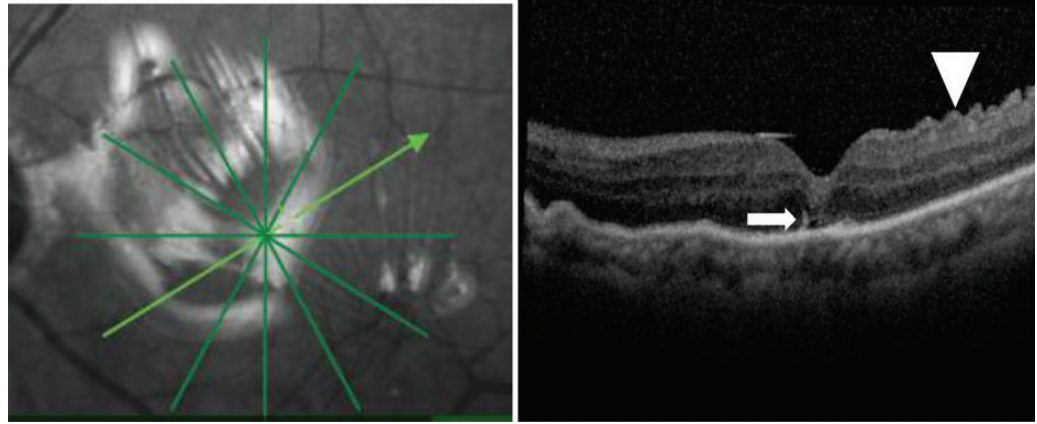


Figure 2: Closure of FTMH with outer retinal defect (white arrow) and ILM striae (white arrow head)

Conclusion

This case report has its limitations. Larger cohort studies are needed to delineate the ways in which FTMH behaves in post vitrectomized eyes. In summary, this report demonstrates that a small FTMH that may develop after vitrectomy for RRD can be observed for some time as it may close spontaneously. The pathogenesis of the formation of the holes in the absence of intact vitreous still remains unclear.

References

- Gass JD. Reappraisal of biomicroscopic classification of stages of development of a macular hole. *Am J Ophthalmol.* 1995;119:752–9.
- Smiddy WE, Flynn HW Jr. Pathogenesis of macular holes and therapeutic implications. *Am J Ophthalmol.* 2004;137:525–37.
- Gaudric A, Haouchine B, Massin P, et al. Macular hole formation: new data provided by optical coherence tomography. *Arch Ophthalmol.* 1999;117:744–51.
- Smiddy WE, Feuer W, Cordahi G. Internal limiting membrane peeling in macular hole surgery. *Ophthalmology* 2001;108:1471–6; discussion 7–8.
- Benzerroug M, Genevois O, Siahmed K, et al. Results of surgery on macular holes that develop after rhegmatogenous retinal detachment. *Br J Ophthalmol.* 2008;92:217–9.
- Rahman W, Georgalas I, da Cruz L. Macular hole formation after vitrectomy for retinal detachment. *Acta Ophthalmol.* 2010;88:e147–8.
- Benzerroug M, Genevois O, Siahmed K, et al. Results of surgery on macular holes that develop after rhegmatogenous retinal detachment. *Br J Ophthalmol.* 2008;92:217–9.
- Fabian ID, Moisseiev E, Moisseiev J, et al. Macular hole after vitrectomy for primary rhegmatogenous retinal detachment. *Retina* 2012;32(3):511–9.
- Gordon LW, Glaser BM, Ie D, et al. Full-thickness macular hole formation in eyes with a pre-existing complete posterior vitreous detachment. *Ophthalmology* 1995;102:1702–5.
- Guyer DR, de Bustros S, Diener-West M, et al. Observations on patients with idiopathic macular holes and cysts. *Arch Ophthalmol.* 1992;110:1264–8.
- Lewis H, Cowan GM, Straatsma BR. Apparent disappearance of a macular hole associated with development of an epiretinal membrane. *Am J Ophthalmol.* 1986;102:172–5.

How to cite this article Das D. and Nigam E. Some holes need no peeling: a case report of spontaneous closure of macular hole in a case of treated rhegmatogenous retinal detachment, *Sci J Med & Vis Res Foun* 2017;XXXV:51–52.

Practice pattern for managing retinal detachment: a narrative of three generations of vitreoretinal surgeons

Chetan Rao¹ and Girish Rao²

^{1,2}Senior Consultant
Sri Bhagwan Mahavir
Vitreoretinal Services,
Sankara Nethralaya,
Chennai, India

Correspondence:
Girish Rao,
Medical Director,
Sankara Nethralaya

Senior consultant,
Sri Bhagwan Mahavir
Vitreoretinal Services,
Sankara Nethralaya,
Chennai, India

The main aim of retinal detachment surgery is relieving the vitreous traction on the retinal break, opposing the retinal break to the retinal pigment epithelium and achieving retinopexy by laser or cryotherapy. The principles remain the same but the surgical treatment has evolved from the time scleral buckling (SB) technique was popularized by Charles Schepens to the introduction of parsplana vitrectomy by Robert Machemer. Furthermore, refinement of surgical procedures, instrumentation, technological advancement in vitrectomy machines, lasers, microscopes and skill enhancement of surgeon has ensured almost 100% success rate of reattachment. The purpose of this interview was to explore how the practice pattern in vitreoretinal surgery is evolving across generations in India. We sought to know the current trends in management from the experiences of vitreo-retina specialists of *three different generations* in India.



Atul Kumar

Ashish Vaidya

Amit Jain

Atul Kumar, MD, FAMS is chief & professor of ophthalmology at Dr R.P. Centre for Ophthalmic Sciences All India Institute of Medical Sciences, New Delhi. He pursued his vitreo-retinal fellowship at the University of Maryland, Baltimore. He is a vitreoretinal surgeon par excellence and has been in this field for more than 25 years.

Ashish Vaidya MS, FRCS (Edin), FMRF has been in retinal practice for the past 20 years in Mumbai at Nethra Retina and Laser Centre and is attached to Lilavati Hospital. He had his training in vitreoretina at Sankara Nethralaya.

Amit Jain, MS, FMRF has completed fellowship in vitreoretina from Sri Bhagwan Mahavir Vitreoretinal Services, Sankara Nethralaya and represents the youngest generation of vitreoretinal surgeon in this interview. He is presently working as an associate consultant in the Department of Vitreoretinal Services at Shri Ganapati Netralaya, Jalna since 2016

What are the current treatment modalities for managing rhegmatogenous retinal detachment?

Amit Jain: Rhegmatogenous retinal detachment (RRD) treatment modalities include laser barrage for peripheral, subclinical RD, pneumatic retinopexy, SB and primary vitrectomy with tamponade.

Ashish Vaidya: Most common in my practice would be vitrectomy with silicone oil followed by vitrectomy with gas, scleral buckle and the least common would be pneumoretinopexy.

Atul Kumar: There are three primary modalities for the treatment of RRD in the modern era—SB, primary vitrectomy with endotamponade and pneumatic retinopexy. A combination of SB and vitrectomy (vitrectomy–buckle) is also a popular modality.

In brief, what are the tips to choose a particular modality (SB/pneumatic retinopexy/primary vitrectomy) for managing a case of RD?

Amit Jain: For any patient presenting with RRD in OPD, my first thought is 'Is it Bucklable'. If it's a yes, then scleral buckle (SB) is my procedure of choice. My criteria for SB are peripheral depressible break/breaks, PVR (proliferative vitreo-retinopathy) not more than grade C1 (ideally PVR B or less), absence of PVD in young patients and pediatric cases. Also in cases with extensive sub-retinal gliotic bands, where removal of bands would be difficult via vitrectomy, I prefer SB, as adequate indent and treatment of breaks obviates the need for removal of these bands in many cases. I have a very high threshold for pneumatic retinopexy which include single superior break in a relatively fresh RD. Primary vitrectomy would be used in all cases which doesn't fit the SB criteria.

Ashish Vaidya: In today's era, primary vitrectomy would be the procedure of choice. The factors pushing me not to do a vitrectomy would be phakic patient, young patient, absence of a posterior vitreous detachment in which case I would do a buckle. Pneumoretinopexy would be restricted to single superior breaks and a very cooperative patient in terms of understanding the procedure and willing for resurgery.

Atul kumar: Vitrectomy as a primary modality works well in most cases, especially pseudophakic

RDs. At times, it is the only modality of use in cases such as those with extensive PVR, choroidal colobomas, choroidal detachments, giant retinal tear with rolled flap and open globe injuries, and macular pathologies induced RDs. SB is a good choice in young, phakic patients who are likely to have a tightly adherent posterior hyaloid. The single operation success rate is comparable for both modalities. Pneumatic retinopexy has an unacceptably high failure rates for use as primary modality except in select cases where retinal breaks are perfectly aligned to the vertical or horizontal meridian.

What is the role of encirclage in RD in the era of MIVS (micro-incisional vitrectomy surgery)?

Amit Jain: Complete vitrectomy is almost impossible to achieve and for me it is here that encirclage still holds a big role in the management of RRD as it helps support the ora and vitreous base thus minimizing the risk of traction and resultant break from the residual vitreous. I usually pass encirclage in almost all my RRD cases unless it is difficult to pass the encirclage due to extensive scarring (in previously operated scleral tear cases) or where 360° relaxing retinotomy is done.

Ashish Vaidya: I would still do an encirclage in inferior breaks and if the patient has PVR.

Atul Kumar: MIVS has allowed shaving vitreous close to the retina and a safe vitreous base dissection. This reduces the postoperative incidence of PVR. Nevertheless, in cases with intrinsically contracted retina, anterior PVR failed surgeries or in phakic patients with multiple peripheral breaks, an encircling element together with vitrectomy will help achieve successful retinal reattachment and avoid chances of re-detachment secondary to PVR.

What is the most important factor in improving the surgical outcome in a case of RD?

Amit Jain: I would like to divide into two parts:

Disease factor: absence of PVR.

Surgeon factor: appropriate planning of technique and commitment to the approach used helps in improving the surgical outcome.

Atul Kumar: removing all traction on the break is the most important factor for improving surgical outcome in a case of RD. 'Do it right, the first time'.

What are the current indications for using heavy density vitreous substitutes?

Amit Jain: With no personal hands on experience with heavy density vitreous substitutes, I

would like to try them in cases of inferior breaks or recurrent inferior RRDs.

Ashish Vaidya: I would use them in recurrent inferior detachments.

Atul Kumar: Earlier silicone oil, which is heavier than water, was considered useful in the treatment of complex RDs (such as those associated with extensive PVR and open globe injury) with retinal breaks and PVR primarily located in the inferior quadrant. But, in the modern era, even these cases can be adequately managed with combined vitrectomy and encirclage along with lighter than water silicone oil.

When would you use PFCL for managing an RD?

Amit Jain: absolute indications (almost): In GRT to flatten the posterior retina, in extensive PVR (PVR C,D) during membrane peeling, during ILM peeling in cases with macular hole. Relative use: PFCL is used to flatten the retina and drain subretinal fluid through primary peripheral break and thus avoid making an additional posterior drainage retinotomy.

Ashish Vaidya: I primarily do a posterior retinotomy and do a fluid-gas exchange. PFCL would be used for a giant retinal tear or with other adjunctive conditions like a nucleus or a lens drop or in management of intraocular foreign body.

Atul Kumar: PFCL is a useful adjuvant in the management of RD and acts as a 'third hand' of the surgeon. It is of invaluable use in the management of detachments with giant retinal tears, dislocated lens or IOL and retained intraocular foreign body. It is also useful during ILM peeling in detached retina, for placing ILM flaps over macular holes in myopic macular hole retinal detachments and in the management of subretinal bleeding.

What are the factors for choosing silicone oil versus gas as tamponade?

Amit Jain: Personally prefer oil in almost every case unless it is a case of simple RRD with macular hole as gas provides better tamponade for macular hole closure.

Ashish Vaidya: In the Indian scenario with patients not complying for positioning and poorer follow-ups, I would prefer silicone oil in most patients. It also gives them earlier visual rehabilitation than gas. Gas would be the first choice for superior or posterior retinal breaks.

Atul Kumar: The choice of tamponade depends on the age of the patient, ability to maintain post-operative positioning, location and extent of the break, PVR at the time of surgery, presence of choroidal detachment, phakic status and fellow eye status. (Silicon oil may be preferred in

pediatric patients, complex RDs like GRT and RD with CD and in one-eyed patients.)

What are the major innovations in the management of RD in the new millennium?

Amit Jain: Use of 23–27G MIVS surgery with better instrumentation provides superior fluidics and reduces surgical trauma and hastens post-operative recovery.

- 1 Addition of valves to the trocar system thus allowing a closed-system vitrectomy surgery.
New cutter designs with larger port areas to fasten vitrectomy, location of port closer to the tip allowing it to be used even in membrane dissections along with increased stability when around mobile retina. Higher cut rates and varying duty cycles with open or closed bias help in extensive vitreous shaving or membrane dissection.
- 2 Advances in the viewing systems with newer wide-angle contact and non-contact systems.
- 3 Higher lumen light sources provide excellent view. Chandelier also comes with advantage of bimanual surgery in difficult situations/extensive PVR.
- 4 Postoperatively, OCT has become an important diagnostic tool to look for residual subretinal fluid in chronic RD cases where functional outcome is not in accordance with anatomical success.
- 5 Macular buckle in cases of RD associated with high myopia and macular hole-history revisited.

Ashish Vaidya: MIVS with safer and faster vitrectomy and more delicate control in which one can go close to the retina and shave the vitreous base has tremendously changed the outcome of the surgeries. Also one must keep in mind that patient awareness is increasing and we are seeing more patients with a recent decrease in vision. More patients are seen with pseudophakia and RD. MIVS enables us to do a better vitrectomy and also reduces the lens-related complications like cataract or lens touch which were more common earlier.

Atul Kumar: The development of high-speed (upto 10,000/- cuts per min) small-gauge duty cycle-controlled vitrectomy systems with better fluidics is the only significant and path breaking

development in the last two decades in the management of RD.

Innovations in buckling:

- 1 Chandelier-assisted buckling
- 2 Suprachoroidal buckling (Injecting hyaluronate in suprachoroidal space corresponding to retinal break.

Innovations in vitrectomy:

- 1 Macular buckle for macular hole RDs
- 2 Use of microscope-intergrated intraoperative OCTs (MiOCT)
- 3 Ngenuity Heads-up digital-assisted vitrectomy surgery
- 4 High-frequency electric welding for retinopexy

What are the preoperative evaluations and checks that are specific for managing RD in paediatric patients?

Amit Jain:

- 1 Age of patient as positioning won't be possible in very small kids.
- 2 Cause of RD—trauma, etc.
- 3 Associated syndromes—Marfan syndrome, Stickler syndrome, etc.
- 4 Associated ocular anomalies—microcornia, coloboma.
- 5 Location of breaks.
- 6 Presence of posterior vitreous detachment.
- 7 Grade of PVR

Ashish Vaidya: A complete paediatric systemic evaluation and fitness for anaesthesia would be a must for these patients including an X-ray chest. The surgery also needs to be done in a set-up which is geared for giving general anaesthesia to children and has an ICU facility at hand.

Atul Kumar: Preoperative evaluation for cause of RD and confirming existence of RRD, rule out tumour, evaluation of extent of PVR (if required with the help of ultrasound biomicroscopy for identifying anterior PVR), lens status and evaluation of fellow eye. Wide field imaging and angiography (Retcam or UltraWide field imaging) may help to document and rule out secondary causes. An examination under anaesthesia may help to formulate the plan.

How to cite this article Rao C. and Rao G. Practice pattern for managing retinal detachment: a narrative of three generations of vitreoretinal surgeons, *Sci J Med & Vis Res Foun* 2017;XXXV:53–55.



**Vitreoretina Services,
Sankara Nethralaya,
Kolkata, India**



Sri Bhagwan Mahavir Vitreoretinal Services,

Sankara Nethralaya,

Chennai, India