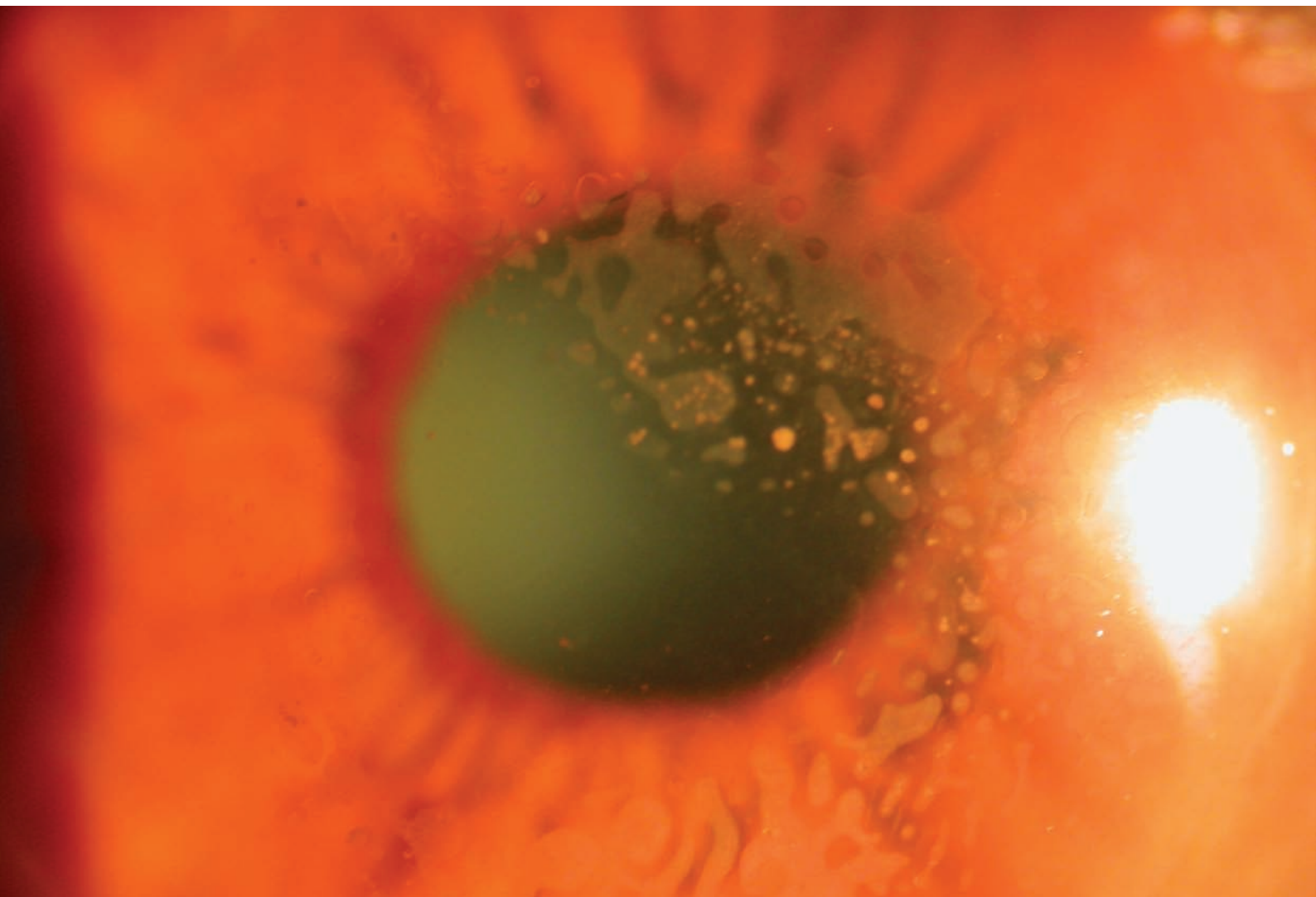


insight

Scientific Journal of

MEDICAL & VISION RESEARCH FOUNDATIONS



insight

Scientific Journal of **Medical & Vision Research Foundations**

Year: 2014

Issue: Vol. XXXII | No. 2 | June 2014 | Pages 19–32

Editor: Parthoprati Dutta Majumder

Typeset at: Techset Composition India (P) Ltd., Chennai, India

Printed at: Gnanodaya Press, Chennai, India

©Medical and Vision Research Foundations



Sankara Nethralaya – The Temple of the Eye.

It was in 1976 when addressing a group of doctors, His Holiness Sri Jayendra Saraswathi, the Sankaracharya of the Kanchi Kamakoti Peetam spoke of the need to create a hospital with a missionary spirit. His words marked the beginning of a long journey to do God's own work. On the command of His Holiness, **Dr. Sengamedu Srinivasa Badrinath**, along with a group of philanthropists founded a charitable not-for-profit eye hospital.

Sankara Nethralaya today has grown into a super specialty institution for ophthalmic care and receives patients from all over the country and abroad. It has gained international excellence and is acclaimed for its quality care and compassion. The Sankara Nethralaya family today has over 1400 individuals with one vision – to propagate the Nethralaya philosophy; the place of our work is an Alaya and Work will be our worship, which we shall do with sincerity, dedication and utmost love with a missionary spirit.

Contents

Guest Editorial: The Tale of Refractive Surgery <i>Prema Padmanabhan</i>	19
Major Review: MicroRNA: Potential Therapeutics of Eye Cancer <i>Swathi Lingam</i>	20
Tips and Tricks: Tips and Pearls in Corneal Examination <i>A. Shweta, B. Sumanta and A. Bharti</i>	23
Case Report: Spontaneous Resolution of Congenital Glaucoma <i>L. Vijaya and M. Baskaran</i>	25
Case Report: Unilateral Full Thickness Macular Hole in Association with Serpiginous Choroiditis <i>P. Ranganathan and J. Biswas</i>	27
Residents' Corner: Intravitreal Medications in Uveitis <i>A. Maheshwari</i>	29
Optics & Refraction: Cycloplegic Refraction in Children <i>L. Jayalakshmi, N. Kalpa and R. Srikanth</i>	30

Inquiries or comments may be mailed to the editor at insighteditor@snmail.org



Cover photo: Mr. M.S. Krishna, Senior photographer,
Department of Ophthalmic Photography, Sankara Nethralaya

The Tale of Refractive Surgery

Prema Padmanabhan

Director, Department of Cornea
and Refractive Surgery,
Sankara Nethralaya

Correspondence to:
Prema Padmanabhan,
Medical Director
Sankara Nethralaya,
Chennai 600006,
India.
E-mail: drpp@snmail.org



“It was the best of times, it was the worst of times, it was the age of wisdom, it was the age of foolishness, it was the epoch of belief, it was the epoch of incredulity, it was the season of Light, it was the season of Darkness, it was the spring of Hope, it was the winter of Despair....” This could well be a Dickensian summary of “The Tale of Refractive Surgery”.

It would be no exaggeration to say that no other field in Ophthalmology has seen so many changes in so short a time as Refractive Surgery

has in the last 25 years. Once considered an experimental hobby, it has gradually gained a level of acceptance even among its most vocal critics. It has, in this short span of time, become the most commonly performed elective procedure done on the human body. A meta-analysis of the USFDA approved Lasik device studies across the globe 8 years ago, found that 96% of patients reported satisfaction. With improved technology that is used today, that figure would be even higher. This can only mean that refractive surgery has met the physical, emotional and financial expectations of its clientele.

Ametropia is now correctable by a myriad surgical techniques—each more clever in design and imaginative in name than the other. Although today the term “Refractive Surgery” is almost synonymous with Laser Refractive Surgery, there are several non-laser techniques as well that a surgeon can choose from. The multiple procedures and their acronyms make for a colorful landscape, but they could all fall into one of four broad categories—incisional (RK being the most notorious and AK the most handy), thermal (like CK that was born only to be buried), lamellar (which began with ALK but soon gave way to Laser Refractive Surgery in all its forms) and intraocular surgery (IOLs that may or may not replace the crystalline lens). With so many choices, the challenge, in Refractive Surgery, lies in choosing the appropriate procedure for each eye. Sometimes, however, the bigger challenge lies in determining the appropriateness of refractive surgery itself for the eye. Failure to do so has resulted in catastrophes. But the more genuine difficulty in “smelling the rat” has often resulted in the landmine blowing into the surgeons’s face. Iatrogenic keratectasia is probably the most feared—and embarrassing—example of a complication resulting, most often, from improper patient selection. There

are more types of diagnostic gadgets that the surgeon can now use for patient screening and selection. The proper interpretation of the ‘displays’ on some of them can be more confusing than is apparent and calls for an understanding of its working principle and equally, of its limitations.

When the right patient and the most suited procedure are chosen, every patient deserves a detailed counseling. Just as it is important for the surgeon to understand the needs and expectations of the patient, it is no less important for the patient to understand the possibilities and limitations of the procedure. Disclosing the unvarnished truth about possible side-effects is a moral responsibility, we owe our patients and sets the patients expectations to more realistic levels.

The introduction of the Femtosecond laser has raised the bar in terms of precision and has opened new windows of possibilities. The femtosecond laser allows the surgeon to choose the diameter, shape, thickness, depth, angle and location of corneal flaps and hinges and makes customized laser refractive surgery more achievable than it earlier was.

Extending the versatility of the Femtosecond laser to perform flapless refractive surgery by extracting a lenticule fashioned entirely by the femtosecond laser, may be an important milestone in the journey of Refractive surgery. By avoiding flap-related complications, it would enhance the safety of the procedure, but we do need to wait for the results of current clinical trials.

The possibilities are mind-boggling. But unless each new procedure passes the test of scientific scrutiny and critical analysis, unless well-designed studies with clear documentation are healthily discussed, unless there is an honest self-reporting of failures and complications, we would be guilty of creating an ophthalmic Frankenstein.

The complexity of the optical design of the human eye is even more mind-boggling. Novel ideas, brilliant technology, deft surgery have not been able to improve the quality of the biological optical system of the human eye, at least until now. Even as we applaud human achievement and serendipity, let us pause for a moment in silent reverence for all that the cornea has given and forgiven.

How to cite this article Prema P. The Tale of Refractive Surgery, *Sci J Med & Vis Res Foun* 2014;XXXII:19.

MicroRNA: Potential Therapeutics of Eye Cancer

Swathi Lingam

Swathi Lingam,
Project Assistant,
Department of Ocular Pathology

Correspondence to:
Swathi L, Project Assistant,
Department of Ocular Pathology.
E-mail: swathi.lingam89@gmail.
com

MicroRNAs (miRNAs) are small single stranded nucleotides that are ~22 base pairs long. They were first identified in *Caenorhabditis elegans*.¹ Functionally, they are involved in post transcriptional regulation of gene expression by binding to the 3' untranslated regions of transcribed mRNA. Mature miRNA also interact with Argonaute proteins, and are inducted into the RNA induced silencing complex which is involved in gene silencing.² Gene silencing occurs when a mutation causes the gene to lose its function. Recently, miRNAs have been found to be associated with diseases such as cardiovascular disease,³ metabolic diseases⁴ and cancer.⁵

Retinoblastoma

Studying the role of miRNA in retinoblastoma could be very important since it has a potential for development into a treatment strategy. The earliest report of an association between miRNA and retinoblastoma was made in the year 2009 by Dalgard *et al.* They investigated the role of miR-34a and were able to identify its differential expression in retinoblastoma cell lines, and comprehensively proved that it acts as a tumor suppressor miRNA. miR-34a is associated with p53, a known tumor suppressor gene, whose pathway is inactivated in a subset of retinoblastoma tumors. As a result of their study, it was possible to hypothesize that increasing miR-34a expression can possibly activate the p53 tumor suppression pathway, and ultimately lead to cancer cell apoptosis⁷ thus paving way for a possible future miRNA-based therapy of retinoblastoma. Just like miR-34a, miR-449a and miR-449b are also tumor suppressor miRNA. Their over expression in retinoblastoma cell lines has been associated with decreased cell proliferation and increased apoptosis.⁸ Since miRNAs are regulators of gene expression, their interactions with genes involved in retinoblastoma have been studied. One such study identified miR-365b-3p, an miRNA that is down regulated in retinoblastoma, and interacts with PAX6, a gene that is involved in

retinoblastoma development. It was found that PAX6 expression was inhibited by this miRNA, and that it functioned as a tumor suppressor.⁹

Cancer associated miRNAs are of two types; those associated with oncogenes (called onco-miRNA's or oncomirs), and those linked to tumor suppressor genes, as described in the previous section.

The miR-17-92 cluster is a cluster of oncogene associated miRNA, which has been shown to be involved in retinoblastoma. The first study that indicated this association was carried out by Conkrite *et al.* in the year 2011. They were able to prove that *Rb* gene deletion leads to an increase in the levels of the polycystronic miR-17-92 cluster. The expression of these miRNA appeared to be directly proportional to the rate of disease progression *in vitro*, and in an *Rb*⁻ mouse model.¹⁰

Epithelial cell adhesion molecule (EpCAM) is a glycoprotein that is expressed only in epithelial cells and epithelial neoplasms. In retinoblastoma, it was identified as a possible cell surface marker, and its regulation of the miR-17-92 cluster was studied. It was found that the miR-17-92 cluster can be positively correlated to EpCAM expression, and is involved in retinoblastoma progression *in vitro*.¹¹ This is a promising result since this correlation can be used as a potential target for retinoblastoma therapy. If EpCAM is knocked down, it will lead to the reduction of miR-17-92, which in turn can cause tumor regression. This effect was observed *in vitro*, but has to be studied in animal models before it can be taken to the clinical trial level. These tumor suppressor and onco-miRNA appear to be useful targets for future retinoblastoma therapy. miRNA-based therapy can be used independently or in conjunction with current forms of therapy to improve the quality of life for a retinoblastoma patient.

Identification of miRNA that are differentially expressed in retinoblastoma is possible using microarray technology. This helps in the identification of novel miRNA, consequently increasing the number of miRNA that can be targeted for

	miRNAs associated with oncogenes	miRNAs associated with tumor suppressor genes
Examples	miR-17-92 cluster	miR-34a, miR-449a, miR-449b, miR-365b-3p, miR-9, miR-182, miR-124a
Role in eye cancer (experimental)	Progression of retinoblastoma by overexpression due to <i>Rb</i> gene deletion	Suppression of retinoblastoma and/or uveal melanoma progression through interactions with tumor suppressor gene pathways

therapy. On comparing 12 retinoblastoma tumors to 3 normal retinae, Martin *et al.*¹² were able to identify 41 differentially expressed miRNA in retinoblastoma tissue.

miRNA released into the serum are also emerging as possible biomarkers of disease. In an effort to identify serum biomarkers for retinoblastoma, microarray technology was utilized, and yielded 45 differentially expressed miRNA in retinoblastoma serum compared with normal age matched serum. Of these, 21 were upregulated, and 24 were down regulated. It was also possible to identify the gene targets of these miRNA.¹³ This information is invaluable as it opens many doors for research into serum biomarkers for retinoblastoma.

Uveal melanoma

Melanoma is a cancer of pigment cells (melanocytes). In the eye, this cancer originates from the melanocytes in the uvea (iris, ciliary body and choroid). The treatments of choice for uveal melanoma are local radiation using Iodine 125 plaques, and in extreme cases, eyeball removal. miRNAs are also being investigated as possible therapeutic targets for uveal melanoma. miR-34a was previously correlated with tumor suppression in retinoblastoma. Two members of the same family, namely miR-34b/c have been associated with suppression of uveal melanoma migration and cell proliferation. It was found that they act as tumor suppressors through the down regulation of several genes involved in the cell cycle.¹⁴ Just as in retinoblastoma, over expression of these miRNA can help in disease regression.

Nuclear factor kappa B (NF- κ B) is a transcription factor family that is involved in cell proliferation, angiogenesis and tumor metastasis. NF- κ B1, a member of this family is a target of miR-9, which is associated with tumor suppression in uveal melanoma. Liu *et al.* showed that expression of miR-9 can be associated with tumor suppression through its interaction with NF- κ B1. This same group was also able to show that miR-9 inhibits genes in the NF- κ B pathway, such as vascular endothelial growth factor A, MMP-2 and MMP-9 (matrix metalloproteinase). Such an association makes miR-9 a suitable target for treatment of uveal melanoma.¹⁵

Another tumor suppressor miRNA found to inhibit uveal melanoma progression *in vitro* is miR-182. Yan *et al.* were able to prove that on transfecting miR-182 into uveal melanoma cell lines, there was increased cell cycle arrest and apoptosis. Furthermore, they were able to identify that miR-182 works by targeting the 3' UTR regions of MTF, BCL2 and Cyclin D2, which are involved in tumor progression. The expression of miR-182 is dependent on p53 expression, which is a known tumor suppressor gene.¹⁶

miR-124a is yet another tumor suppressor that is involved in uveal melanoma tumor suppression. In an *in vitro* study, transfecting uveal melanoma cell lines with miR-124a showed a significant decrease in tumor cell growth, invasion and migration. In an *in vivo* study, tumor suppression was observed. It was found to be epigenetically regulated during melanoma progression, leading to its down regulation.¹⁷

Conclusion

Since the discovery of miRNA little over a decade ago, the fact that they are associated with disease conditions has opened up an entire area of research. There are exciting possibilities for disease treatment and early diagnosis by using miRNA as biomarkers. This approach is especially important in cancer, where associated miRNA are of two types, oncomiRNA and tumor suppressor miRNA. By regulating their target genes, oncomiRNA promote tumor progression, whereas tumor suppressor miRNA have the opposite function.

In the section above, several tumor suppressor and oncomiRNA involved in retinoblastoma and uveal melanoma have been described. Their role in tumor progression, their possible tumor biology, and what this means for treatment have been hypothesized. Theoretically, if an oncomiRNA is down regulated, and a tumor suppressor miRNA is upregulated, tumor progression should be arrested. However, the process is never that straightforward. The pathways involved in tumor progression are complex, and there are several regulatory mechanisms. Also, this cancer related miRNA have many gene targets, and just turning them on and off may not necessarily have the expected effect on tumor progression. What is required is a cumulative approach involving manipulation of oncogenes and tumor suppressor genes and controlling expression of tumor suppressor miRNA, oncomiRNA and their target genes. Once a successful combination leading to tumor progression arrest/cancer cell apoptosis has been identified, it has to show a significant effect in cell lines, in animal models and lastly, human clinical trials before it can be used as a form of therapy.

The use of circulating miRNA in blood plasma and serum as biomarkers of early stage disease, however, is a more achievable target. Since cancer miRNAs are indicators of the disease, accurately quantifying their expression levels can throw light on the presence of the disease, and the stage of the cancer. This is a very important discovery as it can eliminate the need for invasive methods of diagnosis. This is important in tumors such as retinoblastoma where tumor sampling is not possible.

In conclusion, miRNA-based therapy and diagnosis could be the future in the fight against cancer. miRNA and gene manipulation will have

to be used in conjunction with existing treatment strategies, and this will be a potent combination.

References

1. Lee RC, Feinbaum RL, Ambros V. The *C. elegans* heterochronic gene *lin-4* encodes small RNAs with antisense complementarity to *lin-14*. *Cell* 1993; 75(5): 843–854.
2. Kim VN, Han J, Siomi MC. Biogenesis of small RNAs in animals. *Nat Rev Mol Cell Biol* 2009; 10(2): 126–139.
3. Quiat D, Olson EN. MicroRNAs in cardiovascular disease: from pathogenesis to prevention and treatment. *J Clin Invest* 2013; 123(1): 11–18.
4. Fernandez-Hernando C, et al. MicroRNAs in metabolic disease. *Arterioscler Thromb Vasc Biol* 2013; 33(2): 178–185.
5. Chen PS, Su JL, Hung MC. Dysregulation of microRNAs in cancer. *J Biomed Sci* 2012; 19: 90.
6. Lohmann DR, Gallie BL. Retinoblastoma 1993.
7. Dalgard CL, et al. Differential microRNA-34a expression and tumor suppressor function in retinoblastoma cells. *Invest Ophthalmol Vis Sci* 2009; 50(10): 4542–4551.
8. Martin A, et al. MicroRNAs-449a and -449b exhibit tumor suppressive effects in retinoblastoma. *Biochem Biophys Res Commun* 2013; 440(4): 599–603.
9. Wang J, et al. miR-365b-3p, down-regulated in retinoblastoma, regulates cell cycle progression and apoptosis of human retinoblastoma cells by targeting PAX6. *FEBS Lett* 2013; 587(12): 1779–1786.
10. Konkrite K, et al. miR-17~92 cooperates with RB pathway mutations to promote retinoblastoma. *Genes Dev* 2011; 25(16): 1734–1745.
11. Kandalam MM, et al. Oncogenic microRNA 17-92 cluster is regulated by epithelial cell adhesion molecule and could be a potential therapeutic target in retinoblastoma. *Mol Vis* 2012; 18: 2279–2287.
12. Martin J, et al. Differentially expressed miRNAs in retinoblastoma. *Gene* 2013; 512(2): 294–299.
13. Beta M, et al. Identification and insilico analysis of retinoblastoma serum microRNA profile and gene targets towards prediction of novel serum biomarkers. *Bioinform Biol Insights* 2013; 7: 21–34.
14. Dong F, Lou D. MicroRNA-34b/c suppresses uveal melanoma cell proliferation and migration through multiple targets. *Mol Vis* 2012; 18: 537–546.
15. Liu N, et al. MicroRNA-9 suppresses uveal melanoma cell migration and invasion through the NF-kappaB1 pathway. *Oncol Rep* 2012; 28(3): 961–968.
16. Yan D, et al. Role of microRNA-182 in posterior uveal melanoma: regulation of tumor development through MITF, BCL2 and cyclin D2. *PLoS One* 2012; 7(7): e40967.
17. Chen X, et al. MicroRNA-124a is epigenetically regulated and acts as a tumor suppressor by controlling multiple targets in uveal melanoma. *Invest Ophthalmol Vis Sci* 2013; 54(3): 2248–2256.

How to cite this article Swathi L. MicroRNA: Potential Therapeutics of Eye Cancer, *Sci J Med & Vis Res Foun* 2014; XXXII:20–22.

Tips and Pearls in Corneal Examination

A Shweta, B Sumanta and A Bharti

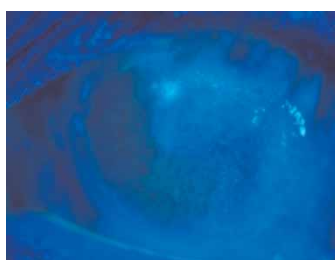
Associate Consultant,
Department of Cornea & Ocular
Surface Disorder,
Sankara Nethralaya

Correspondence to:
Shweta Agarwal,
Associate Consultant,
Department of Cornea & Ocular
Surface Disorder,
Sankara Nethralaya.
E-mail: drsal@snmail.org

Examination of an eye is like a jigsaw puzzle. Every symptom and sign gives you a clue to complete your puzzle. A complete examination would include a detailed history, visual acuity, slit lamp examination, intraocular pressure measurements, fundus evaluation and ancillary tests like staining and schirmers.

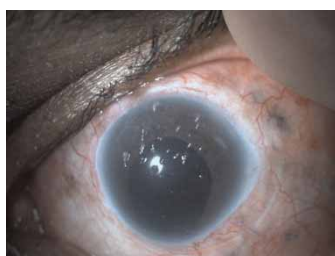Let us go through some common corneal signs and see what each one tells us, however, it is beyond the scope of this article to cover all diseases.

1. Superficial punctate keratitis:



Sign	Symptoms	Differential diagnosis
Minimally raised superficial punctate staining pattern	Irritation FB sensation Watering Photophobia	<i>Lids:</i> concretions, granuloma, papillae, foreign body, blepharitis, meibomian gland disease <i>Conjunctiva:</i> conjunctivochalasis <i>Ocular surface conditions:</i> dry eye, allergic or infective kerato conjunctivitis, viral keratitis contact lens induced, toxic medicamentosa

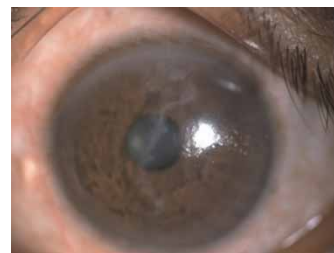2. Filamentary keratitis: filaments appear as mucoid deposits adherent to the corneal surface.



Etiology	Disease	Distribution of filaments
Viral	Herpes simplex	Usually single filament
Trauma	Corneal abrasion	Usually single layer
Surgery	Multiple surgeries	Diffuse
Others	Dry eye	Interpalpebral
	Superior limbic keratoconjunctivitis	Upper one third of cornea
	Neurotrophic keratopathy	Interpalpebral
	Toxic medicamentosa	Lower one third of cornea

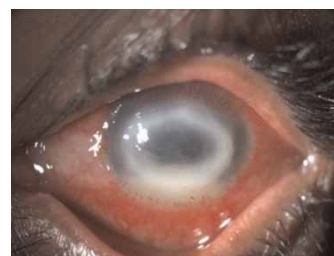3. Epithelial defect: a breach in the continuity of the epithelium is called as an epithelial defect.

Dendritic: herpes simplex, herpes zoster, healing epithelial defect

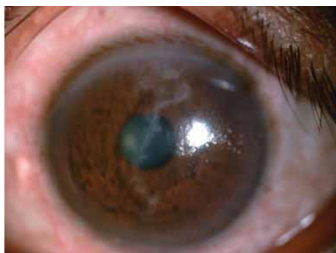

4. Ulcer: an epithelial defect associated with inflammation. An ulcer has varied presentations. But based on its location, edges, shape, depth of involvement associated hypopyon a fair idea of etiology can be made.

Ring ulcer: fungal, acanthamoeba, pseudomonas, severe corneal burn, corneal foreign body

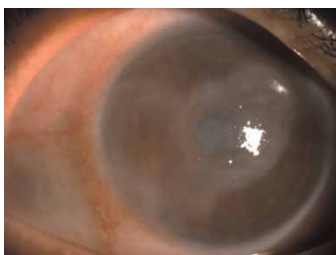

5. Scar: final outcome of any inflammatory lesion. Depending on the layer of corneal involvement it is three types nebular, macular and leucomatous.



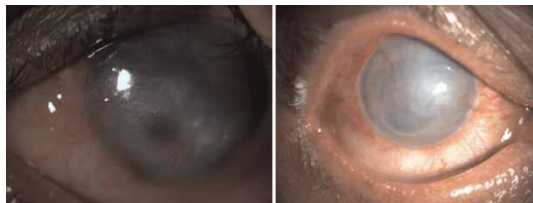Sign	Symptom
White opaque, no epithelial defect, well-defined margins, quiet eye	Minimal photophobia no pain or watering

6. Edema: due to accumulation of fluid in corneal stroma and/or epithelium.



Etiology	Presentation
Primary endothelial failure (Fuchs, CHED)	Primarily stromal, diffuse progressive
Secondary endothelial failure (viral keratitis, trauma)	Primarily stromal, focal or diffuse
Elevated IOP with normal endothelium	Primarily epithelial, microcytic edema

7. Vascularization:



Types of vascularization	Etiology
Superficial	LSCD, CI wear, blepharitis, chronic inflammation
Deep	Interstitial keratitis, viral keratitis

Further reading

1. Krachmer Jay H, Mannis Mark J, Holland Edward J. Cornea, vol 1; Examining and imaging the cornea and external eye.
2. Basic and Clinical science course. AAO. External disease and cornea (section 8) 2013–2014.

How to cite this article Shweta A, Sumanta B, Bharti A. Tips and Pearls in Corneal Examination, *Sci J Med & Vis Res Foun* 2014;XXXII:23–24.

Spontaneous Resolution of Congenital Glaucoma

L Vijaya and M Baskaran

Correspondence to: Vijaya L,
Director, Sri Jadhavbai Nathmal,
Singhvi Glaucoma Services,
Sankara Nethralaya, Chennai
600006, India.
E-mail: drlv@snmail.org

Abstract

To report clinical features in five eyes of three cases with spontaneously resolved congenital glaucoma. All eyes showed megalocornea, deep anterior chambers and refractive status of either high myopia or astigmatism. Gonioscopy revealed high anterior insertion of iris with iris processes. Three eyes showed Haab's striae, two eyes showed features of Reiger's anomaly. Repeated intraocular pressure measurements were in normal range. Congenital glaucoma can resolve on its own leaving behind features suggestive of previous raised intraocular pressure.

Introduction

Congenital glaucoma occurs in one out of 10,000 births and prevalence is 0.01–0.04% of general ophthalmic patients.¹ Spontaneous resolution of such congenital glaucoma has rarely been reported in the literature.^{1,2} Most of the times such cases have been diagnosed on a presumptive basis, that is, from subsequent findings rather than actual documentation of resolution of glaucoma.³ We report five eyes of three patients where in typical clinical signs of congenital glaucoma were seen with consistent normal intraocular pressure indicating the spontaneously resolved condition. None of them had surgery or medical treatment for raised intraocular pressure prior to presentation.

Case 1: A 15-year old male with history of defective vision in left eye and enucleation of right eye at the age of 7 years. Examination of left eye revealed visual acuity of 6/9 with a refractive correction of +1.00 diopter sphere and –5.00 diopter cylinder at axis of 90°. Slit lamp biomicroscopy showed megalocornea, Haab's striae and a deep anterior chamber. Gonioscopy revealed anterior insertion of iris with prominent iris processes. Intraocular pressure was 17 mmHg with applanation tonometer. Optic nerve head evaluation with 90 diopter lens using slit lamp biomicroscopy showed cup disc ratio of 0.6:1 with healthy neural rim.

Case 2: A 9-year old female presented with a history of defective vision in both eyes. Examination revealed visual acuity of 3/36 with –7.00 diopter sphere in right eye 6/36 with –14.00 diopter sphere in the left eye. Slit lamp biomicroscopy showed megalocornea, deep anterior chamber and corectopia. Applanation tonometry showed intraocular pressure of 17 and 18 mmHg in the right and left eyes, respectively.

Gonioscopy revealed anterior insertion of iris with iris process. Optic discs were healthy.

Case 3: A 3-year old presented with a history of blunt trauma to the left eye 2 months back. Examination showed that the child was able to fixate and follow the objects well with right eye while there was no perception of light in the left eye. The refractive error in the right eye was –2.00 diopters sphere with –2.00 diopter cylinder at axis of 20°. Slit lamp biomicroscopy showed megalocornea, Haab's Striae (Fig. 1) and a deep anterior chamber in both eyes. In addition, the left eye showed complicated cataract. Gonioscopy revealed anterior insertion of iris with iris processes (Fig. 2) the right eye optic nerve head showed glaucomatous cupping and ultrasonography of the left eye revealed total retinal detachment.

Megalocornea, Haab's striae with axial myopia or astigmatism are suggestive of previously raised intraocular pressure. Breaks in Descemet's membrane (Haab's Striae) from increased intraocular pressure rarely occur after age 3.⁴ This suggests all five eyes possibly had raised intraocular pressure before 3 years of age. Lockie and Elder² reported three cases of documented spontaneous resolution of glaucoma, out of the three cases one case was seen before and after disappearance of glaucoma. Their series did not mention about gonioscopic features. Primary infantile glaucoma has very characteristic angel features.¹ The presence or absence of congenital glaucoma can be judged

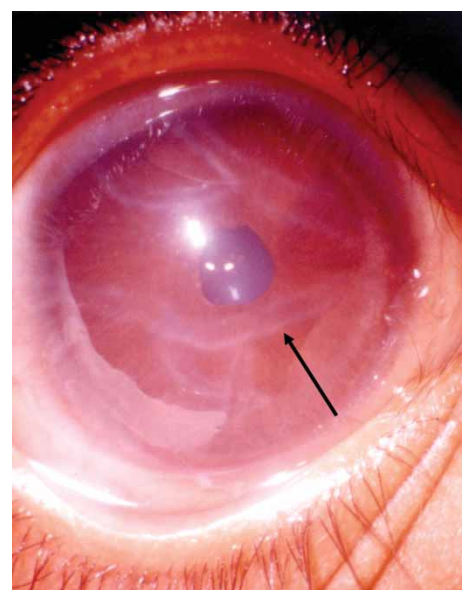


Figure 1. Case 3: external photography of the right eye showing Haab's Striae.

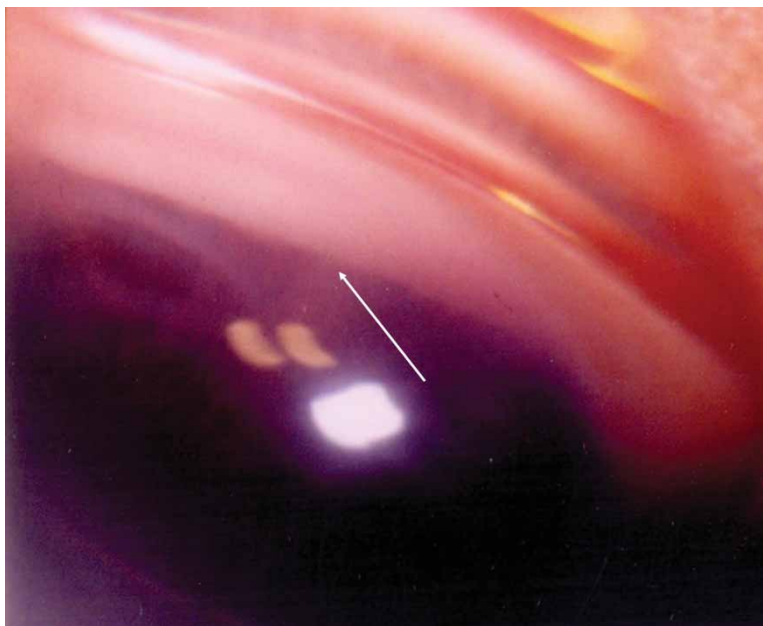


Figure 2. Case 3: gonioscopic photography of the right eye showing anterior insertion of iris.

from non-gonioscopic signs and symptoms, but gonioscopy confirms the diagnosis of congenital glaucoma. In our series, all eyes showed anterior insertion of iris, which eliminates possibility of secondary glaucoma during childhood and confirms the diagnosis of congenital glaucoma. The mechanism of spontaneous resolution is unclear; it is thought to be due to continuous development of angle even after birth with disappearance of the embryological tissue that causes precanalicular obstruction.⁵ Spontaneous resolution of congenital glaucoma is definite entity, though rare.

References

1. De Luise VP, Anderson DR. Primary infantile glaucoma (congenital glaucoma). *Surv Ophthalmol* 1983; 28: 1–19.
2. Lockie P, Elder J. Spontaneous resolution of primary congenital glaucoma. *Aust N Z J Ophthalmol* 1989; 17(1): 75–77.
3. Malbran E, Dodd R. Megalocornea and its relation to congenital glaucoma. *Am J Ophthalmol* 1960; 49: 908–921.
4. Waring GD, Laibson PR, Rodriguez M. Clinical and pathological alteration of Descemet's membrane. *Surv Ophthalmol* 1974; 18: 325–368.
5. Anderson DR. The development of the trabecular meshwork and its abnormality in primary infantile glaucoma. *Trans Am Ophthalmol Soc* 1981; 79: 458–485.

How to cite this article Vijaya L, Baskaran M. Spontaneous Resolution of Congenital Glaucoma, *Sci J Med & Vis Res Foun* 2014;XXXII:25–26.

Unilateral Full Thickness Macular Hole in Association with Serpiginous Choroiditis

P Ranganathan and J Biswas

Correspondence to:
Biswas J,
Director,
Department of Uvea,
Sankara Nethralaya,
Chennai 600006,
India.
E-mail: drjb@snmail.org

Introduction

Serpiginous choroiditis is a bilateral chronic progressive and recurrent disease of unknown etiology affecting the retinal pigment epithelium, choriocapillaries and choroid. Macular serpiginous choroiditis is a variant of serpiginous choroiditis. Macular hole is extremely rare in serpiginous choroiditis.¹ We report a case of unilateral serpiginous choroiditis with macular hole. This is the first case of macular hole in serpiginous choroiditis reported in Indian literature to the best of our knowledge.

Case report

A 20-year old female patient from Tamil Nadu presented to us with chief complaint of blurring of vision and floaters since 3 months in right eye which was gradual in onset and progressive. She was diagnosed as right eye panuveitis 3 months ago elsewhere and was referred to us.

On examination her best corrected vision in right eye was 3/60, N36, left eye 6/5, N6. Her extraocular movements were normal. On slit lamp examination her right eye had vitreous cells 1+, left eye was normal. Fundus examination in right eye showed macular serpiginous choroiditis with thick epiretinal membrane. Left eye was normal. Optical coherence tomography was shown in Fig. 3.

Her laboratory tests were normal except for Quantiferon Gold TB test positive. She was started

on oral steroid based on her weight and anti-tuberculosis treatment. On 1 month follow up her vision remained the same and she was complaining of more blurring of vision than the last visit. Her best corrected visual acuity in right eye was 3/60, N36. Left eye 6/5, N6.

On slit lamp examination anterior segment both eyes normal except right eye has vitreous cells (1+). Fundus examination revealed right eye healed serpiginous choroiditis with macular hole.

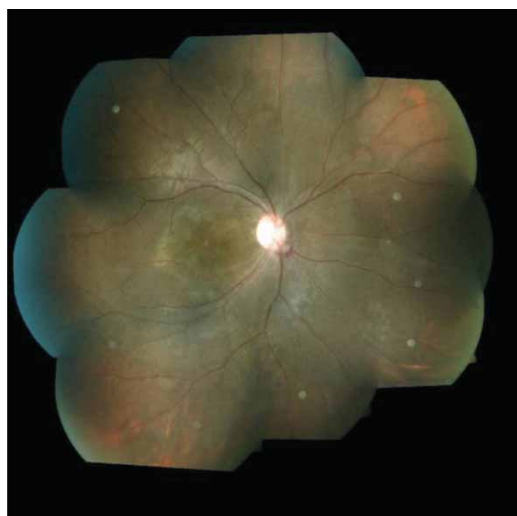


Figure 1. Fundus photograph showing active macular serpiginous choroiditis.

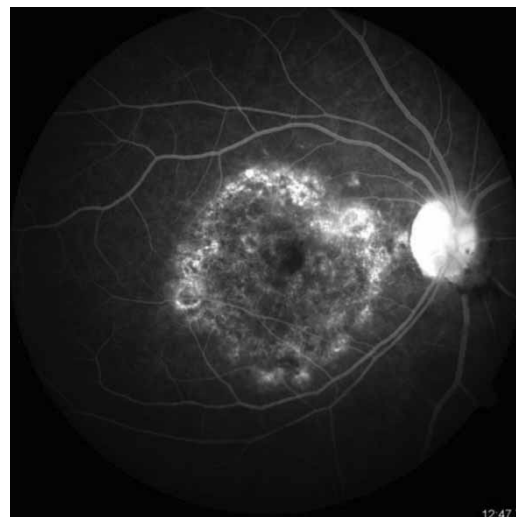


Figure 2. Fundus fluorescein angiogram shows active serpiginous choroiditis with hyperfluorescence border and central area of hypofluorescence.

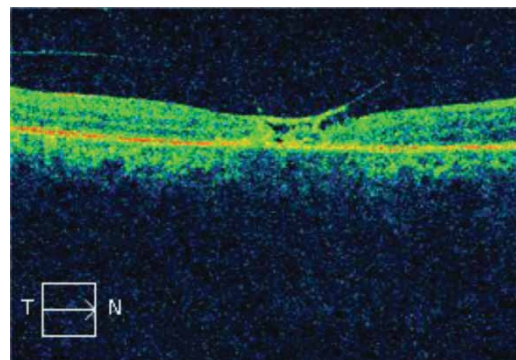


Figure 3. Optical coherence tomography showing vitreomacular traction and epiretinal membrane (at first time presentation).

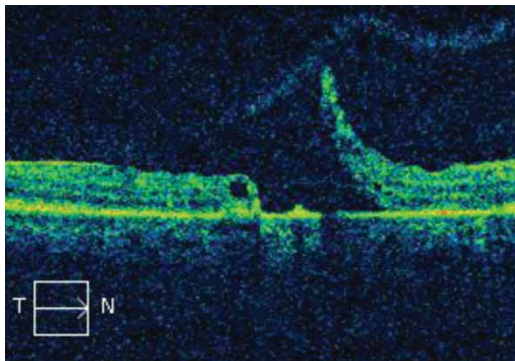


Figure 4. Optical coherence tomography showing full thickness macular hole with edge lift up by traction (1 month after).

Left eye within normal limits. Optical coherence tomography is shown in Fig. 4. She was diagnosed has right eye healed seriginous macular choroiditis with full thickness macular hole. Pars plana vitrectomy, membrane peeling, gas tampanode done to right eye. Her postoperative vision was 6/60, N36. There was incompletely closed macular hole.

Discussion

Macular hole is not common in uveitis except in intermediate uveitis (pars planitis). It has been reported also in toxoplasmic retinochoroiditis² and cat scratch disease.³ The cause of macular hole is not clear in choroiditis. In our case, probably there is persistent inflammation leading to vitreomacular traction causing macular hole. There was mild inflammation of the vitreous in our case (vitreous cells 1+). Other possibility is vitreomacular traction caused by the epiretinal membrane. Gregory *et al.*¹ reported one case of bilateral macular hole in serpiginous choroiditis. In their patient, vitritis during recurrence may have caused irregular contraction of the premacular cortical vitreous. The absence of an operculum

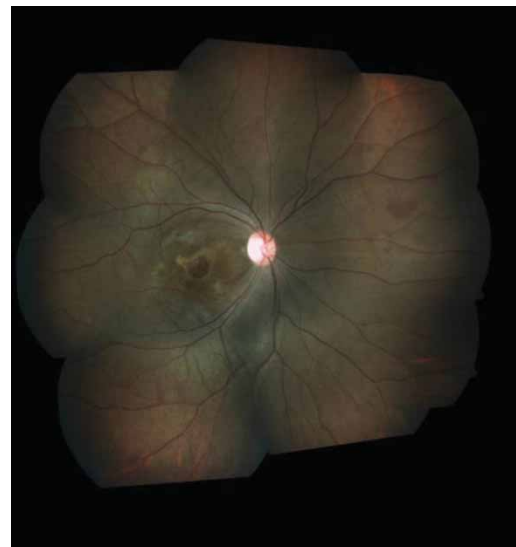


Figure 5. Fundus photograph shows healed macular serpiginous choroiditis and persistent macular hole.

suggests centrifugal photoreceptor displacement by tangential vitreous traction. ERM contraction is another possible source of tangential traction in their case. Management in of macular hole is vitrectomy, internal limiting membrane peeling and gas tamponade. Visual prognosis is guarded in spite of successful surgery.

References

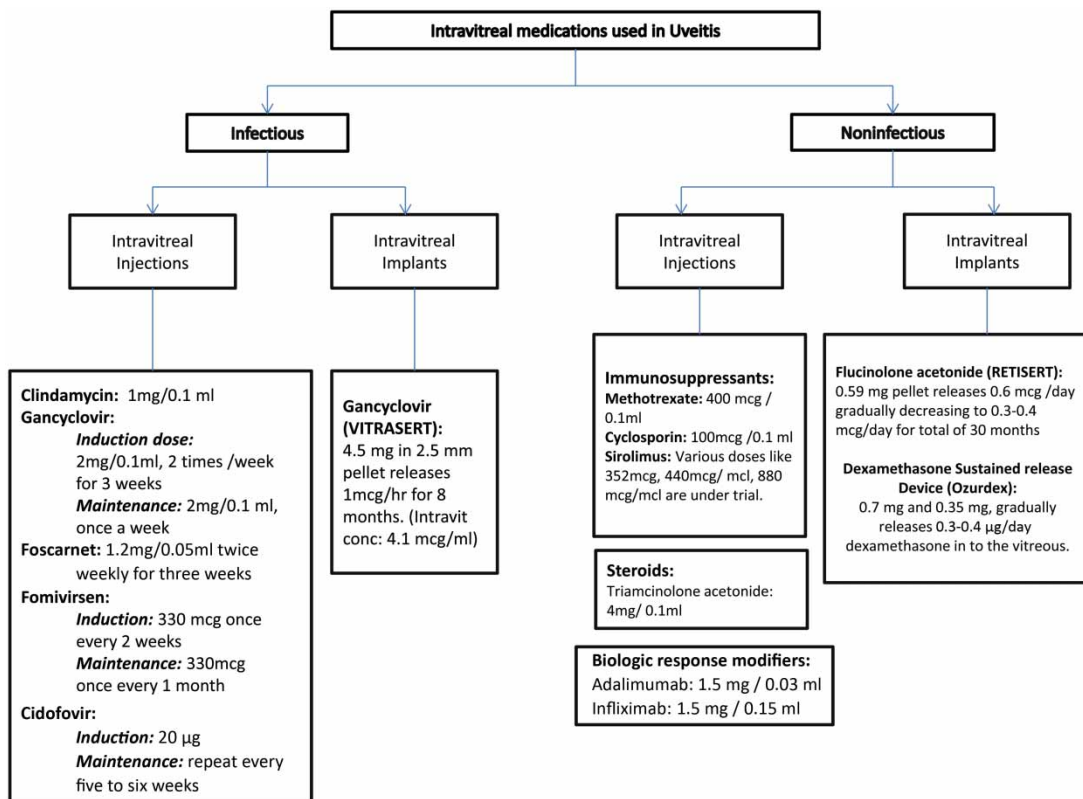
1. Gregory ME, Bhatt U, Benskin S, Banerjee S. Bilateral full thickness macular holes in association with serpiginous choroiditis. *Ocul Immunol Inflamm* 2009; 17(5): 328–329.
2. Blaise P, Comhaire Y, Rakic JM. Giant macular hole as an atypical consequence of a Toxoplasmic chorioretinitis. *Arch Ophthalmol* 2005; 123(6): 863–864.
3. Albin TA, Lakhnpal RR, Foroozan R, *et al* Macular hole in cat scratch disease. *Am J Ophthalmol* 2005; 140(1): 149–151.

How to cite this article Ranganathan P, Biswas J. Unilateral Full Thickness Macular Hole in Association with Serpiginous Choroiditis, *Sci J Med & Vis Res Foun* 2014;XXXII:27–28.

Intravitreal Medications in Uveitis

A Maheshwari

Correspondence to:
Abhilasha Maheshwari,
Post Graduate Trainee,
Sankara Nethralaya,
18, College Road,
Chennai 600006,
India.
E-mail: dimension.abhi@gmail.com



Cycloplegic Refraction in Children

L Jayalakshmi¹, N Kalpa^{1,2} and R Srikanth²

¹Elite School of Optometry,
Chennai 600016, India

²Medical Research Foundation,
Chennai 600006, India

Correspondence to:
R. Srikanth,
Associate Consultant,
Department of Paediatric
Ophthalmology,
Sankara Nethralaya.
E-mail: drrsk@snmail.org

Introduction

Refraction is a procedure to assess the refractive errors of the eye. In static retinoscopy, the patient is asked to fixate a distance target (4–6 m) thereby relaxing the accommodation and retinoscopy is performed. In children, maintaining distance fixation can be difficult and thus can cause fluctuations and inaccurate refraction. Control of accommodation is usually achieved by the use of pharmacological agents (cycloplegics) such as cyclopentolate, atropine, homatropine and tropicamide. Studies^{1–2} have proven that the human ciliary muscle carry muscarinic, angiotensin receptors and P2-adrenoceptors. Cycloplegic agents are anticholinergic and block the muscarinic action of acetylcholine. This inhibits cholinergic stimulation of the iris sphincter muscle and ciliary muscle, causing pupillary dilation (mydriasis) and cycloplegia (arresting accommodation).

In children, cycloplegic refraction is done to accurately assess the refractive power of the eye. Cycloplegic refraction³ involves determination of the refractive error when the patient's accommodation is partially or totally paralyzed using a cycloplegic agent.

Indications for cycloplegic refraction

- Refractive errors
 - To assess the refractive power of the eye in children (myopia, hyperopia and astigmatism).
 - Poor co-operation/fixation during refraction.
 - Fluctuations in the refractive error while performing dry retinoscopy.
 - Vision not correlating with the dry refraction.
 - To rule out latent hyperopia.
 - Refractive surgery—to assess the refractive error accurately and rule out latent component.
- Accommodative anomalies
 - Asthenopia, headache or other symptoms due to accommodative problems such as amplitude of accommodation, dynamic retinoscopy, infacility, insufficiency etc.
 - Pseudomyopia/accommodative spasm—to assess the accurate refractive error and as a treatment to break the spasm

- Amblyopia
 - Penalization—especially atropine is given to the sound eye to blur the vision and training the use of amblyopic eye (PEDIG-ATS^{4–6} atropine penalization and patching achieve similar results in improvement in moderate amblyopia).
- Strabismus
 - All the types of squint especially accommodative and partially accommodative esotropia.
- Media opacities
 - Corneal/lenticular opacities obscuring the visual axis but which show a clear peripheral area on dilatation with a mydriatic eye drop (commonly tropicamide or homatropine) to delay surgical intervention when necessary.
- Uveitis
 - To relieve pain and prevent the formation of synechia.
- Post-operatively
 - To manage post-operative inflammations.
- Malingering

Common cycloplegic agents used by eye care practitioners³

Table 1 describes the cycloplegic and mydriatic effect of different cycloplegic agents.

Post-cycloplegia

- General effects
 - Long lasting mydriasis.
 - Muscle balance and near point testing cannot be performed.
 - Photophobia/difficulty seeing bright lights.
 - Local and systemic toxic and allergic side effects are potentially significant.
- Effects of poor cycloplegia
 - Fluctuations in refractive error while performing retinoscopy and error in refraction.
- How to check cycloplegic effect
 - Pupillary reaction to light.
 - Blurred near vision with receded near point of accommodation.

Table 1.

Agent	Strength (percentage)	Mydriasis		Cycloplegia		Side effects
		Maximum (min)	Recovery time	Maximum (min)	Recovery time	
Phenylephrine	2.5	20	2–3 h	None		Tachycardia, hypertension
Tropicamide	0.5, 1	20–40	2–6 h	30	2–6 h	
Cyclopentolate	0.5, 1, 2	30–60	6–24 h	25–75	6–24 h	Psychosis, seizure
Homatropine	2, 5	40–90	1–3 days	30–60	1–3 days	Ataxia
Atropine	0.5, 1	30–60	7–14 days	60–180	3–12 days	Flushing, tachycardia, fever, delirium

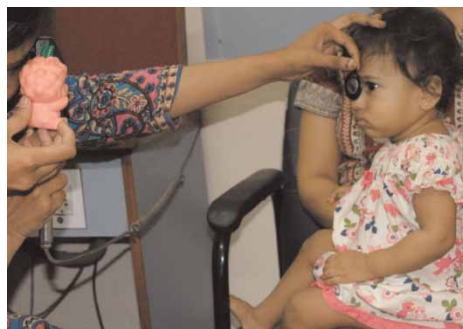

Figure 1. Retinoscopy being performed by an optometrist.

- Variation of refractive error while fixating at a distance and near target.

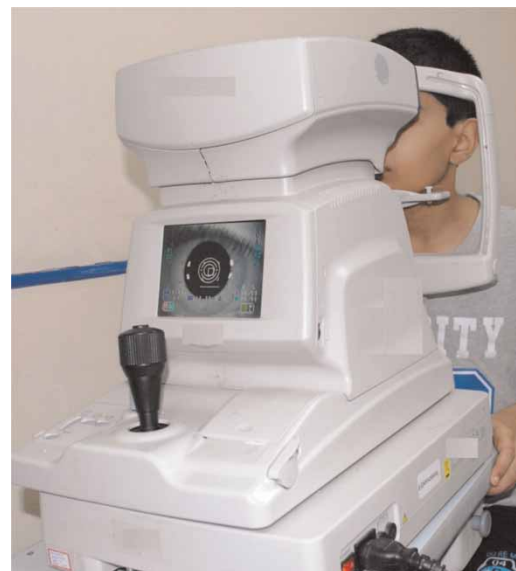

Figure 2. Autorefractometer.

Methods of performing cycloplegic refraction

- Retinoscopy^{7,8}

Retinoscopy (also called skiascopy) is a technique to objectively determine the refractive error of the eye using a retinoscope. In children, it is challenging to perform cycloplegic refraction especially in infants. Infants are engaged showing different colored target (e.g., even mobile phones with interesting cartoons and videos) as a fixation target and retinoscopy is performed holding loose lenses in front of the eye as shown in Fig. 1.

- Autorefractometer^{8,9}

Autorefractometers (Fig. 2) have become more important in recent years because of the busy schedule of the eye care practitioners. Studies have proved that there is no significant difference in cycloplegic refraction between manual retinoscopy method and autorefractometer whereas difference was noted with non cycloplegic refraction between them.

- Open-field autorefractometer

Open-field autorefractometer (Fig. 3) allows the patient to fixate at any distance and refractive error can be determined. Studies

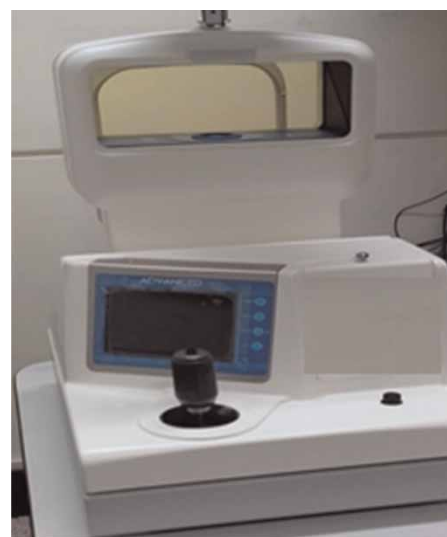

Figure 3. Open-field autorefractometer.

report that it has been validated for measuring refraction reliably in young adult population

and it can measure both static and dynamic accommodation. It can be used in children, giving them attractive distance targets to assess the refractive error.

- Photoscreener¹⁰⁻¹⁵
Photoscreening uses a camera to capture the image of a child's eye in un-dilated or dilated state. These images are analyzed using special software to estimate the refractive error and this technique is termed as photorefractometry. Commonly available photoscreeners are iScreen and Plusoptiks™.

Comparing different methods

- Manual retinoscopy still holds to be the gold standard method to assess the refractive error in children.
- Many studies have compared the use of the above-mentioned methods. There is no significant difference in these methods under cycloplegia. However, open field autorefractometer gives low hyperopic readings before and after cycloplegia as compared with closed field autorefractometer which overestimates myopia and underestimates actual hyperopia (instrumental myopia–near fixation).

Conclusion

Cycloplegia in children though is mainly used to determine the refractive error; it is also indicated for other purposes. Manual retinoscope is still the gold standard method and accurate technique to determine refractive status of children. The refraction skills of an eye care practitioner especially in pediatric population are important and challenging. In children, we mostly depend on cycloplegic refraction to determine the accurate refractive error and prescribe correction.

References

1. Lograno MD, Reibaldi A. Receptor-responses in fresh human ciliary muscle. *Br J Pharmacol* 1986; **87**: 379–385.
2. Zetterstrom C, Hahnenberger R. Pharmacological characterization of human ciliary muscle adrenoreceptors in vitro. *Exp Eye Res* 1988; **46**: 421–430.
3. Wright KW, Spiegel PH. Handbook of Pediatric Ophthalmology and Strabismus. New York: Springer, 2003.
4. PEDIG. A randomized trial of atropine vs. patching for treatment of moderate amblyopia in children. *Arch Ophthalmol* 2002; **120**(3): 268–278.
5. Repka MX, Kraker RT, Beck RW, Holmes JM, Cotter SA, Birch EE, et al. A randomized trial of atropine vs patching for treatment of moderate amblyopia: follow-up at age 10 years. *Arch Ophthalmol* 2008; **126**(8): 1039–1044.
6. PEDIG, Scheiman MM, Hertle RW, Kraker RT, Beck RW, Birch EE, Felius J, et al. Patching vs atropine to treat amblyopia in children aged 7 to 12 years: a randomized trial. *Arch Ophthalmol* 2008; **126**(12): 1634–1642.
7. Farhood QK. Cycloplegic refraction in children with cyclopentolate versus atropine. *J Clin Exp Ophthalmol* 2012; **3**: 7.
8. Pokupec R, Mrazovac D, Kordic R. Comparison between refractometer and retinoscopy in determining refractive errors in children–false doubt. *Coll Antropol* 2013; **37**(1): 205–208.
9. Rotsos T, Grigoriou D, Manios N. A comparison of manifest refractions, cycloplegic refractions and retinoscopy on the RMA-3000 autorefractometer in children aged 3 to 15 years. *Clin Ophthalmol* 2009; **3**: 429–431.
10. Erdumus M, Yagci R, Durmus M. A comparison of photorefractometry and retinoscopy in children. *J AAPOS* 2007; **11** (6): 606–611.
11. Silbert D, Matta N. ROC analysis to improve sensitivity and specificity of the plusoptix photoscreener. *J Ophthalmic Vis Res* 2012; **7**(1): 2.
12. Dahlmann AH, Comyb O, Vivian AJ. Plusoptix vision screener: the accuracy and repeatability of refractive measurements using a new autorefractor. *Br J Ophthalmol* 2009; **93**(3): 346–349.
13. Dahlmann Noor AH, Vivian AJ. A comparison of photorefractometry and retinoscopy in children. *J AAPOS* 2008; **12** (1): 104–105.
14. Mirzajani A, Heirani M, Haghani H. A comparison of the Plusoptix S08 photorefractor to retinoscopy and cycloretinoscopy. *Clin Exp Optom* 2013; **96**(4): 394–399.
15. Silbert D, Matta NS, Andersen K. Plusoptix photoscreening may replace cycloplegic examination in select pediatric ophthalmology patients. *JAAPOS* 2013; **17**(2): 163–165.

How to cite this article Jayalakshmi L, Kalpa N, Srikanth R. Cycloplegic Refraction in Children, *Sci J Med & Vis Res Foun* 2014; **XXXII**:30–32.

The Sankara Nethralaya Academy

(Unit of Medical Research Foundation),

No 9 Vanagaram – Ambattur Road, Ayanambakkam, Chennai – 600 095

www.thesnacademy.ac.in

The Sankara Nethralaya Academy (TSNA) is education arm of Sankara Nethralaya(a unit of Medical Research foundation)

TSNA is avowed to employ a system of educating people in a community or society, arts, and science colleges, imparting knowledge through instruction courses, training classes, and usher in newer training/teaching methodologies including the use of IT. The objective is to teach courses that deal with A to Z in healthcare services.

TSNA offers career oriented programs in the field of allied healthcare and Hospital administration. Our allied health science courses are run in collaboration with The Tamil Nadu Dr MGR medical University. The programs have been designed to meet the growing demand for the well trained health care professionals.

Key Features of our Academy are

- | | |
|---|---|
| <ul style="list-style-type: none"> • Modern air conditioned classroom built for aesthetic comfort • Library facility • Interactive classroom session with eminent faculties • Hostel facility available on request • Audio Video classroom facility • Hi speed internet and Computer lab with latest systems. | <ul style="list-style-type: none"> • No Capitation / Donation Fees • Transportation facilities, • Nominal Fee structure • Flexible fee payment option (Instalments) • Faculty and student collaborative projects • Education loan through City Union Bank (for applicable courses) • Tie up with Multi Speciality Hospital |
|---|---|

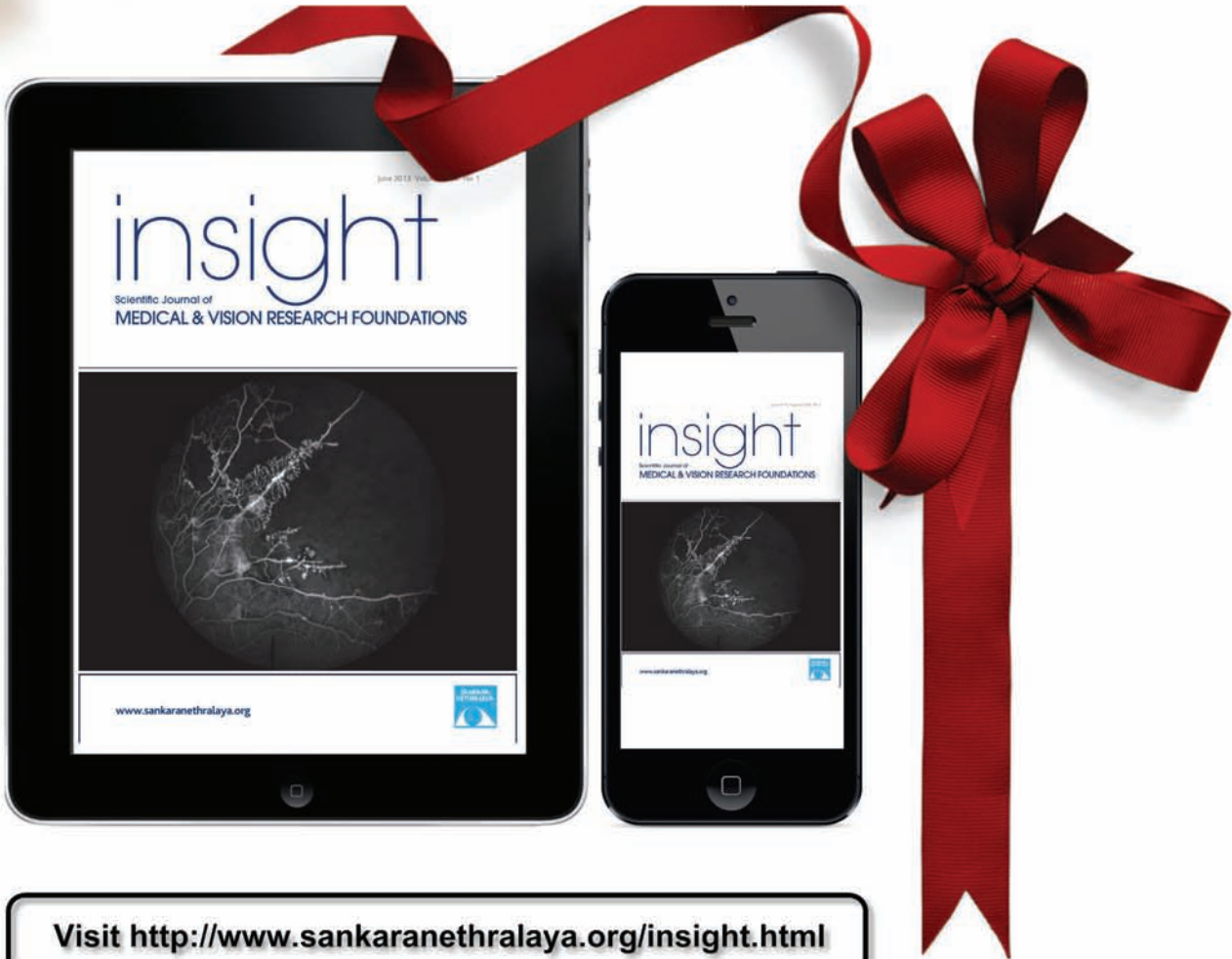The following courses are offered by our SN Academy are:

S No	Degree and Diploma Courses	Course details like :
1	Diploma in Operation Theatre & Anaesthesia Technology.	Affiliation / Association / Eligibility Criteria / Fees Structures
2	Diploma in Ophthalmic Nursing Asst(ONA)	
3	Diploma in Refraction and Dispensing	
4	BSc Medical Laboratory Technology	
5	MS Medical Laboratory Technology	
6	MBA in Hospital and Health System Management.	
Short tem / Certificate Courses		to be referred our website : www.thesnacademy.ac.in
1	Certificate Course in Hospital Management(weekend)	or
2	Certificate Course in Hospital Infection Control(Distance Learning)	Write to:
3	Certificate Course in Optical Sales	A Mahalingam
4	Certificate course in Ophthalmic Dispensing	Academic Officer / Asst Registrar
5	Certificate Course in Optical Retail Management	The Sankara Nethralaya Academy
6	Certificate Course in Basic Life Support (American Heart Assn)	No 9, Vanagaram – Ambattur Road
7	PG Program in Hospital management(Distance Learning)	Ayanambakkam, Chennai – 600 095
8	PG Program in Optical Retail Management(Distance Learning)	Ph No : 044 4908 6000
Optometry - Short tem / Certificate Courses		Fax No : 044 2825 4180
1	Certificate Course in Retinal Diagnosis – 2 weeks	E – Mail : mahali@snmail.org
2	Certificate Course in Glaucoma Diagnosis – 2 weeks	
3	Certificate Course in Corneal Diagnosis – 2 weeks	
4	Certificate Course in Low Vision Aids – 3 months	
5	Certificate Course in Binocular Vision & Vision Therapy	
6	Certificate Course in Clinical Optometry – 3 months	
7	Fellowship in Low Vision Aids – 6 months	
8	Fellowship in Contact Lens – 6 months	
9	Fellowship in Binocular Vision & Vision Therapy – 6 months	
10	Fellowship in British Dispensing Opticians (FBDO) – 8 months	



Now,

**Download & Read INSIGHT
in your iPad, tablet and mobile**



Visit <http://www.sankaranethralaya.org/insight.html>



insight

The scientific journal of MEDICAL & VISION RESEARCH FOUNDATION